

Original Research Article

doi: <http://dx.doi.org/10.20546/ijcrbp.2016.303.001>

Analysis of Retrosternal Goiter among Thyroidectomized Patients in Benghazi

Tawfik Abuzalout*, Salah Eltaktuk and Saed El Taleb

Benghazi University, Benghazi, Libya

*Corresponding author.

Abstract

The aim of the study was to highlight the epidemiology, clinical features and surgical complications of retrosternal goiter. All patients operated for thyroid disease during the period from June 1999 to January 2009 in the Surgical Department of 7th October Hospital, Benghazi-Libya were retrospectively analyzed and age, sex and clinical features were noted. Out of 3614 thyroidectomies performed, 97 patients were found to have retrosternal goiter (2.7%). The mean age was 42 yrs (25—80 yrs). 81 (83%) patients were females and (17%) 16 patients were males. (93%) 90 patients were euthyroid, (5%) 5 patients were toxic and (2%) and 2 patients were hypothyroid. About one Seventh of the patients were asymptomatic. Commonly observed symptoms were, shortness of breath, hoarseness, dysphagia, cough and superior vena cava obstruction. In all patients the goiter was resected through cervical incision, except three patients who needed partial sternotomy. Total thyroidectomy was performed in (72%) 70 cases. There were four minor complications and no death. The incidence of retrosternal goiter with respect to thyroidectomy patients is (2.7%). Cervical incision is nearly always adequate. Retrosternal goiter doesn't seem to be associated with increased incidence of post-operative complications.

Article Info

Accepted: 09 February 2016

Available Online: 06 March 2016

Keywords

Retrosternal goiter
Thyroidectomy
Thyroidism

Introduction

Retrosternal goiter is defined as any goiter which at least 50% of the thyroid resides below the level of thoracic inlet (Moron et al., 1998) and it's a common cause of compression of adjacent structures. The incidence of retrosternal goiter varies from 3 to 20% with respect to thyroidectomy patients. Multinodular goiter is a common condition in Benghazi despite wide spread consumption of iodine in the diet. Traditionally, retrosternal extension of goiter has been an indication of thyriodectomy (Allo and Thompson, 1983). Factors that cause retrosternal extension as outlined by Lahey and Swinton, include

negative intra-thoracic pressure, the absence of anatomical restriction to decent, the downward traction of swallowing and gravity (Lahey, 1934).

Several symptoms are attributable to retrosternal goiter typically, they include the sensation of pressure in the neck, dysphagia, dyspnea, hoarseness and pain are usually more concerning symptoms, as they are suggestive of malignancy. Retrosternal goiter may be asymptomatic in between 5-50% of patients and therefore maybe detected incidentally on chest radiograph or increasingly computerized tomography (CAT scan) (Shen et al., 2004; Wax and Briant, 1992).

Although medical suppression of retrosternal goiter has been described, this is a temporary and cure can be achieved only with surgery (Katlic et al., 1995; Newman and Shaha, 1995). The aim of the present study was to highlight the epidemiology, clinical features, surgical approach, complications and incidence of malignancy in retrosternal goiter.

Materials and methods

All patients operated for thyroid disease from the period June 1999 to June 2009 in Surgical Department of 7th October Hospital were retrospectively analyzed, age, sex, and clinical features were noted and the results were presented.

Results and discussion

Out of 3614, thyroidectomized performed 97 patients were found to have retrosternal goiter which represent 2.7%. Out of 97 cases, 81 (83%) were females and 16 (17%) were males (Table 1 and Fig. 1). A maximum of 40 patients (41%) were in the age distribution of 41-50 years with retrosternal goiter (Table 2 and Fig. 2). The functional status of the patients of the present study is provided in Table 3 and Fig. 3. The symptoms and non-symptoms observed in the patients are given in Table 4 and Fig. 4).

Table 1. Sex ratio of patients with retrosternal goiter.

Sex	Number	Percentage (%)
Female	81	83
Male	16	17
Total	97	100

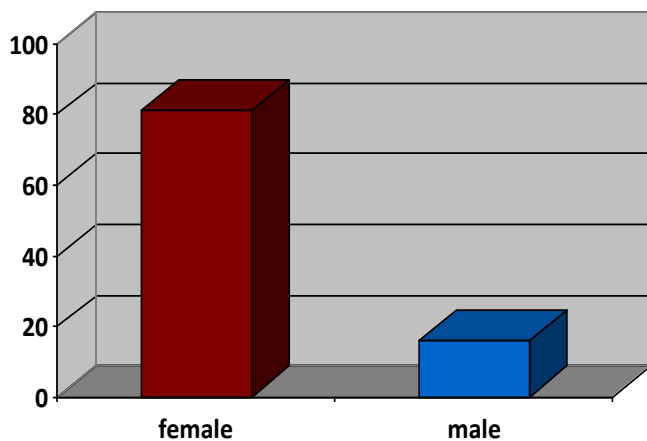


Fig. 1: Percentage of male and female patients with retrosternal goiter.

Table 2. Age distribution of patients with retrosternal goiter.

Age	Female	Male	Total	Percent
10-20	0	0	0	0
21-30	8	2	10	10
31-40	17	4	21	22
41-50	34	6	40	41
51-60	16	3	19	20
61-70	5	1	6	6
71-80	1	0	1	1
Total	81	16	97	100

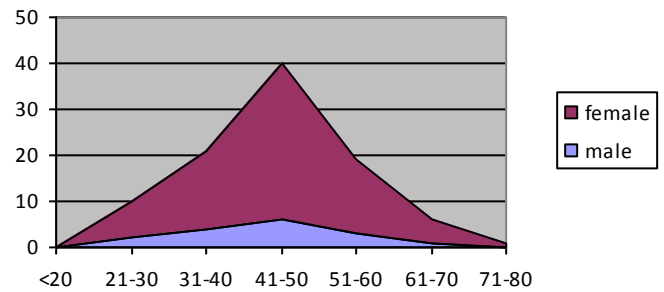


Fig. 1: Age distribution of patients with retrosternal goiter.

Table 3. Functional status of thyroid among the patients with retrosternal goiter.

Functional status	Female	Male	Total	Percent
Euthyroid	77	13	90	93
Hyperthyroidism	2	3	5	5
Hypothyroidism	2	0	2	2
Total	81	16	97	100

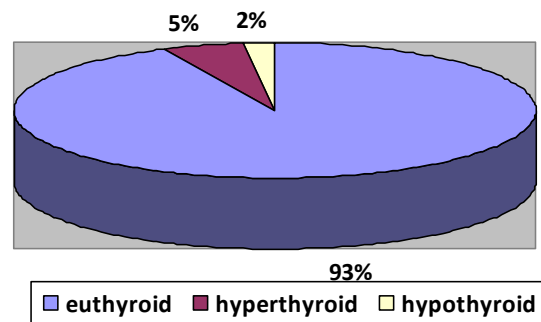


Fig. 2: Thyroid status of the subjects.

Table 4. Symptoms of patients retrosternal goiter.

Symptoms	Female	Male	Total	Percent
Dyspnea	35	6	41	49
Hoarseness	18	2	20	24
Dysphagia	11	3	14	17
cough	5	1	6	7
SVC obst	2	1	3	3
Total	71	13	84	100

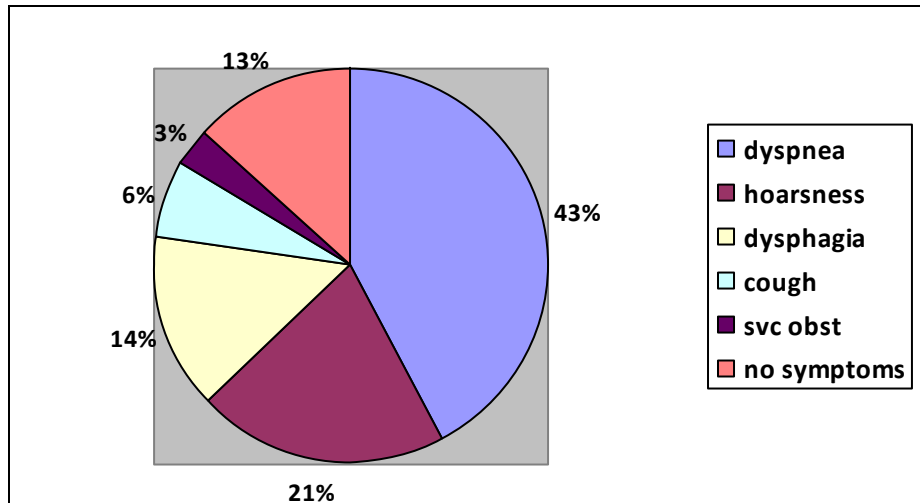


Fig. 3: Symptoms and non-symptoms observed in the patients with retrosternal goiter.

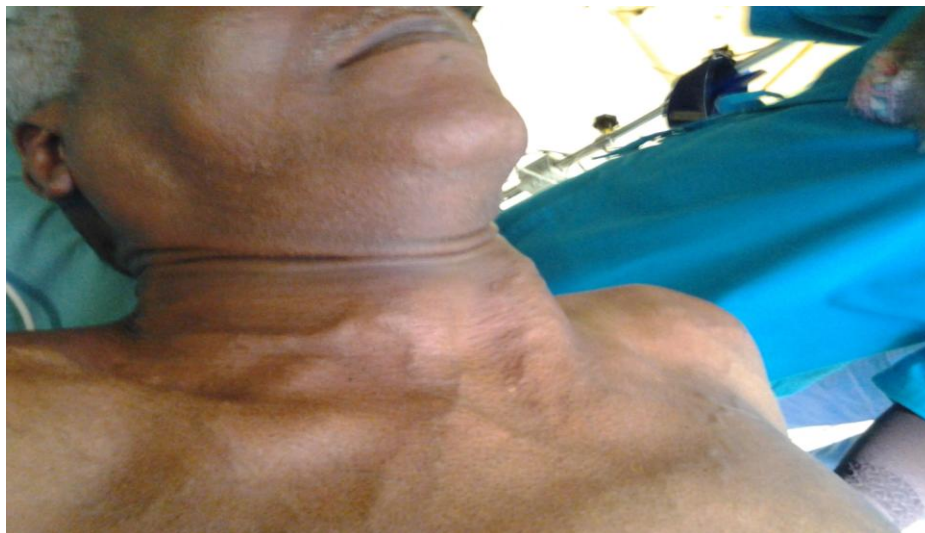

Fig. 5: Compression to Superior Vena Cava.

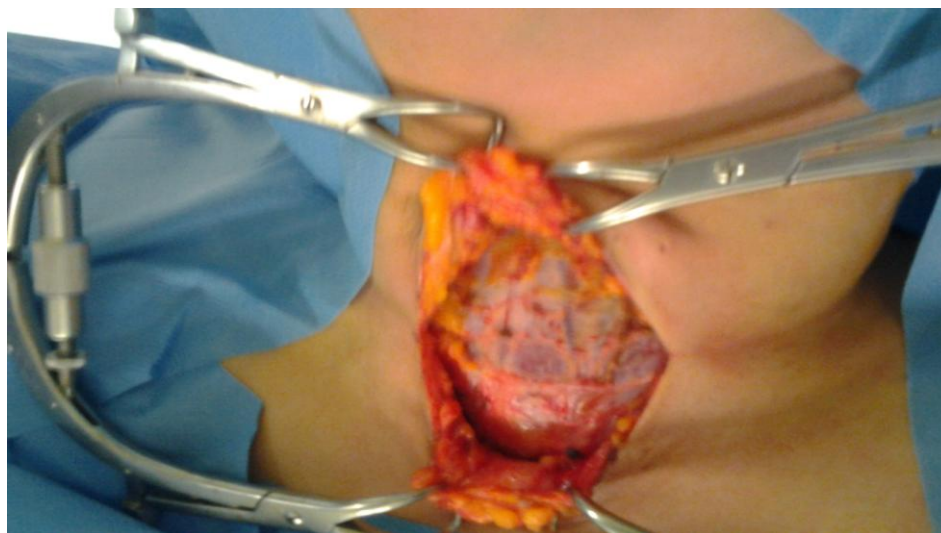


Fig. 6: Cervical incision.

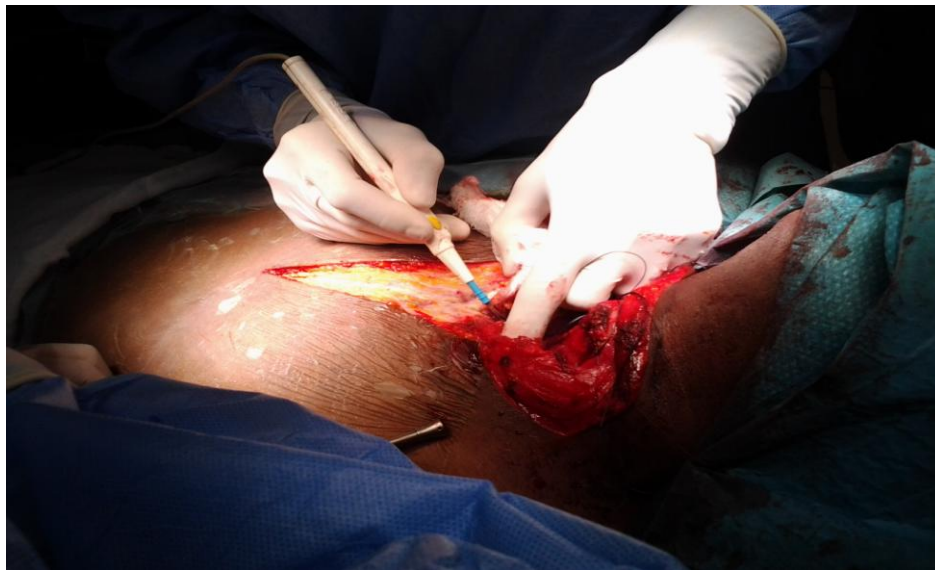

Fig. 7: Sternotomy.

All patients were submitted to surgery, cervical incision was the access in most of patients except three, in whom partial sternotomy was mandatory (Figs. 5, 6 and 7).

- 72% of the cases underwent total thyroidectomy (70 cases).
- 28% of the cases underwent near total thyroidectomy (27 cases).

Four minor complications were recorded:

1. Transient hypocalcaemia (2 cases)
2. Wound hematoma (1 case)
3. Temporary RLN Palsy (1 case)

Histological examination of specimen showed multinodular goiter in 94 patients, follicular carcinoma in two patients and follicular adenoma in one patient. Several definitions of retrosternal goiter have been previously published, which is at least partly responsible for the wide difference in incidence. We have chosen to diagnose retrosternal extension when there is 50 % or more of the goiter in the chest, and this resulted in an incidence of only (2.7%) (Netterville et al., 1998). The range of symptoms seen in our series is similar to that found by previous authors. Shortness of breath was frequent complaints (49%) followed by hoarseness of voice (24%) (Newman and Shaha, 1995; Rodriguez et al., 1999), yet none of the patients had vocal cord paralysis detected on pre-operative assessment.

Only (13%) of our patients were asymptomatic despite the more inclusive definition used, suggesting that it does have clinical validity. We found that the incidence of malignancy was only (2%). However, others have

previously shown malignancy rate of up to (21%) for retrosternal goiters (Torre et al., 1995). All thyroidectomies were possible through cervical incision (97%), and only three patients needed partial sternotomy.

Our complication rate of 4.4% was found in this series which is temporary hypocalcaemia, wound hematoma and temporary RLN palsy. Significantly no cases of permanent recurrent laryngeal recurrent nerve palsy or hypoparathyroidism were seen. This stresses the importance of the ordered surgical technique where particular care is taken to identify the recurrent laryngeal nerve and the parathyroid gland intraoperatively and to gain control of the vascular pedicles early in the procedure.

Thyroidectomy for retrosternal goiter can almost always be carried out through a cervical incision with a relatively low incidence of serious complications. Therefore, it's our recommendation that any goiter that extends into the mediastinum be treated with thyroidectomy using the technique described to remove symptoms and to prevent the serious consequence of acute airway obstruction.

Conclusion

- More The incidence of retrosternal goiter with respect to thyroidectomized patients is (2.7%), from which only (2%) harbor malignancy.
- Cervical incision is nearly always adequate.
- Retrosternal goiter doesn't seem to be associated with increased incidence of post-operative complications.

Conflict of interest statement

Authors declare that they have no conflict of interest.

References

- Allo, M.D., Thompson, N.W., 1983. Rationale for the operative management of substernal goiters. *Surgery*. 94(6), 969-977.
- Katlic, M.R., Grillo, H.C., Wang, C.A., 1985. Substernal goiter. Analysis of 80 patients from Massachusetts General Hospital. *Am. J. Surg.* 149(2), 283-287.
- Lahey, F. S. N., 1934. Intrathoracic goitre. *Surg. Gynecol. Obstet.* 59, 627-637.
- Moron, J.C., Singer, J.A., Sardi, A., 1998. Retrosternal goiter: a six-year institutional review. *Am. Surg.* 64(9), 889-893.
- Netterville, J.L., Coleman, S.C., Smith, J.C., Smith, M.M., Day, T.A., Burkey, B.B., 1998. Management of substernal goiter. *Laryngoscope*. 108(11 Pt 1), 1611-1617.
- Newman, E., Shaha, A.R., 1995. Substernal goiter. *J. Surg. Oncol.* 60(3), 207-212.
- Rodriguez, J.M., Hernandez, Q., Pinero, A., Ortiz, S., Soria, T., Ramirez, P., Parrilla, P., 1999. Substernal goiter: clinical experience of 72 cases. *Ann. Otol. Rhinol. Laryngol.* 108(5), 501-504.
- Shen, W.T., Kebebew, E., Duh, Q.Y., Clark, O.H., 2004. Predictors of airway complications after thyroidectomy for substernal goiter. *Arch. Surg.* 139(6), 656-660.
- Torre, G., Borgonovo, G., Amato, A., Arezzo, A., Ansaldo, G., De Negri, A., Ughe, M., Mattioli, F., 1995. Surgical management of substernal goiter: analysis of 237 patients. *Am. Surg.* 61(9), 826-831.
- Wax, M.K., Briant, T.D., 1992. Management of substernal goitre. *J. Otolaryngol.* 21(3), 165-170.

How to cite this article:

Abuzalout, T., Eltaktuk, S., El Taleb, S., 2016. Analysis of retrosternal goiter among thyroidectomized patients in Benghazi. *Int. J. Curr. Res. Biosci. Plant Biol.* 3(3), 1-5.
doi: <http://dx.doi.org/10.20546/ijcrbp.2016.303.001>