

Pediatric traumatic hyphema: a review of 123 consecutive cases.

By Mariam M.B.Gebril

FRCS (Glasg.)

University of Benghazi, Faculty of Medicine, Ophthalmology department, Benghazi, Libya.

Corresponding author

Mariam M.B.Gebril

Email address: Mariam.gebri@uob.edu.ly

Abstract

Aim: To report the demographics and outcomes in children (<18 years of age) who developed hyphema from ocular trauma.

Introduction: Traumatic hyphema is regarded as a sign of ocular trauma requiring, in most centers, admission to hospital. It is almost invariably associated with damage to the anterior segment and frequently to the posterior segment.

Method: A retrospective review of the ophthalmic records of 123 consecutive patients with traumatic hyphema secondary to ocular trauma presenting to Benghazi Eye hospital between 1/1/2011 and 31/12/2011.

Result: total number 123 cases 97 male and 26 female. Most injury occurred in outdoor locations as school in 77 patient (62.6%). The main causative agent is stone in 39 patient (31.7%) followed by gun soft toys 23 (18.6%).

A total of 37 (30%) eyes had at least one surgical intervention. While 54 (43.9%) patients had visual acuity (VA) less than 6/60 at presentation, 21 (17.0%) of eyes had visual acuity (VA) < 6/60 after injury.

Conclusion: most of the injuries occurred outdoor indicating lack of adult supervision, and community awareness is needed for prevention.

Key words: Pediatric; epidemiology; traumatic hyphema; ocular trauma.

دائرة الصدمة لدى الأطفال: استعراض لحالات متتالية 123

العرض عن طريق: مريم محمد جبريل

جامعة بنغازي، كلية الطب البشري، قسم العيون.

ابميل: Mariam.gebri@uob.edu.ly

الهدف: الإبلاغ عن التركيبة السكانية والنتائج في الأطفال (> سن 18 سنة) الذين حدثت لهم نزف في الحجرة الامامية للعين (هيفيما) الناتج عن إصابة العين.

مقدمة: يعتبر الهيفيما علامة من علامات الإصابة للعين التي تتطلب، في معظم المراكز، الدخول إلى المستشفى. ويرتبط دائماً تقريباً مع الضرر في الجزء الأمامي، وغالباً في الجزء الخلفي.

الأسلوب: مراجعة استعدادية لسجلات المرضى على التوالي 123 مع دائرة الهيفيما الثانوية عرضه لإصابات العين لمستشفى بنغازي للعيون بين 1\1\2011 و 31/12/2011.

النتيجة: مجموع عدد 123 الحالات، 97 الذكور و 26 اناث. وقعت معظم الإصابات في مواقع في الهواء الطلق كمدرسة في 77 مريض (62.6%).

أن العامل المسبب الرئيسي الحجر في 39 المريض (31.7 في المائة) تليها بندقية اللعب اللينة 23 (18.6%).

وكان ما مجموعة 37 (30 في المائة) عيون التدخل الجراحي واحد على الأقل. بينما 54 المرضى (43.9 في المائة) مقدار البصر أقل من 60/6 في العرض التقديمي، كان 21 (17.0%) من العيون قوة الابصار > 60/6 بعد الإصابة.

الاستنتاج: معظم الإصابات حدثت في الهواء الطلق التي تشير إلى عدم إشراف الكبار، ووعي المجتمع بالحاجة إلى الوقاية.

Introduction:

Traumatic hyphaema is regarded as a sign of ocular trauma requiring, in most centers, admission to hospital. It is almost invariably associated with damage to the anterior segment and frequently to the posterior segment

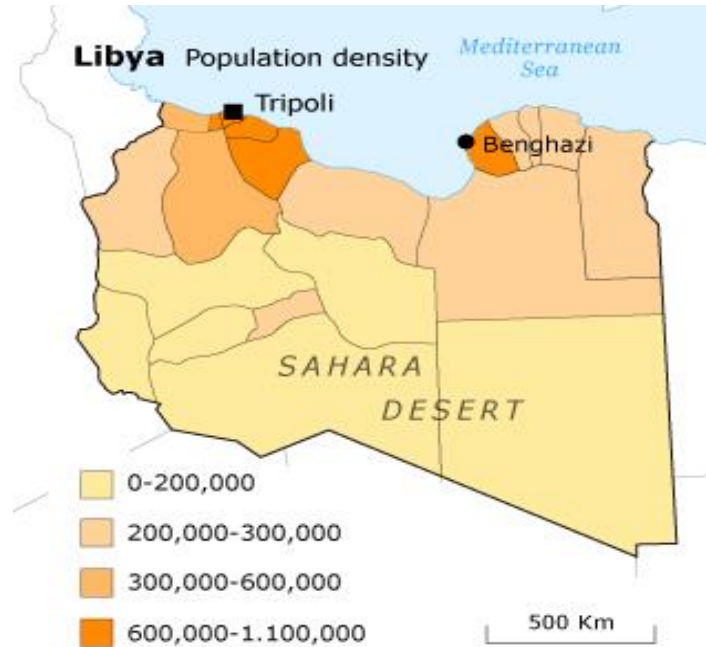
Furthermore, paediatric patients have the highest rate of unilateral non-congenital blindness due to ocular trauma.[Rocha et al ,2004 ; Agapitos et al, 1987].

A common complication of ocular trauma is hyphaema where erythrocytes begin to fill the anterior chamber due to the pressure applied to the anterior surface of the eye from the trauma. This leads to distension of the tissues, increased intra ocular pressures, damage to the ciliary body and the major arterial circle.[Rocha et al, 2004].

When discussing the risks of hyphaema there are multiple considerations that must be accounted for. Complications include increased intraocular pressure due to blockage of the trabecular meshwork by erythrocytes or inflammatory cells [Ashaye et al, 2008].Secondary hemorrhages are of particular concern as they have been associated with permanent vision loss due to secondary glaucoma from angle recession leading to elevated IOP [Edwards WCand Layden WE,1973], corneal blood staining and optic atrophy.⁸ Re-bleed rates in the literature range largely from 3.5% to 38%.

Method:

The Martyr Sohail Al-Atrash Eye Hospital is the second tertiary eye hospital in Libya and covers the eastern part of it; and population of more than one million in Benghazi area



A retrospective study of 123 consecutive cases received in Martyr Sohail Al-atrash eye hospital during one year duration from January to December of 2011; of age group less than 18 years of age who were victim of traumatic hyphaema either due to closed or opened eye injury. This study was performed according to Declaration of Helsinki and the subsequent amendments.

Our policy is to admit all patients with traumatic hyphema regardless the quantity of hyphaema and further management is assigned according to the type of trauma

Regarding hyphaema due to blunt injury without complications, mostly bed rest with elevated head side.

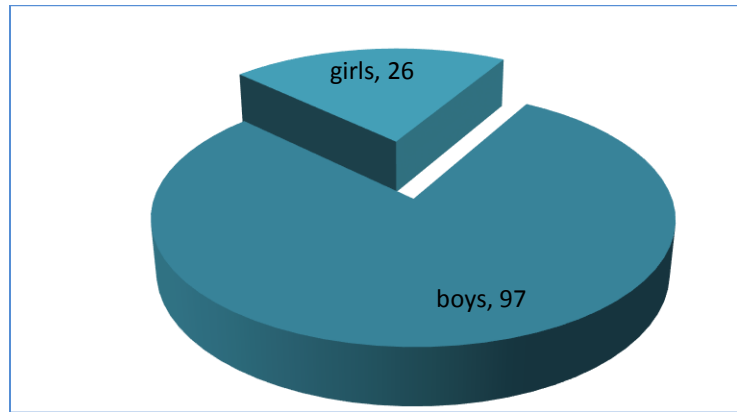
Instructed work sheet were filed from the medical records ,regarding age ,sex ,eye involved, causative agent, where the injury happened, tissue involved ,any associated complications, surgical managements visual acuity at admission and discharge when is possible.

Statistical analysis was performed using SPSS software version 17.0(spss Inc.,Chicago,IL,USA).

Results

A total of 123 cases of traumatic hyphaema was included from which 125 eyes were involved; two patients had bilateral hyphaema.

With 97 boys (78.8%) and 26 girls (21.2%) with a ratio of 3.7:1



Number of girls and boys

Table 1 reveals the age range in years and number of patients included.

Age range	No.	%
1-4	14	11.3
5-9	44	35.7
10-14	52	42.2
15-17	13	10.5

Table 1

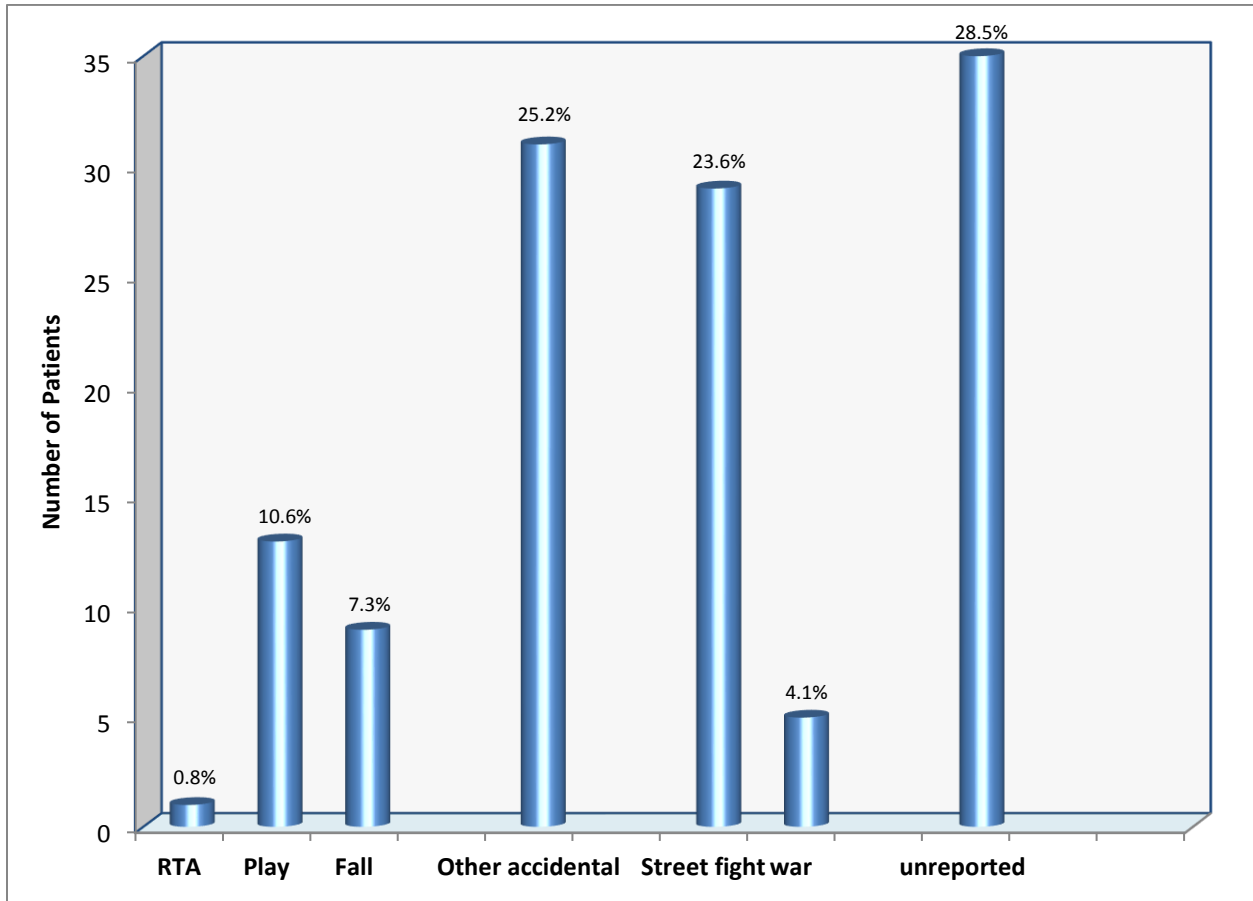
With a mean age of 8.6 years (SD=2.8).

The main duration of hospitalization was 6 ± 3.65 days (range from 0-17 days).

Most of the injuries occurred outdoors 62.6% (streets and school).

Offenders:

In Figure 1 revealed that unreported (or unknown) ocular trauma had 28.5% of the total offenders, followed by others as self-induced injuries) of 25.2% and street fight of 23.6% ,the remaining percentages play ,fall, war ,RTA.

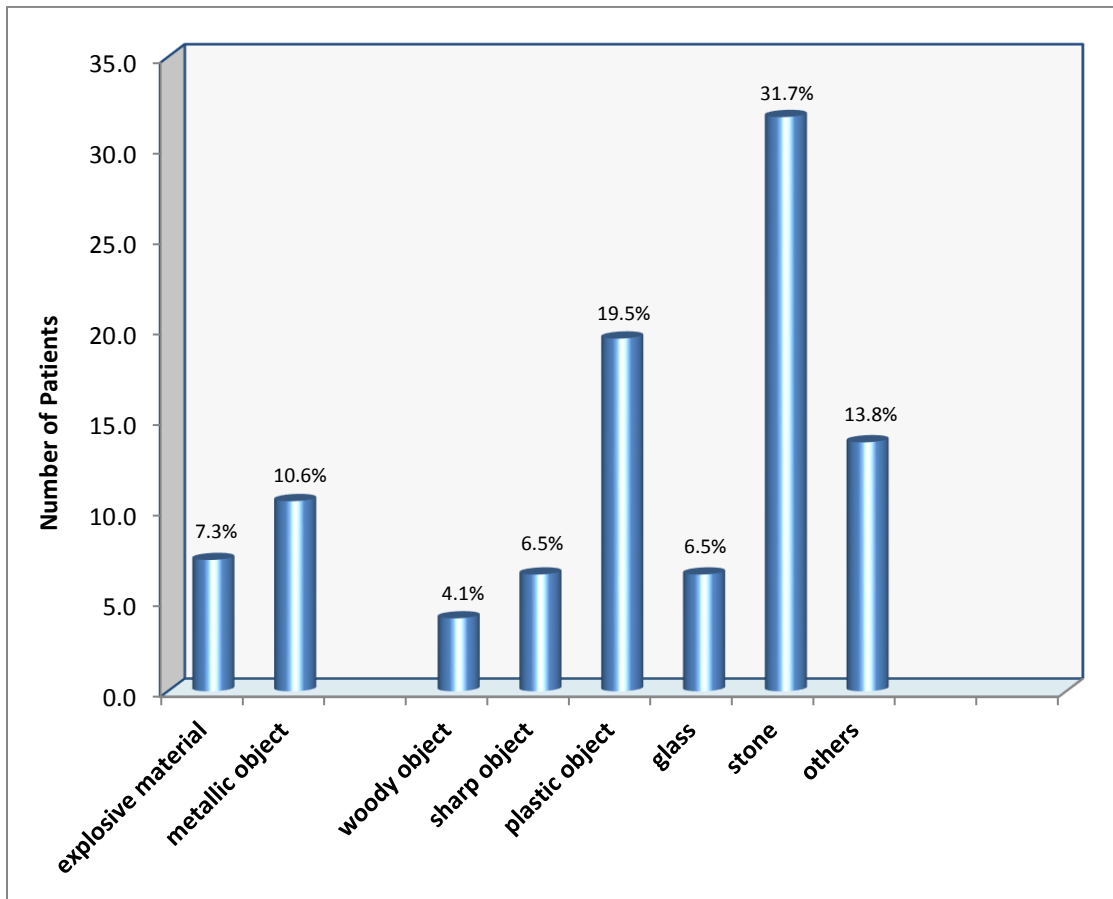


RTA=road traffic accident.

Figure 1

Causative agents:

Figure 2 shows the main causative agents; as stones take 31.7%, plastic objects of 19.5%.



Figuer2

Table 1 shows Visual acuity in closed eye trauma at admission and discharge:

V\A	At admission	At discharge
NPL	2	0
PL	6	2
HM	11	2
CF3M	17	7
6\60-6\12	30	25
6\6-6\9	10	35
Un recorded	10	15

V\A=visual acuity. NPL=no perception of light.PL=perception of light. HM=hand movement.CF=counting fingers.

Table 1

Table 2 shows Visual acuity in closed eye trauma at admission and discharge:

V\A	At admission	At discharge
NPL	6	6
PL	10	9
HM	5	2
CF3M	4	5
6\60-6\12	3	5
6\6-6\9	0	0
Unrecorded	11	12

V\A=visual acuity. NPL=no perception of light.PL=perception of light. HM=hand movement.CF=counting fingers

Table 2

86 eye with closed eye injury and 39 opened injury, all associated with deferent grades of hyphaema;

Grade I 69(55%). Grade II 28 (22.4%).Grade III 22(17.6%).Grade IV 6(4.8%).

There was no significant relationship between visual acuity, IOP and recurrence of hyphema (p>0.05).

The most frequent accompanying symptoms to hyphema were corneal epithelial defect (71eyes 56.8%) and rise in IOP higher than 24 mmHg (30 eyes 24%) at admission to the hospital.

Also common complications were traumatic mydriasis (20%), followed by cataract (12%).

Clot wash done in 2 cases of closed injury due to uncontrolled high IOP (1.6%).

Iridodialysis in 4 cases (3.2%).retinal edema in 21eyes (16.8).choroidal tear in 2 eyes (1.6%).

Rebleeding in only 5caese (4%), no one with sickle cell haemoglobinopathy, but were on topical corticosteroids. All of rebleeding with grade I and occur within 5 days of trauma .105 patients presented within 24 hours of sustaining ocular injury (85.3%).

Discussion:

Hyphema resulting from blunt eye trauma may be seen in all age groups, but it has been reported more commonly in children at 10-19 years of age. [Ng CS,1992;Fong LP,1994] ,In our study 10-14years of age (42.2%).

Majority of the patients were males (77.4%) with Male:Female ratio of 3.7:1, which is consistent with findings in most studies [MacEwen et al., 1999; Tomazzoli et al., 2003; Ariturk et al., 1999; Hill et al., 2006; Moreira et al., 1988; Vasnaik et al., 2002].

We found a higher incidence of eye injuries in the age above 5(88.7%) this result has been reported by others. [MacEwen et al., 1999; Serrano et al., 2003; Tomazzoli et al., 2003; Ariturk et al., 1999; Bratton et al., 1997] as this age tend to be more active and to have some freedom to play without supervision.

Of the patients, 61% had trauma to their left eyes, and this was explained as being due to right hand preference, which may lead to reflex protection of the other eye.[Ashaye AO,2008].

Read and Goldberg reported that IOP was higher than 25 mmHg in 25% of the traumatic hyphema patients at admission which is similar to ours(24%), this is due to obstruction in the trabecular meshwork and increased incidence of pupillary block.

There were no significant correlations between the visual acuity , IOP, accompanying findings, complications, or surgery rates. Serious complications were seen in 32% of all patients.

This may be due to hospitalization of all patients, immobilization by bed rest, topical steroid use, and lack of sickle cell anemia.

In our study closed globe injuries were more frequent (69.9%) similar finding were reported in others [MacEwen et al., 1999; Serrano et al., 2003; Strahlman et al., 1990].

Conclusion :

More clear and proper regimes regarding management and reporting of ocular trauma are needed.

Modifying and close monitoring of ocular trauma, community education for causes and sings of complications of pediatric ocular trauma .

Most of the injuries occurred outdoor indicating lack of adult supervision, and community awareness is needed for prevention.

References:

- Agapitos PJ, Noel LP, Clarke WN. Traumatic hyphema in children. *Ophthalmology*. Oct 1987;94(10):1238-1241.
- Ashaye AO. Traumatic hyphaema: a report of 472 consecutive cases. *BMC Ophthalmol* 2008;8:24.
- Ariturk, N., Sahin, M., Oge, I., Erkan, D., Sullu, Y., 1999. The evaluation of ocular trauma in children between ages 0–12. *Turk. J. Pediatr.* 41 (1), 43–52.
- Bratton, S.L., Dowd, M.D., Brogan, T.V., Hegenbarth, M.A., 1997. Serious and fatal air gun injuries: more than meets the eye. *Pediatrics* 100 (4), 609–612.
- Fong LP. Secondary hemorrhage in traumatic hyphema. Predictive factors for selective prophylaxis. *Ophthalmology* 1994;101:1583-8
- Edwards WC, Layden WE. Traumatic hyphema: a report of 184 consecutive cases. *AmJ Ophthalmol* 1973; 75: 110-6.
- Hill, J.R., Crawford, B.D., Lee, H., Tawansy, K.A., 2006. Evaluation of open globe injuries of children in the last 12 years. *Retina* 26 (Suppl. 7), S65–S68.
- MacEwen CJ. Sport associated eye injury: a casualty department survey. *BrJ Ophthalmol* 1987; 71: 701-5.
- Moreira Jr., C.A., Debert-Ribeiro, M., Belfort Jr., R., 1988. Epidemiological study of eye injuries in Brazilian children. *Arch. Ophthalmol.* 106 (6), 781–784.
- Ng CS, Strong NP, Sparrow JM, Rosenthal AR. Factors related to the incidence of secondary haemorrhage in 462 patients with traumatic hyphema. *Eye (Lond)* 1992;6:308-12.
- Read J, Goldberg MF. Comparison of medical treatment for traumatic hyphema. *Trans Am Acad Ophthalmol Otolaryngol* 1974;78:799-815.
- Rocha KM, Martins EN, Melo JLAS, Bueno de Moraes NS. Outpatient management of traumatic hyphema in children: Prospective evaluation. *Journal of American Association for Pediatric Ophthalmology and Strabismus*. 8// 2004;8(4):357-361.

Serrano, J.C., Chalela, P., Arias, J.D., 2003. Epidemiology of childhood ocular trauma in a Northeastern Colombian region. *Arch. Ophthalmol.* 121 (10), 1439–1445.

Strahlman, E., Elman, M., Daub, E., Baker, S., 1990. Cause of pediatric eye injuries. A population-based study. *Arch. Ophthalmol.* 108 (4), 603–606.

Tomazzoli, L., Renzi, G., Mansoldo, C., 2003. Eye injuries in childhood: a retrospective investigation of 88 cases from 1988 to 2000. *Eur. J. Ophthalmol.* 13 (8), 710–713.

Vasnaik, A., Vasu, U., Battu, R.R., Kurian, M., George, S., 2002. Mechanical eye (globe) injuries in children. *J. Pediatr. Ophthalmol. Strabism.* 39, 5–10.