

Original Research Article

Laparoscopic Transabdominal Preperitoneal Hernia Repair. Early experience of 37 patients

Abuzalout Tawfik A.* and Taktuk Salah S.

Department of Surgery, Faculty of Medicine, University of Benghazi, Benghazi, Libya

* Corresponding author Email: tawfikz_salem@yahoo.com.

Abstract

Introduction: Inguinal hernia repair is one of the most frequently performed procedures in surgery and many different techniques have been suggested. This report reviews our experience with 39 transabdominal preperitoneal (TAPP) hernia repairs in 37 patients.

Methods: Thirty-seven patients have been admitted for inguinal hernia repair in Benghazi Medical Center and in Aljala hospital, Benghazi-Libya. Laparoscopic TAPP repair was considered for all reducible inguinal hernias aged (18–70 years). Data was prospectively collected from January 2009 to December 2013, including age, sex, BMI, hernia characteristics, complications, mean operative time and mean hospital stay. Patients with irreducible, obstructed or scrotal hernias, previous lower abdominal surgery, BMI more than thirty five and an American Society of Anesthesiologists (ASA) grade higher than II were excluded.

Results: There were 34 males and 3 females, with a mean age of 33.4 ± 13.0 years and BMI of 24.6 ± 1.9 . Mean operative time was 75 ± 18.6 minutes. The mean hospital stay was one day ± 0.27 . There was no conversion, mesh infection, bladder or vascular injury, death or recurrence after a median follow up for six months. Four minor complications occurred with two seroma formation, one wound bruising and one chronic groin pain due to tackers treated conservatively. Median return to normal activities was 10 days. One fourth of patients required no postoperative analgesia.

Conclusion: Laparoscopic inguinal hernia repair was found in our study to be feasible, safe, with less postoperative pain, shorter hospital stay, and early return to normal activities..

Key-words:

Hernia, Laparoscopy, TAPP.

Abuzalout Tawfik A.* and Taktuk Salah S. Laparoscopic Transabdominal Preperitoneal Hernia Repair. Early experience of 37 patients. Submitted 22/08/2016. Revised 28/08/2016. Accepted 28/08/2016

Citation DOI: 10.21502/limuj.005.01.2016

LIMUJ, Volume 1, PP 35-, 2016



LIMUJ is licensed under a [Creative Commons Attribution 4.0 International License](https://creativecommons.org/licenses/by/4.0/)

1. INTRODUCTION

Inguinal hernia repair is one of the most commonly performed operations carried out throughout the world by general surgeons; indeed, it has been stated that 'the history of hernia repair is the history of surgery [1].

Inguinal hernias affect 0.14 per cent of the population and account for 70,000 operations per year in the UK [2]. Up to our knowledge, there are no reports on the prevalence of hernia in Libya. Since the original description of hernia repair by Bassini in 1889, hernia surgery underwent numerous refinements with the sole idea to reduce recurrence [3].

Schultz, GerCorbitt, and Filipi were among the first who described laparoscopic inguinal herniorrhaphy in the early 1990s [4,5,6,7]. TAPP dominated the general surgical practice within few years of the dawn of laparoscopic repair. It rapidly became popular, and many different techniques for repair were developed.

Initial reports have been encouraging, suggesting a rapid and relatively pain free recovery, but very few reports have included longer-term results [8,9]. Advantages of laparoscopic procedures may include a reduction in post-operative pain and hospital stay, and the ability to undertake simultaneous repair of

symptomatic incipient contra-lateral herniation [10,11,12]. However, open repair can be performed under local anaesthesia and is preferred by many surgeons.

The aim of hernia repair is to repair the weakness of the abdominal wall. In the laparoscopic procedure, the repair is achieved by placement of a prosthetic mesh to cover the entire groin area, including the sites of direct, indirect, femoral and obturator hernias.

Since January 2009, we have carried out more than thirty nine laparoscopic inguinal hernia repairs and documented in detail the early outcomes of these patients. The aim of this report is to document our experience and compare our results with that of others.

PATIENTS AND METHODS

Thirty-seven patients have been admitted for inguinal hernia repair in Benghazi Medical Centre and in Aljala hospital, Benghazi-Libya. Data was prospectively collected from January 2009 to December 2013, including age, sex, BMI, hernia characteristics, complications, mean operative time and mean hospital stay. A detailed explanation of the procedure was given to all patients, and informed consent was obtained. Laparoscopic TAPP repair is

Abuzalout Tawfik A.* and Taktuk Salah S. Laparoscopic Transabdominal Preperitoneal Hernia Repair. Early experience of 37 patients. Submitted 22/08/2016. Revised 28/08/2016. Accepted 28/08/2016



considered for all reducible inguinal hernias in the age group 18 to 70 years of age. Patients with irreducible, obstructed or scrotal hernias and those with previous lower abdominal surgery, BMI more than thirty-five, and an ASA (American Society of Anesthesiologists') grade higher than II were excluded.

All patients were admitted a day before surgery. General anesthesia was used for carrying out the procedure. All patients were given a prophylactic dose of third generation cephalosporin at induction of anesthesia.

Operative technique

The patients were given a general anesthetic and a pneumoperitoneum instilled using CO₂ insufflations of up to 4 liters at a pressure of 12 mmHg, using either a Veress needle or an open blunt cannulation technique. Three ports were used, 10 mm (umbilicus), 11 mm or 5mm (right iliac fossa) and 5 mm (left iliac fossa). After identification of the hernia, starting 1 cm above the upper margin of the internal ring, a peritoneal flap is raised off the posterior surface of the transversalis fascia and extended posteriorly and caudally to expose an adequate length of testicular vessels and vas (5-6 cm).

During this dissection, the hernial sac is identified and either inverted or transected. A prolene mesh (Ethicon®) is cut to size (10 cmx 13 cm) and fixed over the defect with either staples, tackers or sutures (2/0 Vicryl on a 30 mm curved needle). The

peritoneum is then closed over the mesh with either staples, tackers or continuous Vicryl suture. The port sites are closed with 0/0 Vicryl to the deep layers and 3/0 subcuticular prolene to the skin, 20 ml of 1% bupivacaine was infiltrated around the port sites. The operative time was recorded in minutes and was counted from the incision to the placement of the last suture. Hospital stay was defined as the number of nights spent in hospital postoperatively. All patients are encouraged to mobilize and take oral fluids as soon as they feel able. The majority of patients were discharged on next day of the operation.

The patients were followed up in OPD at one week, one month and six months intervals.

Data presentation and statistical analysis

SPSS statistical package version 18.0 was used in conducting the statistical analysis. Descriptive parameters used to describe the data included percentages, mean, median, range and standard deviation.

RESULTS

This study included 34 males (92%) and 3 females (8%), where 33 of the patients (91.6%) were Libyan. The mean age of patients was 33.4±13 with a range from 18 to 70 years (Figure 1) and BMI of 24.6±1.9 with a range from 23 to 31.

Hernia characteristics are shown in the table 1, where six hernias (15.5%) were recurrences after conventional repair.



Laparoscopic Transabdominal Preperitoneal Hernia Repair

Mean operative time was 75 ± 18.6 minute, where the operation took from 60 to 89 minutes in 21 patients (58% of all patients) and less than one hour in 11 patients (30% of all patients- Figure 2). The mean hospital stay was 1.0 ± 0.27 days. There was no conversion, mesh infection, bladder or vascular injury, death or recurrence after a median follow up for six months. A total of four minor complications

occurred (10%); two seroma formation treated by aspiration, one wound bruising and one chronic groin pain due to tackers treated conservatively. One fourth of patients required no postoperative analgesia. Median return to normal activities was 10 days. All operations are performed by consultant surgeon. Three patients lost follow up at 6 months.

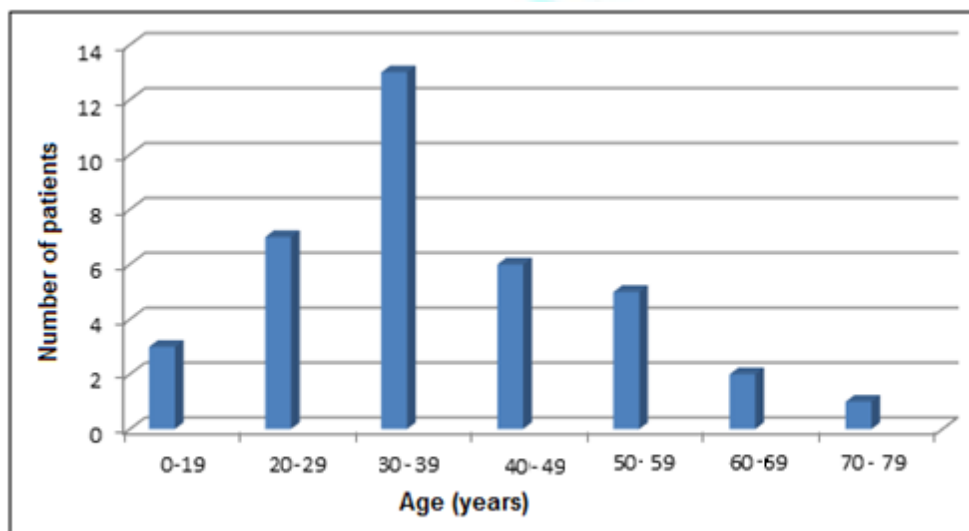


Figure 1: Age distribution of the patients admitted for inguinal hernia repair in Benghazi Medical Center and in Aljala hospital, Benghazi, Libya.

Table 1: Site and type of hernia of the patients admitted for inguinal hernia repair in Benghazi Medical Center and in Aljala hospital, Benghazi, Libya.

Site of hernia	No. (%)	Type of Hernia	No. (%)
Right	21 (54)	Direct	7 (18)
Left	16 (41)	Indirect	25 (64)
Bilateral	2 (5)	Recurrent	6 (15.5)
		Femoral	1 (2.5)

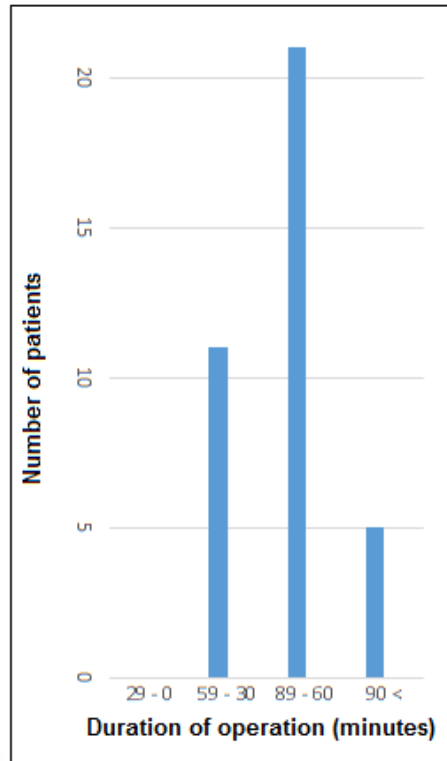


Figure 2: Duration of operation in patients admitted for inguinal hernia repair in Benghazi Medical Center and in Aljala hospital, Benghazi.

DISCUSSION

Groin hernia repair is a common surgical procedure and variety of methods of repair exists [13]. Inguinal hernia can be repaired using traditional open methods or using newer laparoscopic techniques. The most common open technique in use in the UK is that popularized by Lichtenstein and colleagues [14,15].

Laparoscopic approaches allow hernia repair without the need to open the abdominal wall. The main variations in laparoscopic approaches depend on whether

or not the instruments enter the peritoneal cavity [16,17,18].

Laparoscopic hernia repair has several advantages over conventional open methods as shown by prospective randomized trials comparing laparoscopic to tension-free open herniorrhaphy [19].

The major advantages include less postoperative pain, earlier return to normal activities and work, and better cosmetic results [20,21].



This study is carried out at two big Hospitals in Benghazi, Benghazi Medical Center (BMC) and AlJala Hospital. Benghazi is the second largest city in Libya located at the coast of the Mediterranean Sea in the north eastern part of the country, with about one million inhabitants. Aljala hospital is a major referral trauma hospital. TAPP was introduced to our hospital only few years ago and we thought that documenting our experience would help create a baseline knowledge about the procedure in our area. We report the data collected on the first Thirty-nine repairs carried out by our team. They represent the developmental and learning curve of the involved surgical team. We have recently also reduced the cost of the laparoscopic repair by avoiding the use of disposable instruments and using sutures instead of staples, because of the war in our country and limited resources.

The outcomes of laparoscopic inguinal hernia repair in our patients are close to those reported by others in the region [22,23] with similar complication rate of about 10% and less analgesic requirement. This might be because of the good selection of cases subjected to the procedure. We have not seen intraoperative complications. This is in contrast to some of the other reports. Some reported complications such as bladder injury (0%-0.2%), mainly in patients with previous suprapubic surgery; bowel injury (0%-0.3%) if the patient is not in the Trendelenburg position and damage to major vessels (0%-0.11%) [27].

There were no major postoperative complications and no recurrences in our patients. However, the median follow-up in our patients was relatively short and some might recur later on due to the fact that most recurrences occur after two years. Therefore, our results are only applicable to the operative and early postoperative courses.

Laparoscopic inguinal hernia repair requires the acquisition of technical skills. A learning curve of at least 40 cases is necessary to reduce the rate of complications and recurrences [24]. One of the ways to shorten the learning curve, minimize complications and the recurrence rate is to refine the techniques in a major center.

Historically, cost analysis favored open hernia repair over laparoscopy. However, with more than a decade of experience in laparoscopic hernia repair and the dissemination of knowledge to all regions, costs have fallen and are now comparable to open repair [25,26].

Fully trained surgeons can now complete a laparoscopic repair in the same time or faster than an open one which has only become clear over the past few years due to the learning curve surgeon.

From large, randomized trials and meta-analyses, it is evident that laparoscopic repair is superior to open mesh and sutured repairs in the early postoperative period, being associated with less pain and a shorter convalescence [10,28,29].



CONCLUSIONS

Laparoscopic inguinal hernia repair was found in our study to be feasible, safe, with less postoperative pain, shorter hospital stays, less postoperative complications and early return to normal activities.

CONFLICT OF INTEREST

The authors state that there is no conflict of interest whatsoever and no funding from any party was received in the making of this study.

REFERENCES

- [1] Patino JF. A history of the treatment of hernia. *Hernia*. 1995;4:3-15..
- [2] National Institute for Health and Clinical Excellence(NICE). *Laparoscopic Surgery for Inguinal Hernia Repair*. NICE: London, 2004.
- [3] Holzheimer RG. Low recurrence rate in hernia repair results in 300 patients with open mesh repair of primary Inguinal hernia. *Eur J MedRes*. 2007;12:1-5.
- [4] Ger R. The laparoscopic management of groin hernias. *Contemp Surg*. 1991;39(4):15-9.
- [5] SCHULTZ L, GRABER J, PIETRAFITTA J, HICKOK D. Laser laparoscopic herniorrhaphy: a clinical trial preliminary results. *Journal of laparoendoscopic surgery*. 1990;1(1):41-5.
- [6] Corbitt Jr JD. Laparoscopic herniorrhaphy. *Surgical Laparoscopy Endoscopy & Percutaneous Techniques*. 1991 Mar 1;1(1):23-5.
- [7] Filipi C, Fitzgibbons RJ, Salerno GM, et al. Laparoscopic herniorrhaphy. *Surg Clin North Am*. 1992;72:1109–24.
- [8] Stoker DL, Spiegelhalter DJ, Singh R, Wellwood JM. Laparoscopic versus open inguinal hernia repair; randomized prospective trial. *Lancet* 1994; 343:1243-5.
- [9] Wheeler KH. Laparoscopic inguinal herniorrhaphy with mesh, an 18 month experience. *J Laparosc Surg* 1993;3:345-50.
- [10] Berndsen F, Arvidsson D, Enander LK, et al. Postoperative convalescence after inguinal hernia surgery: prospective randomized multicenter study of laparoscopic versus shouldice inguinal hernia repair in 1042 patients. *Hernia*.2002;6:56–61.
- [11] Eklund A, Rudberg C, Smedberg S, et al. Short-term results of a randomized clinical trial comparing Lichtenstein open repair with totally extraperitoneal laparoscopic inguinal hernia repair. *Br J Surg*. 2006;93:1060–8
- [12] Memon MA, Cooper NJ, Memon B, Memon MI, Abrams KR. Meta-analysis



- of randomized clinical trials comparing open and laparoscopic inguinal hernia repair. *British Journal of Surgery*. 2003;90(12):1479-92.
- [13] McCormack K, Wake B, Perez J, Fraser C, Cook J, McIntosh E, et al. Laparoscopic surgery for inguinal hernia repair: Systemic review of effectiveness and economic evaluation. *Health Technology Assessment*. 2005;9:14
- [14] O'Riordan DC, Morgan M, Kingsnorth AN, Black NA, Clements L, Brady H, et al. Current surgical practice in the management of groin hernias in the United Kingdom. Report to the Department of Health. London: Department of Health; 1996.
- [15] Lichtenstein IL, Shulman AG, Amid PK, Montllor MM. The tension-free hernioplasty. *Am J Surg*. 1989;157:188-93.
- [16] Ger R. The management of certain abdominal hernia by intra-abdominal closure of the neck of the sac. Preliminary communication. *Ann R Coll Surg Engl*. 1982;64:342-4.
- [17] Schultz LS, Graber J, Pietrafitta JJ. Laserlaparoscopic herniorrhaphy – a clinical trial. Preliminary results. *J Laparoendosc Surg*. 1991;1:41-5.
- [18] Corbitt JD Jr. Laparoscopic herniorrhaphy. *Surg Laparosc Endosc*. 1991;1:23-5.
- [19] Bringman S, Blomqvist P. Intestinal obstruction after inguinal and femoral hernia repair: a study of 33,275 operations during 1992-2000 in Sweden. *Hernia* 2005;9:178-83.
- [20] Heikkinen TJ, Haukipuro K, Koivukangas P, et al. A prospective randomized outcome and cost comparison of totally extra-peritoneal endoscopic hernioplasty versus Lichtenstein operation among employed patients. *Surg Laparosc Endosc*. 1998;8:338-44.
- [21] Pawanindra L, Kajla RK, Chander J, et al. Randomized controlled study of laparoscopic total extra-peritoneal versus open Lichtenstein inguinal hernia repair. *Surg Endosc*. 2003;17:850-6.
- [22] Saber A, Hokkam AN, Ellabban GM. Laparoscopic transabdominal preperitoneal approach for recurrent inguinal hernia: A randomized trial. *J Minim Access Surg*. 2015;11:123–8.
- [23] Eisa A, Gaber A, Harb TT. Laparoscopic transabdominal preperitoneal inguinal hernia repair. *Egyptian journal of surgery*. 2014;33: 86-9.
- [24] Tamme C, Scheidbach H, Hampe C, et al. Totally extraperitoneal endoscopic inguinal hernia repair (TEP). *Surg Endosc*. 2003; 17:190-5.
- [25] Swanstrom LL. Laparoscopic hernia repairs. The importance of cost as an



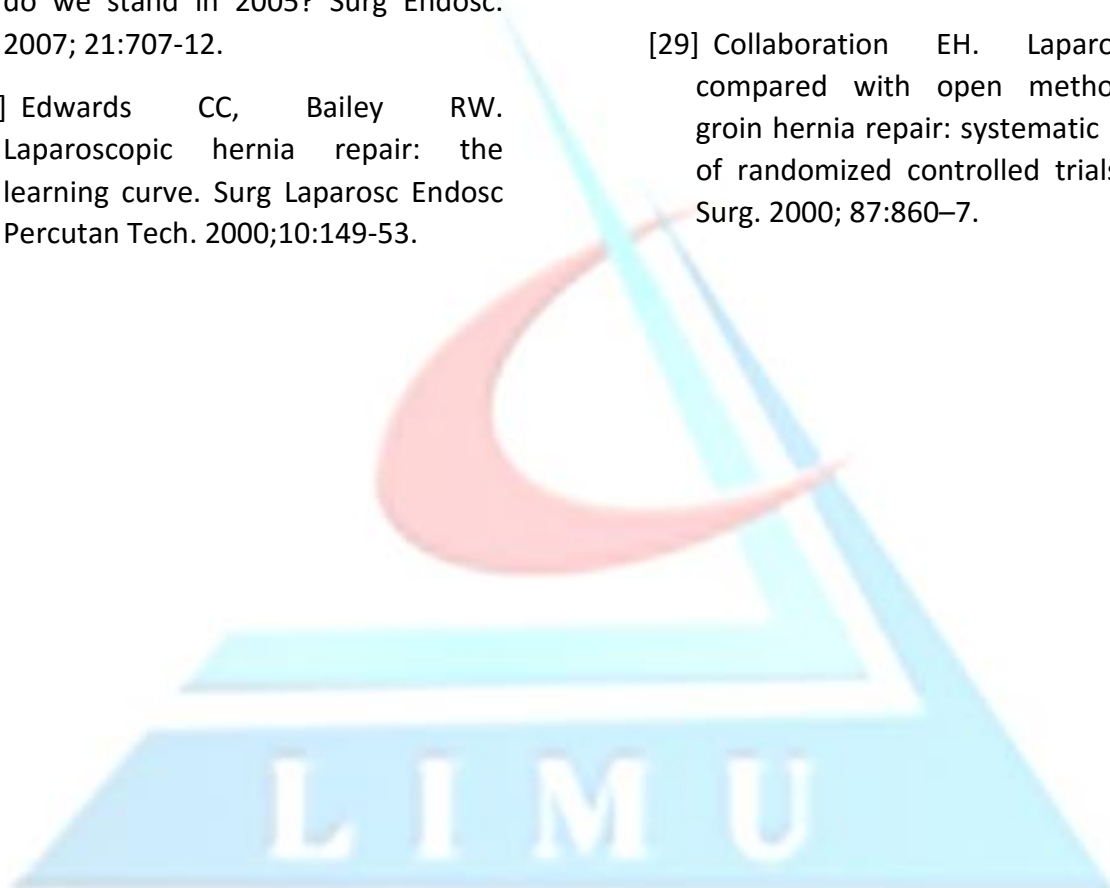
outcome measurement at the century's end. *Surg Clin North Am* 2000; 80:1341-51.

[26] Bowne WB, Morgenthal CB, Castro AE, et al. The role of endoscopic extraperitoneal herniorrhaphy: where do we stand in 2005? *Surg Endosc*. 2007; 21:707-12.

[27] Edwards CC, Bailey RW. Laparoscopic hernia repair: the learning curve. *Surg Laparosc Endosc Percutan Tech*. 2000;10:149-53.

[28] Eklund A, Rudberg C, Smedberg S, et al. Short-term results of a randomized clinical trial comparing Lichtenstein open repair with totally extraperitoneal laparoscopic inguinal hernia repair. *Br J Surg*. 2006;93:1060-68.

[29] Collaboration EH. Laparoscopic compared with open methods of groin hernia repair: systematic review of randomized controlled trials. *Br J Surg*. 2000; 87:860-7.



ملخص باللغة العربية

عملية إصلاح الفتق باستعمال المنظار عن طريق جدار البطن ومن أمام الصفاق: خبرة مبكرة على 37 مريض

توفيق أ. أبوزلوط*، صلاح س. طقطوق

* قسم الجراحة، كلية الطب، جامعة بنغازي، بنغازي، ليبيا.

* المؤلف المسؤول. البريد الإلكتروني: tawfikz_salem@yahoo.com

الملخص

مقدمة: إصلاح الفتق الأربي هي واحدة من الإجراءات التي تؤدي في معظم الأحيان في الجراحة والعديد من التقنيات المختلفة وقد اقترحت العديد من التقنيات بالخصوص. يستعرض هذا التقرير تجربتنا مع 39 عملية فتق اربي على 37 مريض باستعمال المنظار عن طريق جدار البطن و من أمام الصفاق.

الطرق: تم قبول سبعة وثلاثين مريضاً لإصلاح الفتق الإربي في مركز بنغازي الطبي ومستشفى الجلاء بنغازي-ليبيا. أجريت العمليات على المرضى الذين تتراوح أعمارهم بين (18-70 سنة). وقد تم جمع البيانات بأثر رجعي من يناير 2009 إلى ديسمبر 2013. تضمنت البيانات السن والجنس ومؤشر كتلة الجسم، وخصائص الفتق، والمضاعفات، ومتوسط الزمن المستغرق لكل من إجراء العملية والبقاء. تم استثناء المرضى الذين يعانون من الفتق غير القابل للتصحيح اليديوي والفتق المسدود وفتق الصفن والمتعرضين لجراحات سابقة على الجزء السفلي من البطن وكذلك الذين لديهم مؤشر كتلة جسم أكثر من 35 والذين تم تصنيفهم بدرجة أكبر من 2 حسب تصنيف رابطة المخدرين الأمريكية.

النتائج: كان من بين المرضى 34 ذكراً و3 إناث بمتوسط عمر إجمالي 33.4 ± 13.0 ومؤشر كتلة بمتوسط 24.6 ± 1.9 . بلغ متوسط زمن العملية 75 ± 18.6 دقيقة ومتوسط زمن البقاء في المستشفى 1 ± 0.27 يوم. لم تتعرض أي حالة للتحويل إلى فتح البطن أو التهاب الشبكة أو إصابة للمثانة أو الأوعية الدموية أو الوفاة أو لتكرار الفتق خلال ستة أشهر من المتابعة. حدثت أربع مضاعفات بسيطة تمثلت في حالي ورم مصلي وحالة كدم حول الجرح وحالة ألم مزمن في الحوض تمت معالجتها تحفظياً. تمكن أغلب المرضى من العودة إلى نشاطهم المعتاد بعد 10 أيام من العملية كما لم يحتاج ربع المرضى لأي مسكنات للألم في فترة ما بعد العملية.

الخلاصة: وجدنا في هذه الدراسة أن عملية الفتق الإربي باستعمال المنظار عن طريق جدار البطن ومن أمام الصفاق بأنها آمنة وممكنة ومصاحبة بدرجة أقل من الألم وأقل حاجة للبقاء في المستشفى مع عودة سريعة للنشاطات اليومية المعتادة.

الكلمات المفتاحية:

الفتق؛ تنظير البطن؛ تنظير من خلال جدار البطن وأمام الصفاق.

