

Laparoscopic conversion of Gastric Banding into Roux-en-Y gastric bypass

Dr. Tawfik Abuzalout

Dr. Antonio iannelli

Prof. Jean Gugenheim

Departement of digestive surgery and liver transplantation, Archet2 hospital, nice-france .University of nice-sophia-antipolis.

Abstract:

Introduction: In the last few years, laparoscopic adjustable gastric banding (LAGB) for the treatment of morbidly obese patients has become increasingly popular in Europe, Australia, and United States . Despite gastric banding (GB) remains for most the preferred bariatric procedure , the problem of revision of failed GB procedures is a quite common situation in bariatric surgery .

The aim of this paper is to assess the safety, feasibility and efficacy of the conversion of failed LAGB into RYGBP in a series of 100 consecutive cases.

Materials & methods: From March 1999 to July 2008, 100 patients underwent revisional surgery of LAGB. All patients had the LAGB converted into RYGBP. Data were collected prospectively and included: age, gender, body mass index (BMI), excess weight (EW) at the time of LAGB and at the time of revision of LAGB into RYGBP.

Results: There were 89 women and 11 men, with a mean age of 44 years. Mean initial BMI was 44,6 and 42,1 kg/m²,and mean EW was 63 and 56,8 kg at the time of LAGB and at the time of revision of LAGB into RYGBP respectively. The indications for conversion to RYGBP were primary inadequate weight loss or secondary weight regain in 59 patients, pouch enlargement in 15 patients, gastro oesophageal reflux disease (GERD) in 11 patients , gastric volvulus in 3 patients, band erosion in 7 patients (7 %), band slippage in 5 patients.

The RYGBP was performed laparoscopically in 91 cases, conversion to laparotomy in 11 cases and robotic assisted surgery in one case . The mean operative time was 169,5 min ,and the mean hospital stay was 9,4 days. One

patient died (mortality rate 1%) of a pulmonary embolism on postoperative day 4, Postoperative morbidity rate was 14 %.

Conclusion: Laparoscopic conversion of LAGB to RYGBP is safe and effective regarding weight loss and treatment of comorbidities, and can be an alternative for patients who failed the LAGB. We therefore recommend that LRYGBP should be preferred as rescue procedure after failed LAGB.

However, revision surgery is technically challenging and should be performed only by surgeons who have completed the learning curve for LRYGBP.

Key words: obesity, laparoscopy, gastric banding, failure, gastric bypass, weight loss.

Introduction:

The recent advent of laparoscopic techniques in bariatric surgery and the continuous increase in the prevalence of morbid obesity have resulted in a renewed interest in the field of bariatric surgery [1–8]. As a consequence, a large and increasing number of primary bariatric procedures are done each year worldwide.

In the last few years, laparoscopic adjustable gastric banding (LAGB) for the treatment of morbidly obese patients has become increasingly popular in Europe and Australia [9,10], and more recently in the United States [11]. Several advantages of this procedure have contributed to its wide diffusion, such as the minimally invasive and easy surgical technique, its reversibility and the ability to calibrate the stomach.

Despite gastric banding (GB) remains for most the preferred bariatric procedure [12], the problem of revision of failed GB procedures is a quite common situation in bariatric surgery [13]. There is also evidence that, in case of failed LAGB, the conversion into Roux-en-Y gastric bypass (RYGBP) is the procedure of choice [14,15].

The aim of this paper is to assess the safety, feasibility and efficacy of the conversion of failed LAGB into RYGBP in a series of 100 consecutive cases.

Patients and Methods:

From March 1999 to July 2008, 100 patients underwent revisional surgery of LAGB. All patients had the LAGB converted into RYGBP. Patients underwent a thorough preoperative work-up including: upper gastrointestinal (GI) series and endoscopy, abdominal ultrasound, medical approval from the endocrinologist, psychiatrist, and nutritionist of the bariatric team. Data were collected prospectively and included: age, gender, body mass index (BMI), excess weight (EW) at the time of LAGB and at the time of revision of LAGB

into LRYGBP, indication for revision, revision in one or two steps, type of approach (laparoscopy, laparotomy, conversion of laparoscopy to laparotomy, robotic assisted surgery), operative time, length of hospital stay, early morbidity and mortality (within 3 months of surgery irrespective of hospital stay), late morbidity and mortality (occurring beyond 3 months of surgery), and weight reduction (BMI, % excess weight loss (EWL); % excess BMI loss (EBL)). All patients were informed of the risks inherent in revisional bariatric surgery, as well as the potential benefits of this surgery and the alternatives to it.

Surgical technique:

Laparotomy:

An upper midline laparotomy was done and adhesions were taken down, the catheter leading to the port was dissected until the locking mechanism of the band was identified and the band was divided, and removed. The angle of His was freed, a retrogastric window was created close to the stomach at the level of the lesser curvature and the gastric pouch was created as small as possible with sequential applications of the endoscopic stapler (either endo-GIA stapler (Covidien, European Service Center, Elancourt, France) or Echelon (Ethicon Endo-Surgery, USA) loaded with green cartridges (4.8-mm staples). The gastric division line was reinforced with a running suture in selected cases. A 150 cm long Roux-en-Y jejunal limb was created in all the cases, after dividing the jejunum 50 cm distal to the ligament of Treitz with the endoscopic stapler loaded with white cartridges (2.5-mm staples). The jejuno-jejunal anastomosis was fashioned side-to-side using the endoscopic stapler loaded with white cartridges, completed with a running 2-0 monofilament absorbable suture. The gastrojejunal anastomosis was fashioned in one layer with continuous 2-0 absorbable sutures. An abdominal drain was left close to the gastrojejunal anastomosis in selected cases. The port was removed.

Laparoscopy:

The decision of performing the procedure in one or two steps was taken by the operating surgeon at the time of laparoscopic surgical exploration. In the case of a two steps procedure the band was retrieved first as previously described [16], and the second step was performed at least eight weeks later. LRYGBP was done with a six ports approach. The gastric pouch was fashioned first as this step of the procedure was considered the main determinant of conversion to laparotomy. The RYGBP was performed as in the case of the open technique.

Postoperative Management:

Patients were started on an oral fluid diet on postoperative day 2 after an upper GI series had showed no leak. Patients were discharged on day 5 if no postoperative complications occurred. Follow-up visits were scheduled at 1, 3, 6, 12 months and every 6 months thereafter.

Results:

There were 89 women and 11 men, with a mean age of 44 (21 to 67) years. Mean initial BMI was 44,6 (39,5 – 61,6) and 42,1 (28,4 to 57,4) kg/m² at the time of LAGB and at the time of revision of LAGB into LRYGBP respectively; mean EW was 63 (33,9 – 100,1) and 56,8 (21,2 to 94,6) kg at the time of LAGB and at the time of revision of LAGB into LRYGBP respectively (Table 1). The indications for conversion to RYGBP were primary inadequate weight loss or secondary weight regain in 59 patients (59 %), pouch enlargement in 15 patients (15 %), gastro oesophageal reflux disease (GERD) in 11 patients (11 %), gastric volvulus in 3 patients (3 %), band erosion in 7 patients (7 %), band slippage in 5 patients (5 %) (Table 2).

The RYGBP was performed laparoscopically in 91 cases (91 %), conversion to laparotomy was performed in 11 cases (12,1 %) because of technical difficulties (adhesions, bleeding or hepatomegaly). The RYGBP was performed by laparotomy in 8 cases (8 %) (previous abdominal surgery) and it was performed by robotic assisted surgery in one case (1 %). The mean operative time was 169,5 min (range 85 – 480 min). A mean hospital stay of 9,4 (4 – 36) days was recorded.

Mortality and morbidity:

Early (Table 3).

One patient died (mortality rate 1 %) of a pulmonary embolism on postoperative day 4 Postoperative morbidity rate was 14 %. There were four cases of leak at the gastrojejunostomy or the gastric pouch staple line (rate 4 %) that were managed conservatively with an endoscopic silicone covered stent in one case and with a CT scan guided drainage. Two cases of stenosis at the gastrojejunostomy were recorded (rate 2 %) that were both successfully managed with endoscopic balloon dilation. There were two peroperative splenic injuries, one leading to a conversion with splenectomy and one managed with application of Surgicel. We had also two wound abscess managed with simple drainage.

Late (Table 4).

Eighteen late complications were recorded (rate 18 %). Four stenosis at the gastrojejunostomy (rate 4 %) were successfully treated with endoscopic balloon dilation. Two cases of internal hernia (rate 2 %) required surgical exploration

for repair. Four cases of marginal ulcer (rate 4 %) three required medical treatment and one had a total gastrectomy. Six cases of incisional hernia (6 %) required surgical repair. There were two cases of dumping syndrome.

Weight loss (Figure 1, 2)

At a mean follow-up of 55,3 (4 to 108) months the RYGBP resulted in a mean BMI of 29.7 kg/m², a mean EWL of 53.1 %, and a mean EBL of 66.7 %.

There were 17 patients (17 %) who did not present any comorbid condition (Fig 3).

Table 1: Demographics

	Patients (n)	%	Mean	Range
Age (years)			44	21 – 67
Gender (F/M)	89 / 11	89 / 11		
Weight (kg)			LGB 119 LRYBP 112,3	79 – 158 76 – 164
EW (kg)			LGB 63,3 LRYBP 56,8	33,9 – 100,1 21,2 – 94,6
BMI (kg/m ²)			LGB 44,6 LRYBP 42,1	33,5 – 61,6 28,4 – 57,4

Table 2: Causes for conversion

Cause	No
Primary inadequate weight loss or secondary weight regain	59
Pouch enlargement	15
Gastro-esophageal reflux disease (GERD)	11
Volvulus	3
Erosion (intra-gastric migration)	7
Slippage	5

Table 3: Early Morbidity and Mortality

Type	Number	Causes	Treatment
Hemorrhage	2	Splenic injury	1 splenectomy, 1 conservative treatment
Fistula	6		5 stent, 1 percutaneous drainage
Anastomotic stenosis	2		1 endoscopic dilatation, 1 laparotomy
Wound abscess	2		simple drainage
Pulmonary embolism	2		1 medically , 1 died
Death	1	Pulmonary embolism	

Table 4: Late Morbidity and Mortality

Type	No	Treatment
Anastomotic stenosis	4	Endoscopic dilatation
Dumping syndrome	2	medically
Internal hernia	2	laparotomy
Eventration	6	surgical repaire
Anastomotic ulcer	4	medically
Total	18 (18 %)	

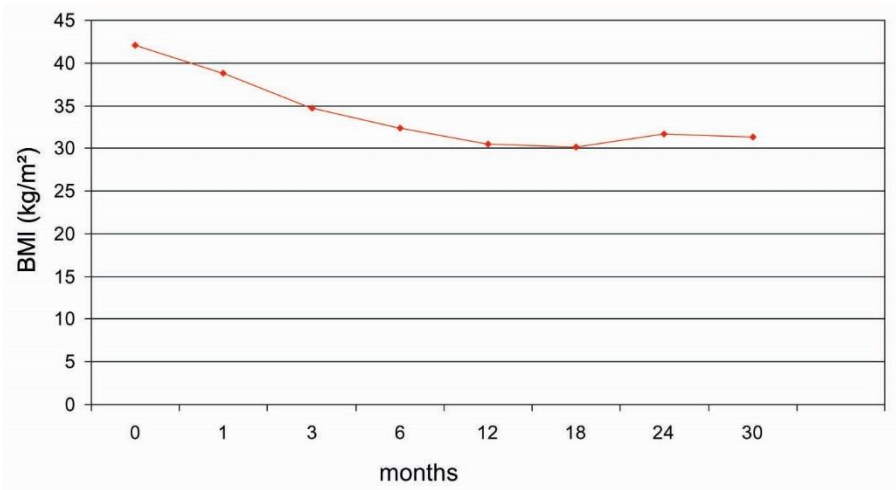


Figure 1. evolution of body mass index

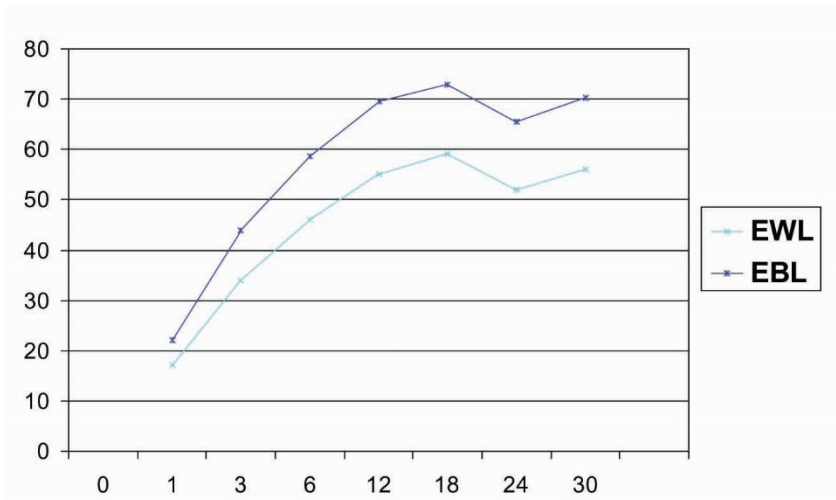


figure 2. EWL&EBL

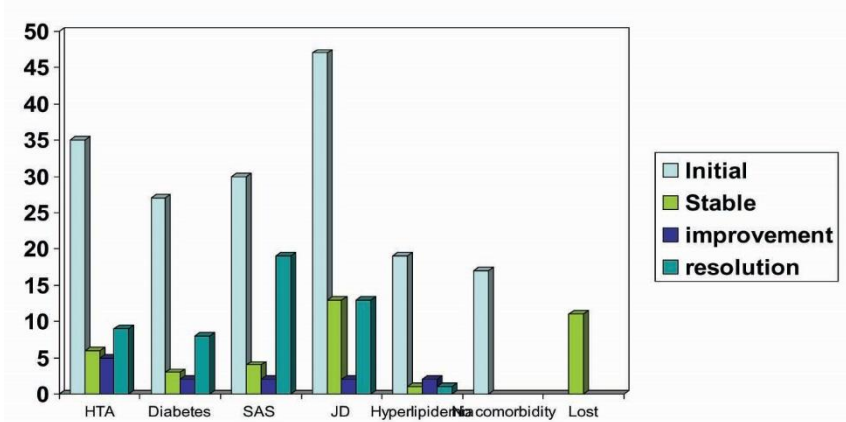


figure 3. comorbidities sequelles

Discussion:

Morbid obesity is a major public health problem worldwide that lead to a mortality rate up to 12 times greater than in normal weight population [17,18]. The WHO considers that approximately 1 billion adults in the world are overweight and at least 300 millions are obese. LAGB has increased his popularity since its introduction in 1986 because of its reversibility, easy surgical technique and good early and mid-term weight loss results [9,19,20,21]. However the high rate of long-term complications (up to 76%) and failures associated with LAGB is a concern [22,23]. Actually LRYGBP is considered the gold-standard for conversion due to LAGB complications and failures [15]. The rational of splitting the procedure in two steps, band retrieval followed by the conversion into LRYGBP a few months later, was adopted in most of the cases in order simplify the surgical procedure.

The band is generally associated with a thick scarring reaction of the gastric tissue around it, the gastric pouch above the stomach may remain dilated despite pre-operative band deflation and especially in the case of gastric erosions the vascular supply of the stomach may be impaired. The fact of removing the band may allow at least a partial regression of the inflammatory reaction around the band. Furthermore band retrieval may be sometimes a challenging and time consuming procedure.

The rate of immediate post-operative complication in this series was 15 %. This is higher than most of the series of LRYGBP reported in the literature. However this is in line with results reported by Mognol et al [24] that report a early post-operative complication rate of 14,3% and van Wageningen [25] et al that report a complication rate of 17 %.

The most common post-operative complication was a leak at the level of the gastric jejunostomy or the gastric pouch staple line. This may be at least in part attributed to the jeopardized vascular supply of the stomach and the efficacy of stapling on thick scaring tissue.

Despite of the high rate of complication functional results of conversion are satisfying and in line with results reported with primary LRYGBP.

Conclusion:

Laparoscopic conversion of LAGB to RYGBP is safe and effective regarding weight loss and treatment of comorbidities, and can be an alternative for patients who failed the LAGB.

We therefore recommend that LRYGBP should be preferred as rescue procedure after failed LAGB.

However, revision surgery is technically challenging and should be performed only by surgeons who have completed the learning curve for LRYGBP.

References

- 1- Marema RT, Perez M, Buffington CK. Comparison of the benefits and complications between laparoscopic and open Roux-en-Y gastric bypass surgeries. *Surg Endosc* 2005;19:525–30.
- 2- Hwang RF, Swartz DE, Felix EL. Causes of small bowel obstruction after laparoscopic gastric bypass. *Surg Endosc* 2004;18:1631–5.
- 3- Calle EE, Rodriguez C, Walker-Thurmond K, et al. Overweight, obesity, and mortality from cancer in a prospectively studied cohort of U.S. adults. *N Engl J Med* 2003;348:1625–38.
- 4- Calle EE, Teras LR, Thun MJ. Obesity and mortality. *N Engl J Me* 2005;353:2197- 9.
- 5- Nguyen NT, Goldman C, Rosenquist CJ, et al. Laparoscopic versus open gastric bypass: a randomized study of outcomes, quality of life, and costs. *Ann Surg* 2001;234:279–89.
- 6- Flegal KM, Carrol MD, Ogden CL, Johnson CL. Prevalence and trends in obesity among US adults, 1999–2000. *JAMA* 2002;288:1723–7.
- 7- Nguyen NT, Root J, Zainabadi K. Accelerated growth of bariatric surgery with the introduction of minimally invasive surgery. *Arch Surg* 2005;140:1198–203.
- 8- Buchwald H, Williams SE. Bariatric surgery world-wide 2003. *Obes Surg* 2004;14:1157–64.
- 9- Angrisani L, Furbetta F, Doldi SB et al. Lap-Band adjustable gastric banding system: the Italian expérence with 1,863 patients operated on 6 years. *Surg Endosc* 2003; 17: 409-12.
- 10- O'Brien PE, Dixon JB. Lap-band: outcomes and results. *J Laparoendosc Adv Surg Tech A* 2003; 13:265-70.
- 11- Ren CJ, Cabrera I, Rajaram K et al. Factors influencing patient choice for bariatric operation. *Obes Surg* 2005; 15: 202-6.
- 12- Peeters A, O'Brien PE, Laurie C, Anderson M, Wolfe R, Flum D, MacInnis RJ, English DR, Dixon J. Substantial intentional weight loss and mortality in the severely obese. *Ann Surg.* 2007; 246: 1028-33.
- 13- Gagner J *Am Coll Surg*
- 14- Muller MK, Attigah N, Wildi S, Hahnloser D, Hauser R, Clavien PA, Weber M. High secondary failure rate of rebanding after failed gastric banding. *Surg Endosc* 2007; 22: 448-53.

- 15- Weber M, Müller MK, Michel JM, Belal R, Horber F, Hauser R, Clavien PA. Laparoscopic Roux-en-Y gastric bypass, but not rebanding, should be proposed as rescue procedure for patients with failed laparoscopic gastric banding. *Ann Surg.* 2003; 238: 827-34.
- 16- Iannelli A, Dahman M, Facchiano E, Gugenheim J. A simple technique for laparoscopic removal of silicone adjustable gastric banding. *J Laparoendosc Adv Surg Tech A.* 2006; 16: 301-4.
- 17- Martin LF, Hunter SM, Lauve RM, O'Leary JP . Severe obesity: expensive to society, frustrating to treat, but important to confront. *South Med J* 1995; 88:895-902
- 18- Drenick Es. Definition and health consequences of morbid obesity. *Surg. Clin North Am* 1979; 59:963-76
- 19- Allen JW, Coleman MG, Fielding GA (2001). Lesson learned from laparoscopic gastric banding for morbid obesity. *Am J Surg* 182:10-14
- 20- Ren CJ, Weiner M, Allen JW (2004). Favorable early results of gastric banding for morbid obesity. *Surg Endosc* 18:543-546
- 21- Spivak H, Hewitt MF, Oma A, Half EE (2005). Weight loss and improvement of obesity related illness in 500 US patients following laparoscopic adjustable gastric banding procedure. *Am J Surg* 189:27-32
- 22- Suter M, Calmes JM, Paroz A, Giusti V. A 10-year experience with laparoscopic gastric banding for morbid obesity: high long-term complication and failure rates. *Obes Surg* 16:829-835
- 23- Camerini G, Adami G, Marinari GM, Gianetta E, Pretolesi F, Papadia F, Marini P, Murelli F, Carlini F, Stabilini C, Sormani M, Scopinaro N. Thirteen years of follow-up in patients with adjustable silicone gastric banding for obesity: weight loss and constant rate of late specific complications. *Obes Surg* 2004; 14:1343-8
- 24- Mognol P, Chosidow D, Marmuse JP. Laparoscopic conversion of laparoscopic gastric banding to Roux-en-Y gastric bypass: a review of 70 patients. *Obes Surg* 14:1349-1353
- 25- van Wageningen B, Berends FJ, van Ramshorst B, Janssen IFM. Revision of failed laparoscopic adjustable gastric banding to Roux-en-Y gastric bypass. *Obes Surg* 16:137-141.