



Alarab Medical University  
Faculty of Medicine, Benghazi  
Department of Anatomy & Histology

# **MORPHOMETRIC ANALYSIS OF THE HUMAN CEREBRAL LATERAL VENTRICLE USING MAGNETIC RESONANCE IMAGING**

## **Thesis**

Submitted in Partial Fulfillment for the Master Degree in Anatomy

**By**

**Asharf Mohamed Elmansori**

Graduate Student, Department of Anatomy,  
Faculty of Medicine, Alarab Medical University

## **SUPERVISORS**

**Prof. Dr. Adel A. Bondok**

Professor of Anatomy,  
Faculty of Medicine, Mansoura University, Egypt

**Dr. Faisal Shembesh**

Assistant Professor of Radiology,  
Faculty of Medicine, Alarab Medical University

**2009**



جامعة العرب الطبية  
كلية الطب  
قسم التشريح والأنسجة

# تحليل القياسات الشكلية للبطين الوحشي الدماغى البشري باستخدام التصوير بالرنين المغناطيسى

رسالة مقدمة من الطبيب

**أشرف محمد المنصوري**

قسم التشريح - كلية الطب - جامعة العرب الطبية

توطئة للحصول على درجة الماجستير في علم التشريح

**المشرفون**

**الأستاذ الدكتور عادل عباس بندق**

أستاذ التشريح  
قسم التشريح وعلم الأجنة  
كلية الطب - جامعة المنصورة - مصر

**الدكتور فيصل شمش**

أستاذ مساعد الأشعة التشخيصية والعلاجية  
كلية الطب - جامعة العرب الطبية

2009



بِسْمِ اللَّهِ الرَّحْمَنِ الرَّحِيمِ

وَإِنْ أَنْفَسْنَا أُفٍّ لَنَا أَفْئِدَةً بِصُورِهَا

حَاطِقِ اللَّهِ الْعَظِيمِ

الخارياق ، الايه 21.

# CONTENTS

---

---

Introduction.....	1
Aim of the work .....	4
Review of the literature .....	5
• Historical background .....	5
• Development of the ventricular system .....	12
• Anatomy of the ventricular system .....	18
• The Lateral ventricle .....	20
• Circumventricular organs .....	25
• Choroid plexus .....	26
• Imaging of the ventricular system .....	27
• Lateral ventricle in different diseases .....	34
Subjects and methods.....	40
Results .....	49
A- Morphometric analysis of the lateral ventricle.....	49
B- Sex differences in the lateral ventricle .....	108
C- Age changes in the lateral ventricle .....	112
Discussion.....	123
Summary and conclusion .....	130
References .....	133
Arabic summary .....	1

---

---

# ACKNOWLEDGMENTS

It is a great pleasure to acknowledge and thank those whose assistance, cooperation and support have made the completion of this thesis possible.

I am very grateful and indebted to my principal supervisor who showed me the light in the dark road. He is **Prof. Dr. Adel Bondok**, Professor of Anatomy, Faculty of Medicine, Mansoura University, Egypt. He designed the protocol of this thesis and helped me in all the details of this thesis from planning, writing, reading to revising and editing the thesis. He has been generous with his time, his criticisms were exclusively constructive and his generous support was unlimited. Not only that, but also he performed and produced all the statistical charts in a professional method. He asked me for nothing but perfection. I really can't express my gratitude to him and all that I can say is that "Allah blesses him".

I am grateful to my co-supervisor **Dr. Faisal Shembesh**, Assistant Professor of Radiology, Benghazi Radiodiagnostic and Therapy Center, Arab Medical University, for his kind support.

I am also very grateful to **DR. Iman Idris Ali**, Head of Department of Anatomy and Histology, Alarab Medical University, for her unlimited support, cooperation and encouragement.

I am also grateful to **Dr. Salha Zoubi**, Assistant Professor of Histology and **Dr. Idris Albarasi**, Lecturer of Histology, for their support.

I would like to thank my colleagues in the department of Anatomy and my friends for their encouragement and support.

I like to thank those at Benghazi Radiodiagnostic and Radiotherapy Center for allowing me to use their facilities.

Special thanks & love to my parent, wife and my son for their support, enthusiasm and care.

# INTRODUCTION

The human brain has been the focus of intense research over the centuries. It is well recognized that individuals vary considerably in brain volume, cytology, distribution of grey and white matter, gyral pattern, and in ventricular size (**Meyer, 1971**).

The ventricular system of the brain is continuation of the central canal of the spinal cord. They comprise four ventricles; right and left lateral ventricles, third ventricle, and fourth ventricle. Each ventricle contains a choroid plexus that produces cerebrospinal fluid (CSF) used to bathe and cushion the brain and the spinal cord. The total volume of CSF depends on the age but the normal adult volume of about 150 ml is reached by the age of 5 years. Normal volume of the lateral ventricles has been measured by ultrasound (US) and does not exceed 12 to 15 ml. The third ventricle contains only 1 ml of CSF (**Enzmann and Pelc, 1991**).

The cerebral ventricular system in man occupies a mean volume of approximately 20 ml, varying from 10 to 50 ml. The lateral ventricles represent about 90% of the total ventricular system volume (**Nolte, 1993**). Several pathological conditions as the processes of expansible intracranial masses, the meningo-ventricular infections and the intraventricular hemorrhage can

---



cause alterations of the ventricular volume (**Berman & Banker, 1966; Boasquevisque et al., 2000**).

The evaluation of the volume and measurements of the cerebral ventricles becomes important when one want to follow the evolution of the hydrocephaly or to define therapeutic conducts as the placement of ventricular valves which require reproducible results for evaluation and assessment or to assess other neurological diseases that interfere with normal and social activities like dementia and Alzheimer's disease where changes in the ventricles were observed (**Lombroso et al., 1968; Johnstone et al., 1976; Hobar et al., 1983; Hilpert et al., 1995; Liao et al., 1997; Garel & Alberti, 2006**). Evaluation of the cerebral ventricular system is a routine part of all fetal sonographic examinations. Ventriculomegaly and decreased choroid volume are indicators of poor fetal outcome, so it is important to know the normal variation of these parameters (**Hilpert et al., 1995**).

The CT (Computerized Tomography) and the MRI (Magnetic Resonance Imaging) are the methods more used in the evaluation of CNS diseases (**Degreeef et al., 1992; Buchsbaum et al., 1997; Chudgar, 1999; Bernasconi et al., 2000; Dale et al., 2000; Brambilla et al., 2001; Levine et al., 2002; Duffner et al., 2003**).

Several investigators have studied the cerebral ventricles quantitatively (**Gyldensted, 1977; DeCarli et al., 1992a & 1992b; Blatter et al., 1995; Hauser et al., 2000; Melhem et al., 2000; Jeong et al., 2005; Lewis et al., 2009**). However, the methods and the suitable equipments used for the morphometric

---

---

measurements and analysis are still controversial in the literature (Evans, 1942; Zatz 1979; Meese et al., 1980; McGahan & Phillips, 1983; Blumhagen & Mack, 1985; Shackelford, 1986; Jernigan et al., 1990; Riccabona et al., 1995).

---

# **AIM OF THE WORK**

The daily practice of magnetic resonance (MR) brain imaging technology requires a simple method to perform, which allows an accurate measurement of the ventricular system. The evaluation of the width of the lateral ventricles by means of the ventricular / hemispheric index, Evans' index and of the cross sectional areas are likely to meet all these requirements.

The present MR imaging-based morphometric study was carried out to define the normal quantitative values of the different parts of the human lateral ventricle to create a standard morphometric database of the cerebral ventricle in a normal Libyan population. It is also intended to compare the parameters of the right and left lateral ventricles in both males and females and to study the sex differences and age changes in the lateral ventricle from age of 20 years to age of 60 years. This database can be used as a guideline and as a reference for MRI diagnosis of different neurological diseases.

---

# REVIEW OF THE LITERATURE

## HISTORICAL BACKGROUND

The ventricular anatomy from its start in antiquity to the transition phase of the Renaissance has been the subject of interest of many anatomists. The localization of motor and sensory activities, and the localization of the mental processes or the seat of the soul in the ventricles of the brain were ancient. With the Renaissance there came an era where true knowledge, through dissections, revealed the actual structures of the ventricles and ended the unfounded arguments of ventricular function (**Longrigg, 1988; Staden, 1989; Tascioglu and Tascioglu, 2005**).

Both Erasistratus (ca 260) and Herophilus of Alexandria (ca 270) were particularly interested in the brain. They provided the first accurate and detailed description of the human brain including the ventricles (**Von Staden, 1989**). Like Alcmeon and the Hippocratic doctors before them, they had no question about the brain's dominant role in sensation, thought, and movement.

The functional role of the ventricles began with Herophilus of Alexandria (ca 270). Herophilus claimed that the fourth ventricle was the "command center" and compared the cavity in the posterior floor of the fourth ventricle with the cavities in the pens that were in use in

---

---

Alexandria at the time, and it is still called calamus scriptorius or sometimes calamus Herophili (**Longrigg, 1988**).

**Galen (129–199 AD) (Fig. 1)** was the most important figure in ancient medical science. He provided a detailed and accurate account of anatomy in general and anatomy of the brain in special. However, historians realized that his descriptions are remarkably accurate when applied to the monkey or ox (his usual subjects of dissection) but not on humans (**Singer, 1957**). He described the ventricles in considerable detail as four cavities and their connections. He described the two lateral (anterior), the third and the fourth ventricle and addressed them as crucial in his physiological system where the ventricles were the site of storage of psychic pneuma. The psychic pneuma (animal spirit) was the active principle of both sensory and motor nerves and the central nervous system. Although the ventricles particularly the anterior ventricle, were important as a source of psychic pneuma, he located the soul and higher cognitive functions not in the ventricles but in the solid portions of the brain around the ventricles. He claimed that when brain lesions penetrated to the ventricles, death did not invariably result even if both sensation and movement were lost. Being the greatest anatomist of antiquity, he did not, encourage his students to rely on illustrations, believing that direct visualization and handling of the structures was the only way to appreciate their form and relationship.

---



**Fig 1: Galen**

Quoted from Rocca  
**(1997)**

The early church authorities, in particular Nemesius, Bishop of Emesia (ca 390) and St Augustine (350–430) were very much concerned with the nonmaterial nature of the soul rather than the localization of the soul. They believed that soul cannot be localized in the heart as Aristotle did, and placed it in a much higher place at the temple, to encephalon. Nemesius put all the faculties of the soul into the ventricles following the same antero-posterior pattern as his contemporary Poseidonus (**Nemesius, 1955**).

The lateral ventricles were considered as one cavity, the first cell, the small room, or the vestibulum of the temple. It received impulses from the special senses and from the rest of the body and thus accommodated “sensus communis” the common sense. Since images were created from these sensations, so “imaginativa” imagination and “fantasia” fantasy were also in the posterior part of the first cell. The second cell (our third ventricle) or middle cell was the seat of the cognitive process: “ratio” reason, “aestimativa”

judgment or “cogitativa” thought. For the posterior third cell (our fourth ventricle), Galen’s original thought of motor function was changed to “memorativa” memory (**Singer, 1957; Tascioglu and Tascioglu, 2005**).

With the advent of Renaissance learning, the medieval cell doctrine began to lose ground. This gradual transition was brought about by a group of men who stand between the medieval period and the Renaissance. Men who learned the old ways began to assimilate and adopt the new. Leonardo de Vinci (1472–1519) (**Fig. 2**) was the first of these pioneers. His powerful extraordinary visual curiosity drove him to seek meaning in the structure and pattern of the body (**Gross, 1998; Tascioglu and Tascioglu, 2005**).

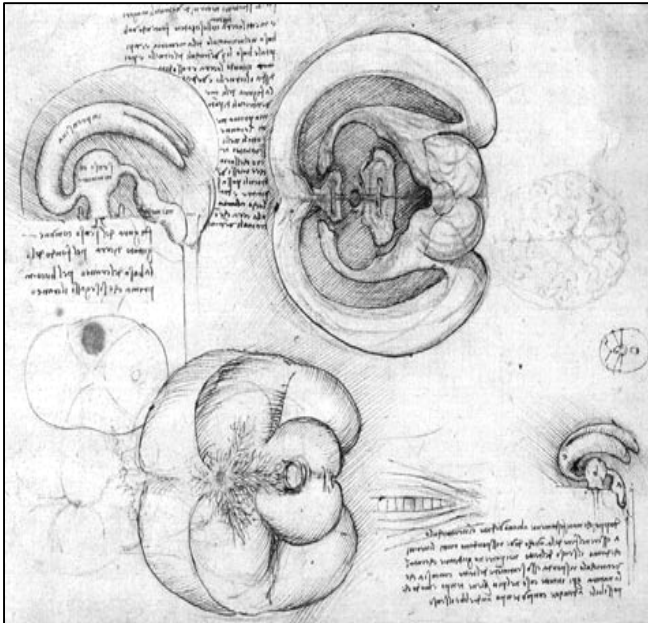


**Fig 2:** Leonardo de Da Vinci  
Quoted from **Tascioglu (2005)**.

Leonardo studied the ventricles using the sculptural technique of wax injection and revealed the shape of the ventricles. As he instructed," Make two vent-holes in the horns of great ventricles and insert melted wax with a syringe. Then when the wax has set, take away the brain and you will see the shape of the ventricles. But first put narrow tubes into the vents so that the air which is in the ventricles can escape and make room for the wax which enters into the ventricles" (**Keele, 1964**). The results of Leonardo’s wax studies stand out in **Fig. 3**. which shows a sagittal and axial sectional

---

anatomical drawing of the ventricles. In the axial view, posterior horns of the lateral ventricles are not visible. It was probably due to the absence of air vents in the posterior horns and the use of unpreserved brain (**Clarke and Dewhirst, 1972**).



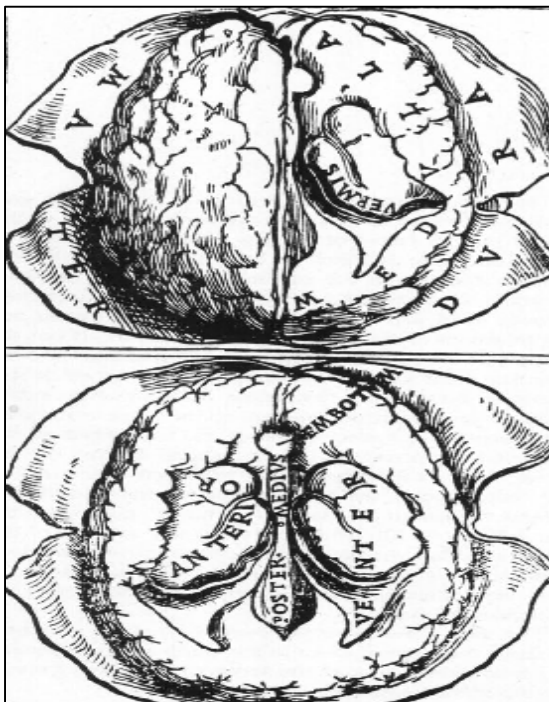
**Fig.3.** Drawings of Leonardo da Vinci after his wax injection studies (1504–1507) (**Clarke and Dewhirst, 1972**)

About 20 years after Leonardo's wax studies, Berengario da Carpi (1460–1530) published his book "Isagoge Breves" in 1522. His anatomical illustrations were more like pictures and were much improved compared to Leonardo's illustrations. **Figure 4 (Clarke and Dewhirst, 1972)** shows the brain from above with one ventricle opened to show the vermis. In this figure, vermis shown as the sitting place of the choroid plexus where as in the dynamic cell doctrine it acted as a valve between cells one and two. Berengario located all the mental functions in the lateral ventricles and he argued that the other ventricles dealt with excretion, motion and sensation. His most famous book "Tractates' ed Fractua Calve Sive Cranei" is a surgical

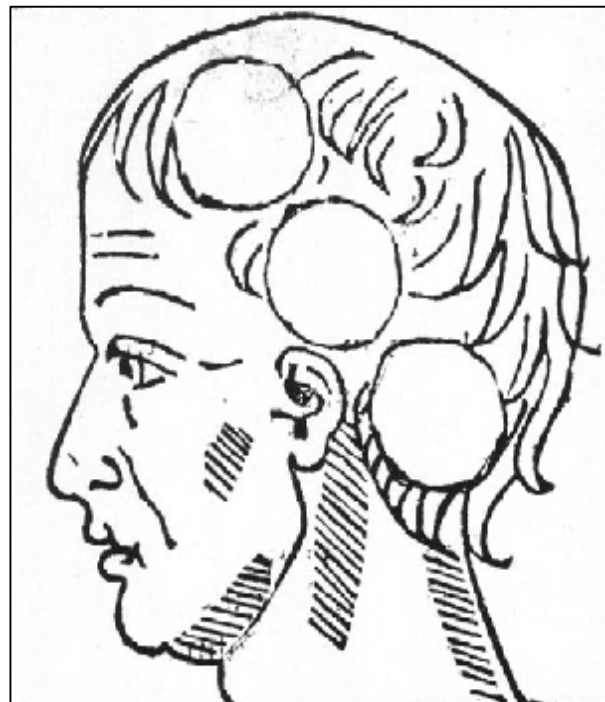

text on cranial fractures. On the cover of his book, there is a head in profile showing the three cells (Fig. 5).

Andreas Vesalius of Pauda (1514–1564) (Figs. 6, 7), is known as the greatest of the Renaissance Anatomists. In his remarkable book “De Humani Corporis Fabrica” 1543 (Poynter, 1964), Vesalius argued against placing the functions of the soul in the ventricles. He argued that many animals have ventricles similar to those of humans and yet they were denied a reigning soul.




**Figure 4.** Anatomical illustration from *Isagoge Breves* (Clarke and Dewhirst, 1972).

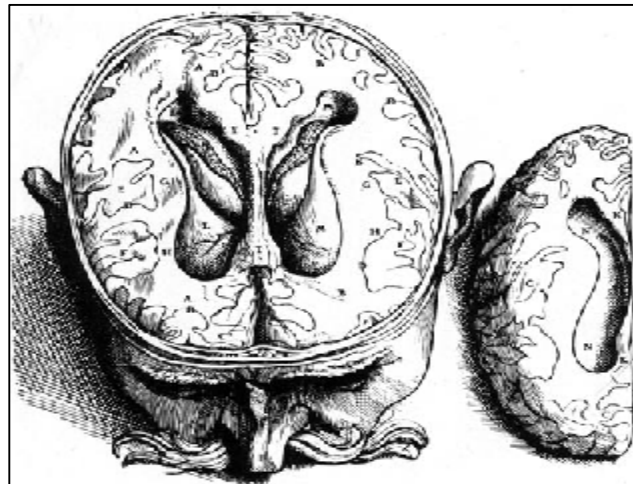


**Figure 5.** Cover of the famous book of Berengario da Carpi “*Tractatus ed Fractua Calve Sive Cranei*” (Clarke and Dewhirst, 1972).

With the work of Renaissance artists and Vesalius, the true anatomy of the ventricular system was established. It was shown that the ventricles contained a fluid, what is now called cerebrospinal fluid and it was highly unlikely that mental functions took place within it (**Dopson, 1927; Tascioglu and Tascioglu, 2005**).



**Fig. 6.** Andreas Vesalius.  
(**Tascioglu & Tascioglu**  
, 2005).



**Fig. 7.** Brain ventricles from his  
Book De Fabrica (**Tascioglu**  
& **Tascioglu, 2005**).

## **DEVELOPMENT OF THE VENTRICULAR SYSTEM**

The central nervous system appears at the beginning of the third week and takes origin from an elongated area of ectoderm, the neural plate, situated in the axial region of the embryo in front of Hensen's node and the primitive streak (**Hamilton et al., 1972; Sadler, 1998; Larsen, 2001; Dudek & Fix, 2005**). The neural plate shows a median groove, the lateral margins of this groove grow and meet to form neural tube. At an early stage, on day 19, as the result of differential growth, this simple neural tube shows a demarcation into a cylindrical and elongated caudal portion, which becomes the spinal cord, and a shorter and broader cephalic portion, which becomes the brain. The central cavity of the developing brain soon shows three segmentally arranged dilatations known as the primary brain vesicles. Their cavities become the subsequent cerebral ventricles and aqueduct. The rostral dilatation is called the forebrain vesicle and its wall forms the prosencephalon. The intermediate dilatation is the midbrain vesicle; its wall forms the mesencephalon. The caudal dilatation is the hindbrain and its wall forms the rhombencephalon. The mesencephalon shows no fundamental changes in the subsequent development like the other two vesicles

---

---

that undergo marked modification. The rhombencephalon is subdivided during the fifth week into a more rostral, metencephalon that gives origin to the pons and cerebellum, and a more caudal myelencephalon that develops into the medulla oblongata. The prosencephalon divides into a postero-superior median portion, called the diencephalon and an antero-inferior pair of laterally directed invaginations in the developing cerebral vesicles and representing the future lateral ventricles.

The cavity of the diencephalon is called the third ventricle. Postero-inferiorly, it communicates freely with the mesencephalic cavity; antero-superiorly, it communicates on each side with the corresponding lateral ventricle by a large aperture, the future interventricular foramen (foramen of Monro). The fourth ventricle represents the cavity of the original rhombencephalon, and the mesencephalic cavity becomes the cerebral aqueduct of Sylvius (**Hamilton et al., 1972; Sadler, 1998; Larsen, 2001; Dudek & Fix, 2005**).

As the development proceeds, the lateral ventricle initially occupies most of the volume of the hemisphere but it progressively constricted by the thickening of the cortex. However, along the line between the floor and the medial wall of the hemisphere, the cerebral wall does not thicken but instead remains thin and form a groove called choroid fissure. A choroid plexus develops along the choroid fissure. The lateral ventricle extends the whole length of the hemisphere, reaching anteriorly into the frontal lobe and its posterior

---

---

end reaching the occipital lobe and curves around to occupy the temporal lobe (**Larsen, 2001; Dudek & Fix, 2005**).

The configuration of the third ventricle becomes more like that of the adult and each interventricular foramen becomes relatively smaller (**Boyd, 1955; Hamilton et al., 1972**). During the third month of fetal development, the telencephalon undergoes rapid growth more than the rest of the brain. Ventrally, the growth associated with the basal ganglia and the cortical component of the ventral telencephalon has no ventricular cavity beneath it and becomes the cortex of the insula. Because of the differential growth pattern between the pallium, or cerebral cortex, and the basal ganglia, the pallium expands like the shell of the cavity being the lateral ventricle. At the same time, the rapidly growing basal ganglia push into the cavity an expanding fist that make the ventricle curve around the basal portion of the telencephalon in a C-shape manner. After the closure of the caudal neuropore, the developing brain ventricles and the central canal of the spinal cord become filled with the cerebrospinal fluid (**Burt, 1993; Dudek & Fix, 2005**).

---

---

---

## **SOME STUDIES ON DEVELOPMENT OF THE LATERAL VENTRICLE**

**Saliba et al. (1990)** performed study on 87 preterm infants of 27 to 36 weeks' gestational age using serial ultrasound imaging of the brain and reported that lateral ventricle area measurements increased as age and head circumference increased. During the first six weeks of life, the rate of growth was 0.53 cm/week and the mean postnatal ventricular area growth velocity was 0.39 mm<sup>2</sup>/ week. A reference range for lateral ventricle area developed from these serial measurements.

**Alagappan et al. (1994)** studied 500 fetuses to reassess the mean size of the lateral cerebral ventricular atrium by using axial ultrasound. Eleven fetuses had ventricular atrial measurements of 10 mm or more. The mean size of the ventricular atrium was 6.6 mm. They concluded that use of 10 mm as the upper limit of normal for the ventricular atrial measurement should be continued. Measurements of 10 mm or above should prompt a careful search for associated fetal abnormalities and consideration of amniocentesis.

**Hilpert et al. (1995)** described the normal size of the fetal lateral ventricular atrium in 608 healthy fetuses from 13 to 42 weeks' menstrual age. The atrium of the lateral ventricle was measured in the axial and coronal planes and was confirmed with previous observations.

---

**Nadel and Benacerraf (1995)** investigated the presence of a sex difference in the size of the fetal lateral ventricular atrium. The width of the lateral ventricular atrium was measured sonographically on 543 fetuses scanned at 17- 40 weeks. Lateral ventricular measurements of male and female fetuses were compared. They concluded that male fetuses have slightly larger cerebral lateral ventricles than female fetuses.

**Achiron et al. (1997)** used ultrasonography to study asymmetries of the fetal lateral ventricles in 7200 pregnant women. Lateral ventricular asymmetry was found in 21 subjects. In 15 fetuses, the body or the occipital horn of the left lateral ventricle was larger than the right, whereas in six fetuses, the right was larger than the left. They concluded that some degree of asymmetry of the lateral ventricles exists in the human fetal brain and is detectable in utero.

**Liao et al. (1997)** used ultrasound scans to measure the lateral ventricles of 540 neonates. In their study, coronal scans showed that the distance between the falx and the lateral wall of the body of the lateral ventricle and the greatest axis of the lateral ventricle correlated with increasing gestational age.

**Fannon et al. (2000)** investigated the developmental correlations of ventricular enlargement. Information on childhood development and magnetic resonance images were collected from 21 patients experiencing a first episode of psychosis. In their results,

---

---

21 patients had significantly less whole brain volume and enlarged third and lateral ventricles compared to 25 controls. They concluded that enlargement of both third and lateral ventricles are present in first-episode psychosis.

---



---

## **ANATOMY OF THE VENTRICULAR SYSTEM**

The cerebral ventricular system consists of series of interconnecting spaces and channels within the brain that are derived from the lumen of the embryonic neural tube and the cerebral vesicles. Within each cerebral hemisphere lies the large C-shaped lateral ventricle. Near its rostral end the lateral ventricle communicates through the interventricular foramen (foramen of Monro) with the third ventricle, which is midline, slit-like cavity lying between the two thalami and bounded inferiorly by hypothalamus. Caudally, the third ventricle is continuous with the cerebral aqueduct, a narrow tube that passes the length of the midbrain that is continuous with the fourth ventricle. The fourth ventricle is a tent shape cavity of the hindbrain and continues downward with central canal of the spinal cord. The ventricular system contains cerebrospinal fluid (CSF), which is mostly secreted by the choroid plexuses located within the lateral, third and fourth ventricles (Fig.8). CSF flows from the lateral to third ventricles via foramen of Monro then passes into the fourth ventricle. It leaves the fourth ventricle through three apertures to reach the subarachnoid space surrounding the brain (**Carpenter and Sutin, 1983; Burt, 1993; FitzGerald& Folan-Curran, 2002; Standing et al., 2005**).

---

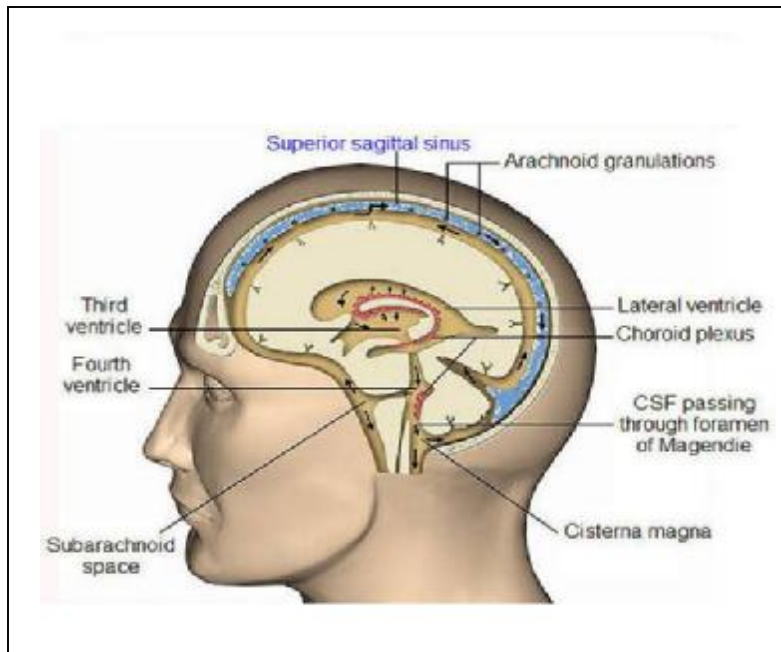


Fig.8. The ventricular system. (Standing et al., 2005)

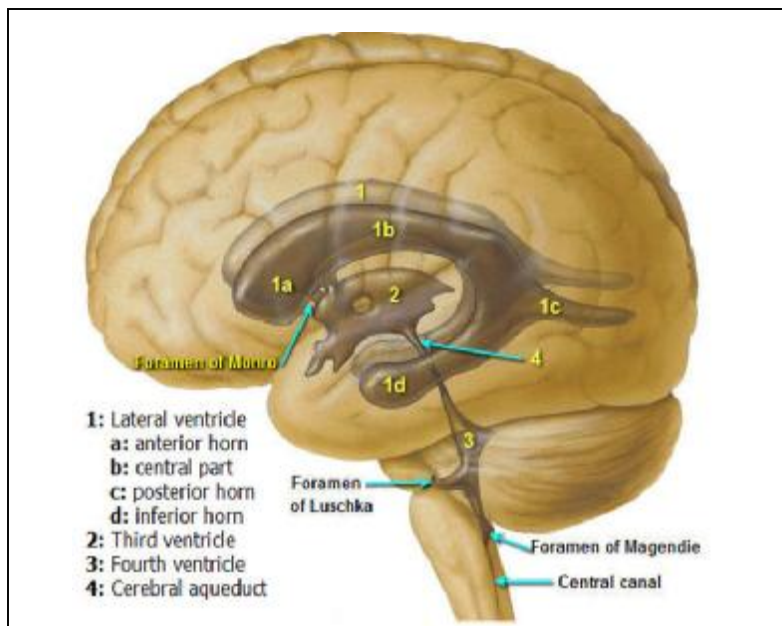


Fig.9. The parts of the lateral ventricle. (Standing et al., 2005)

## **THE LATERAL VENTRICLE**

Viewed from its lateral aspect, the lateral ventricle has a roughly C-shaped profile with an occipital tail. The shape is a consequence of the developmental expansion of the frontal, parietal and occipital regions of the hemisphere that displace the temporal lobe inferiorly and anteriorly (Fig.9). Both the caudate nucleus and the fornix have adopted similar morphology, so that the caudate nucleus encircle the thalamus and the fornix traces the outline of the ventricle forward to the interventricular foramen. The lateral ventricle is customarily divided into a body and 3 horns: anterior, posterior and inferior (**Carpenter and Sutin, 1983; Standing et al., 2005**).

The anterior (frontal) horn lies within the frontal lobe anterior to the interventricular foramen. The posterior aspect of the genu of the corpus callosum bound it anteriorly. The roof is formed by the anterior part of the body of the corpus callosum. The anterior horns of the two lateral ventricles are separated by the septum pellucidum. The coronal profile of the anterior horn is roughly a flattened triangle in which the head of the caudate nucleus projects into the lateral wall (**Standing et al., 2005**).

The body lies within the parietal lobe and the posterior part of the frontal lobe. It extends from the interventricular foramen to the splenium of the corpus callosum. The bodies of the lateral ventricles

---

---

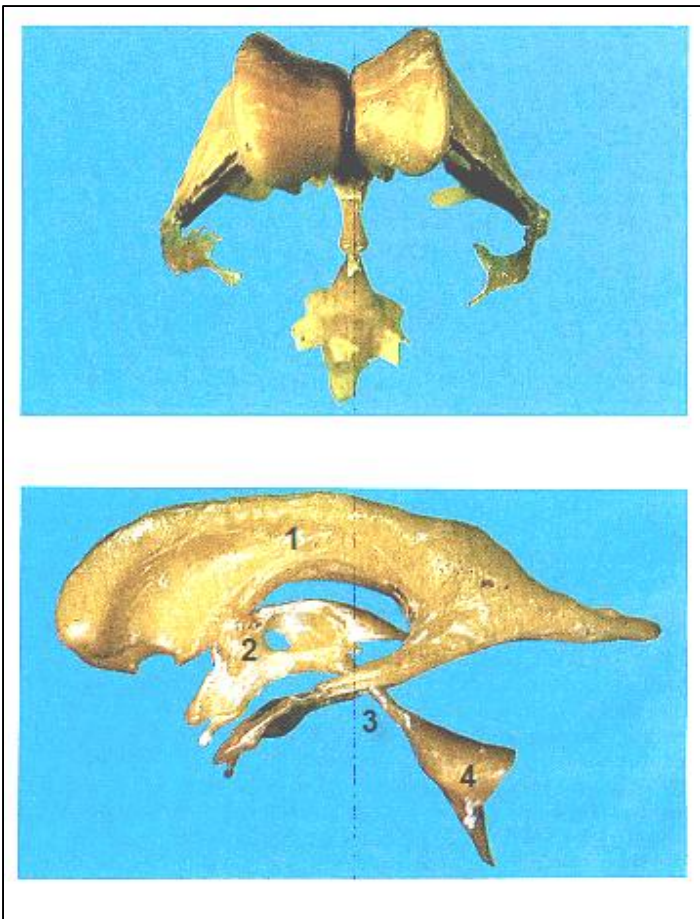
are separated by the septum pellucidum, which is attached to the body of the fornix. The coronal profile of the body of the ventricle is flattened triangle with inward bulging lateral wall formed by the thalamus inferiorly and the body of the caudate nucleus superiorly. The boundary between the thalamus and the caudate nucleus is marked by a groove that is occupied by the stria terminalis, and by the thalamostriate vein. The fornix is separated from the thalamus by choroidal fissure that is occluded by the choroid plexus. The body widens posteriorly to become continuous with the posterior and inferior horns at the collateral trigone or the atrium (**Burt, 1993**).

The posterior (occipital) horn curves postromedially into the occipital lobe. It is usually diamond-shaped or square in outline. The two sides are often symmetrical. Fibers of the tapetum of the corpus callosum form the lateral wall and the roof of the posterior horn and separate the ventricle from the optic radiation. Fibers of the splenium of the corpus callosum (forceps major) pass medially as they sweep back into the occipital lobe and produce a rounded elevation in the upper medial wall of the posterior horn called bulb of the posterior horn. A second elevation below the bulb is called the calcar avis and is produced by the deeply infolded cortex of the calcarine sulcus (**FitzGerald& Folan-Curran, 2002; Standing et al., 2005**).

The inferior (temporal) horn extends forwards into the temporal lobe. It curves round the posterior aspect of the thalamus (pulvinar). It curves anteriorly to end within 2.5 cm of the temporal pole, near the uncus. Its position relative to the surface of the hemisphere usually

---

corresponds to the superior temporal sulcus. The roof of the inferior horn is formed mainly by the tail of the caudate nucleus and the stria terminalis, which connects the amygdala at the anterior end of the ventricle with the septal area. The floor of the ventricle consist of the hippocampus medially and the collateral eminence, formed by the infolding of the collateral sulcus, laterally. The inferior part of the choroid fissure lies between the fimbria and the stria terminalis in the roof of the temporal horn. The temporal extension of the choroid plexus fills this fissure and covers the outer surface of the hippocampus.



**Fig 10:** Resin cast of the ventricular system of the human brain showing lateral (1), the third ventricle (2) the cerebral aqueduct (3) and the fourth ventricle (4). Quoted from **Standing et al. (2005)**.

---

Both the lateral ventricles communicate via the foramina of Monro with the third ventricle, found centrally between the two thalami and the hypothalamus. The third ventricle communicates with the fourth ventricle via the cerebral aqueduct. Three foraminae (median and two lateral apertures) communicate the fourth ventricle with the subarachnoid space. The fourth ventricle continues with the central canal, allowing CSF to bathe the inside surface of the spinal cord as well (**Carpenter and Sutin, 1983; FitzGerald & Folan-Curran, 2002**).

Several studies support frequent reports of an asymmetry favoring an increased volume of the left compared to the right lateral cerebral ventricle (**Shenton et al., 1991**).

In study of **Celik et al. (1995)**, CT examination of 100 cases with no physical or neurological deficits revealed that the sizes of the cerebral ventricles increase with age in both sexes. Increase in the size of the third ventricle by age was statistically significant. Compared to women, the size of the third ventricle was larger in men.

**Mu et al. (1999)** performed a study to define the range of normal volume for the temporal horn of the lateral ventricle in different age groups ranging from 40 to 90 years in order to generate a guideline for the MR diagnosis and differential diagnosis of early Alzheimer disease. Their results concluded that differences in the mean value of standardized volumes of the hippocampal formation,

---

---

the amygdala, and the temporal horn correspond to differences in age among healthy subjects.

**Sullivan et al. (2002)** used MRI performed twice, 4 years apart, to compare rates of age-related size change of the corpus callosum, which inconsistently observed to thin with age, with change in the lateral ventricles, which are well established to enlarge. Percent change in size was significant for both the callosal and ventricular measures, but annual rate of ventricular expansion was significantly greater than annual rate of callosal thinning.

---

## **CIRCUMVENTRICULAR ORGANS**

The circumventricular organs are midline sites in the ventricular walls where the blood brain barrier is absent (**McKinley et al., 2003**). They include the vascular organ, subfornical organ, neurohypophysis, median eminence, subcommissural organ, pineal gland, and area postrema.

The circumventricular organs are six patches of brain tissues close to ventricular system contain neurons and specialized glial cells abutting fenestrated capillaries (**FitzGerald & Folan-Curran, 2002**). Specialized ependymal cells called tanycytes are also present and may be involved in secretions into CSF and transport of neurochemicals from subjacent neurons, glia or vessels to the CSF and transport of neurochemicals from CSF to the adjacent structures (**Carpenter and Sutin, 1983; Standing et al., 2005**). In addition, these ependymal and subependymal glia cell layers are the source of undifferentiated stem cells in the adult (**Mercier et al., 2002**), currently under intensive study for their potential neurorestorative properties.

---



## **CHOROID PLEXUS**

In the roof of the third and fourth ventricles, and in the lateral ventricle along the line of the choroid fissure, the vascular pia mater lie in close apposition to the ependymal lining of the ventricles forming telachoroida which gives rise to highly vascularized choroid plexus. CSF secreted by the choroid plexus into the ventricles at rate of about 500 ml per day (**Burt, 1993; Dudek & Fix, 2005; Standing et al., 2005**).

In the lateral ventricle, the choroid plexus extends anteriorly as far as interventricular foramen. From which, the plexus passes posteriorly, in contact with the thalamus, curving round its posterior aspect (pulvinar) to enter the inferior horn of the ventricle and reaches the hippocampus. Throughout the body of the ventricle, the choroid plexus lies between the fornix superiorly and the thalamus inferiorly (**Carpenter and Sutin, 1983**).

The blood supply of the choroid plexus in the lateral ventricle is usually via the anterior choroidal branch of the internal carotid artery and several choroidal branches of the posterior cerebral artery (**Burt, 1993; FitzGerald & Folan-Curran, 2002**).

---

## **IMAGING OF THE VENTRICULAR SYSTEM**

The history of neuroimaging began in the early 1900s with a technique called pneumoencephalography. This process involved draining the cerebrospinal fluid from around the brain and replacing it with air, altering the relative density of the brain and its surroundings, to show up better on an x-ray. It was considered to be incredibly unsafe for patients (**Griscom and O'Connor, 1995**). A form of magnetic resonance imaging (MRI) and computed tomography (CT) were developed in the 1970s and 1980s. The new MRI and CT technologies were considerably less harmful. Next come Positron Emission Tomography (PET) scans, which allowed scientists to map brain function. Learning from MRI, PET scanning, scientists were able to develop functional MRI (fMRI) with abilities that opened the door to direct observation of cognitive activities (**Chmielowski et al., 2004; Srijit and Shipra, 2007; Jain et al., 2008**).

**Moniz (in 1927)** introduced cerebral angiography, whereby both normal and abnormal blood vessels in and around the brain could be visualized with great accuracy (Quoted from **Gawish et al., 2005**).

Ultrasound being a safe, quick, noninvasive & repeatable modality has a definite role in diagnosis of hydrocephalus. However, the ultrasound waves cannot penetrate the bony skull. It is still used in neonatal brain imaging where the open anterior fontanelle is the

---

---

acoustic window. Hence, its use is limited between age group 6 months- 2 years. Often hydrocephalus can be diagnosed in utero by 15 weeks gestation. The ventricular height and the diagonal width are more appropriate for assessing ventricular dilatation in preterm neonates. In utero, an upper limit of 10 mm for the ventricular atrium is considered significant and hydrocephalus can be suspected (**Berg et al., 2000; Ichihashi et al., 2005; Correa et al., 2006**).

With the advent of computerized axial tomography (CAT), ever more detailed anatomic images of the brain became available for diagnostic and research purposes. The names of **Oldendorf in 1961 Hounsfield and Cormack in 1973** ( Quoted from **Gawish et al., 2005**) are associated with this revolutionary innovation, which enabled much easier, safer, non-invasive, painless and to a reasonable extent repeatable neuro-investigation.

Certain CNS abnormalities can be missed with routine US, especially if the ventricles are not dilated, as in the case of agenesis of the corpus callosum, this problem noted by **Bennett et al., (1996)**. Because of these limitations, magnetic resonance (MR) imaging has been suggested as a useful adjunct in cases in which US findings are nonspecific (**Sonigo et al., 1998**). MR imaging allows acquisition of multipalnar views and direct visualization of the brain parenchyma, thus providing a detailed evaluation of CNS anatomy in a manner not possible with US (**Levine et al., 1997; Erdem et al., 2007; Hakyemez et al., 2007**).

---

---

The possibilities of differentiation between a "normal" and an "enlarged" ventricular system by means of computerized tomography are limited. On the other hand, that differentiation is essential for the diagnosis of ventricular enlargement, hydrocephalus and brain atrophy. The daily practice requires a method, which allows an accurate measurement as well as a quick and simple performance. The evaluation of the width of the lateral ventricles by means of the ventricle index (VI) and of the ventricle-hemispheric index (V/H) using computed tomogram is likely to meet all these requirements (**Reisner et al., 1980**).

In the study of **Brinkman et al. (1981)**, quantitative indexes of computed tomography included bifrontal, bicaudate ratios and ventricular / brain ratio (VBR) were compared in patients with Alzheimer dementia and in elderly persons with no history of neurologic diseases. Age-correlated ventricle-brain ratios were abnormal for half of the dementia patients; where as only a single subject in the control group had ventricles outside the limits of normal variation. Employment of quantitative indexes standardized for age may aid in differentiating cerebral atrophy associated with dementia from that associated with normal aging.

Study of the ventricular system with computed tomography has been of interest since the introduction of this modality. **Hughes and Gado (1981)** studied four linear measurements of the ventricular system. Three of these measurements were taken from the image at the level of the foramen of Monro. **A**= the width of the third ventricle;

---

---

**B**= the sum of the shortest distances between the caudate nucleus and the septum pellucidum; **C** = the width of the lateral ventricles just anterior to the foramen of Monro. **D** = the width of the narrowest part of the bodies of the lateral ventricle. The widest interparietal distance was measured from the image showing that part of the ventricle. A ventricular score (VS) was obtained with the following equation:

$$VS = A + B + C + D / \text{Interparietal distance}$$

**Hirashima et al. (1983)** studied the measurements of the area of the anterior horn of the right lateral ventricle and four ventricular indices from the CT scans of 198 normal cases: (1) maximum width of the anterior horns; (2) minimum width of the anterior horns; (3) sum of these maximum and minimum widths; and (4) the ventricular index. The size of the ventricular system increased steadily with age. The sum of the maximum and minimum widths of the anterior horns was most highly correlated with the area of the right anterior horn.

The premature infant brain has been thoroughly studied by sonography and normal standards for ventricular size have been established (**Hobar et al., 1983**). **Winchester et al. (1986)** examined the normal appearance of the lateral ventricles in 53 healthy full-term infants by sonography on the first to sixth days of life. Vaginal delivery had a statistically significant association with these “compressed” lateral ventricles. Their study indicates that asymmetric ventricular size may be normal, and that shortly after birth most healthy infants have “compressed” lateral ventricles that should not be interpreted as cerebral edema.

---

---

**Blatter et al. (1995)** presented a normative volumetric database of total brain volume and total ventricular volume, based on a multispectral segmentation of brain MR. In this study standard axial T2-weighted MR images were performed. They concluded that these normative data tables could provide a comparison index for contrasting pathologic groups with a normative sample.

**O'Hayon et al. (1998)** compared volumetric area and linear measurement of ventricular size in pediatric patients with hydrocephalus. Sixty-four CT, MRI, and US scans from 25 children aged 0 -17 years with hydrocephalus were measured. Measurements included ventricular volume, a ventricular/brain ratio, and four standard linear measures (Evans' index, minimal lateral ventricular width, lateral ventricular span at the body and the frontal and occipital horn ratio). They concluded that the frontal/occipital horn ratio (FOR) is a simple method of evaluating ventricular size in pediatric hydrocephalus patients.

**Kulkarni et al. (1999)** characterized the measurement properties of the FOR in children with hydrocephalus. They concluded that the FOR is simple and linear reproducible method for assessments of hydrocephalus.

**Levine et al. (2002)** elucidated the imaging appearance of the fetal cerebral ventricles by comparing ultrasonographic and MR images. They reviewed MR and US images of 110 normal fetuses and 94 fetuses with central nervous system abnormalities to assess lateral ventricular morphology. They concluded that ventricular

---

---

contours differ with differing diagnosis of central nervous system abnormalities.

The development of a computer-assisted ultrasonic device offers new perspectives for the quantification of ventricular volume. **Csutak et al. (2003)** examined 250 healthy neonates with 3D cranial ultrasound. The volume of both lateral ventricles and the third ventricle were separately quantified and summated for the calculation of ventricular volume. The correlation between body weight, head circumference, gestational age and ventricular volume was statistically significant. 3D US appear to be an accurate imaging modality for the exact calculation of ventricular volume and therefore should be incorporated into the cranial sonographic assessment of ventricular size in infants.

**Duffner et al. (2003)** scanned thirty healthy volunteers and thirty patients suffering from hydrocephalus using high-resolution 3-D MR imaging. In healthy volunteers, the measurements confirmed the results previously obtained from ventriculography and from anatomic casts. In hydrocephalic patients, the ventricular system was found to be enlarged asymmetrically.

**Grasby et al. (2003)** studied 81 preterm neonates by ultrasound scans obtained nearest to 6 weeks of age. The ventricular index, the diagonal width and the ventricular height were measured and were used to grade the degree of dilatation. They concluded that the ventricular height and the diagonal width are more appropriate for assessing ventricular dilatation in preterm neonates.

---

---

**Ichihashi et al. (2005)** assessed ventricular volume with 3D ultrasonography and found that the lateral ventricular size became larger during the first two weeks after birth. The left ventricle was larger than the right one. There was no correlation between lateral ventricular volume and birth weight.

**Garel and Alberti (2006)** evaluated the similarities between fetal ultrasonography and MRI in the measurement of atrial diameter of the lateral ventricle on a coronal slice at the level of the choroid plexuses in 106 fetuses. Their results showed that the two techniques yielded results in close agreement. Ventricular atrial diameters below 10 mm tended to be slightly overestimated by ultrasonography, whereas those above 10 mm tended to be underestimated in comparison to measurements by MRI.

**Kazan-Tannus et al. (2007)** assessed which imaging plane is most reproducible for the performance of brain volumetry measurements in fetuses referred for ventriculomegaly. The results showed that the volumes increased with gestational age. They concluded that supratentorial parenchyma and lateral ventricular volumes can be reliably measured on fetal MRI, and imaging plane was not an important factor in measurement.

---



## **LATERAL VENTRICLE IN DIFFERENT DISEASES**

The abnormality in the normal pressure hydrocephalus (NPH) occurs secondary to an abnormality in fluid removal, leading to an increase in ventricular size and encroachment of enlarged ventricles on adjacent brain tissue. The pressure exerted on the cerebral parenchyma by immense fluid-filled cavities deforms white matter tracts, causes gait abnormalities and incomplete control of the bladder, as well as difficulties in processing incoming stimulation and in producing responses. MRI or CT typically demonstrates ventricular dilation with preservation of the surrounding brain tissue. Compared with studies of normal patients, MRI of patients who have NPH demonstrates ventriculomegaly and maintained cerebral parenchyma. This finding is in contrast to the ventricular dilation associated with significant loss of brain tissue evident in images of patients who have Alzheimer's disease (**Verrees and Selman, 2004**).

Dilatation of the temporal horns, increased frontal horn radius, and acuteness of the ventricular angle have been described as the classic structural changes suggestive of hydrocephalus (**El Gammal et al., 1987; Segev et al., 2001**).

---

---

**Anderson et al. (2002)** used a three-dimensional analysis to measure ventricular volume changes after shunting for idiopathic normal pressure hydrocephalus (INPH). They observed a decrease in ventricular volume after shunting in 10 of 11 patients.

**Ernestus et al. (2002)** examined thirty patients with occlusive hydrocephalus by the relevance of differentiated MR imaging. They found that MRI allows a very precise estimation of the pathophysiological and the anatomic prerequisites for endoscopic procedures.

**Bazán-Camacho et al. (2004)** described the evolution of ventricular dilatations during the early years of life as well as how to carry out a prospective estimate of the changes in the ventricular measurements for hydrocephalus by using ultrasonography. They concluded that ultrasonic encephalography plays a valuable role in the diagnosis and follow-up of ventriculomegalies.

**Lee et al. (2005)** evaluated the correlation between gait disturbance and midbrain diameter and the width of the lateral ventricles in patients with idiopathic normal pressure hydrocephalus (NPH) by using MRI. The results showed that the maximal midbrain diameter was significantly smaller in the NPH group than in the controls, there were inverse correlations between the midbrain diameter and the width of the lateral ventricles. They concluded that midbrain atrophy is significantly associated with gait disturbance in NPH.

---

---

Enlargement of the lateral cerebral ventricles is one of the earliest reported structural brain imaging abnormalities found in schizophrenia, as well as one of the most stable findings in morphometric investigations (**Buchsbaum et al., 1997; Mata et al., 2009**). **Raz et al. (1987)** studied the size of the cerebral ventricles of 14 young patients with schizophrenia and 12 controls. A volumetric analysis of the same 26 scans revealed enlargement of the lateral and third ventricles in the schizophrenics. On the other hand, **Wright et al. (2000)** have implicated preferential enlargement of the temporal horn or body of the ventricles. They found that the mean cerebral volume of the subjects with schizophrenia was smaller, but the mean total ventricular volume was greater.

**Nopoulos et al. (1997)** studied volumes of major brain regions of eighty schizophrenic patients (40 male and 40 female) and 80 healthy volunteers matched by sex and age. They concluded that male and female patients with schizophrenia have the same pattern of structural brain abnormalities, but male patients appear to manifest greater severity, especially with regard to ventricular enlargement.

**Gaser et al. (2004)** reported that thalamic shrinkage, especially of medial nuclei and the adjacent striatum and insular cortex, appear to be important contributors to ventricular enlargement in schizophrenia.

---

---

**Nakamura et al. (2004)** designed a study to investigate the extent to which schizophrenia patients can be differentiated from normal subjects by structural brain measures by using MRI. Significant enlargements of the left and right body of the lateral ventricle were observed in the male patients. Significant enlargements of the left inferior horn were observed in the female patients.

**Styner et al. (2005)** explored the effects of heritability and genetic risk for schizophrenia reflected in ventricular size and structure. They examined ventricular shape and size in the MRI studies of monozygotic (MZ) twin pairs discordant for schizophrenia, healthy MZ twin pairs, healthy dizygotic twin pairs, and healthy nonrelated subject pairs. Their results suggest that genetics have stronger influence on the shape of lateral ventricles than do the disease-related changes in the schizophrenia.

**Beats et al. (1991)** and **Wurthmann et al. (1995)** studied ventricular enlargement in geriatric depression and control persons with computed tomography. They found that patients with geriatric depression had a remarkable enlargement of the ventricles.

Abnormally large brain ventricles have been reported frequently in bipolar disorder. In addition, lateral ventriculomegaly might progress with repeated affective episodes and greater illness severity in bipolar disorder (**Davis et al., 1998; Hauser et al, 2000**).

---

---

Studies of patients with unipolar depression suggest associations between greater lateral ventricular volume and basal ganglia abnormalities (**Strakowski et al., 2000**).

**Fiske et al. (2005)** performed cerebral ultrasound examinations in 35 infants and early signs of ventricular dilation were reviewed. They noticed that displacement of the medial wall of the body of the lateral ventricle toward the midline is an earlier sign of ventricular dilation than the displacement of the lateral wall away from the midline.

**Berg et al. (2000)** examined 74 subjects with multiple sclerosis (MS) and ages- and sex-matched control subjects with MRI to assess the cross sectional area of the frontal horns of the lateral ventricles which were significantly larger in subjects with MS than in healthy ones. They concluded that measurement of the cross sectional area of the cerebral ventricle with MRI is quick and easy surrogate marker for serial follow-up examinations in patients with MS. Moreover, **Dalton et al. (2002)** investigated ventricular enlargement over one year in patients with MS and found significant ventricular enlargement in 27 of 55 patients who fulfilled the MRI criteria for MS.

**Melhem et al. (2000)** reviewed MR images of children with spastic cerebral palsy and found that lateral ventricular volumes of the moderate and marked motor deficit groups were significantly larger than those of the control and mild motor deficit groups.

---

---

**Bradley et al. (2002)** studied elderly subjects by serial volumetric brain MRI scans and concluded that rate of change analysis makes serial brain MRI a valuable surrogate marker for Alzheimer's disease.

**Schmidt et al. (2004)** studied the association of diabetes to MRI detected brain lesions to in 1,252 elderly individuals. The linear measurements of the ventricular diameter relative to the intracranial cavity defined the severity of subcortical atrophy. Diabetes was associated with cortical brain atrophy defined by ventricular dilatation but not with any focal brain lesions or subcortical atrophy.

Hemorrhage into the ventricles of the brain is one of the most serious complications of premature birth. Large intraventricular hemorrhage has a high risk of neurological disability and over 50 % of these children go on to develop progressive ventricular dilatation (**Sadleir and Tang , 2009**).

# **SUBJECTS AND METHODS**

## **A. SUBJECTS**

A total of 160 neurologically healthy Libyan individuals of both sexes (80 men of age 20 - 60 years and 80 women of age 20 - 60 years) were drawn from a Benghazi community and were referred to the MRI unit for different reasons other than neurological disorders. They underwent a medical interview to exclude notable neurologic or psychiatric illnesses. Persons who reported history of cardiovascular, neurological or psychiatric conditions, head trauma with loss of consciousness, thyroid problems and diabetes as well as persons who reported taking anti-seizure medication, anxiolytics or antidepressants were excluded from the study. They were subjected to MR imaging of the lateral ventricle, after taking their consent, at Benghazi Radiodiagnosis and Radiotherapy Center.

## **B. METHODS**

### **1. IMAGE PROCESSING & ACQUISITION**

High-resolution fast spin-echo T2-weighted MR images of the lateral ventricle at coronal and axial planes were acquired on Philips 1.5 Tesla scanner (equipped with high-performance gradients by using a manufacturer-supplied quadrature head coil (Philips, Nederland) at Benghazi Radiodiagnosis and Radiotherapy Center,

---

Benghazi, Libya. The acquired images were automatically transformed to the Brilliance workstation (Philips) for 2D image analysis using special software.

T2-weighted sequences, in which the ventricle appears white, were administered and numbers of images that show the fullest views of the regions to be examined were selected. The frontal horn of the lateral ventricle was most clearly seen in the axial plane at the level of the head of the caudate nucleus, the temporal horn appeared clearly in the axial plane at the level of the midbrain, while the trigone was seen completely in the axial plane at the level of splenium of the corpus callosum.

## **2. STANDARD PLANIMETRIC MEASURES OF THE LATERAL VENTRICLE**

Anatomic landmarks for the measurements of the lateral ventricle were defined perpendicular to the plane connecting the anterior and posterior commissures. The shape of the lateral ventricle is governed by the neuroanatomical structures surrounding it, such as the caudate nucleus or the hippocampus.

Planimetric measures of the lateral ventricle include processing of two-dimensional axial slices by using the program's suite of editing tools, which enable free hand tracing of the lateral ventricle (2D tools → Graphics → ROI → Free hand). The axial and coronal images were loaded onto the 2D tool and were magnified two times to reduce the manual tracing errors and to determine more accurate boundaries.

---



The margins of the frontal horn, trigone and the temporal horn of both sides were outlined manually on the corresponding axial MR sections for each side at selected standard anatomical levels. The cross sectional areas of the frontal, temporal, and trigone were calculated and expressed in mm<sup>2</sup> units.

The Ventricular index (VI) was calculated at the same axial plane for all subjects. The ventricular/hemispheric index (**V/H**) was calculated at coronal plane for all subjects.

The following parameters were automatically obtained from the free hand tracing of the region of interest:

1. Cross sectional area of the right frontal horn (**CSA Rt FH**) at level of head of the caudate nucleus (**Fig. 11**).
  2. Cross sectional area of the left frontal horn (**CSA Lt FH**) at level of head of the caudate nucleus (**Fig. 11**).
  3. Cross sectional area of the right trigone (**CSA Rt Tr**) at level of the splenium of corpus callosum (**Figs. 11, 12**).
  4. Cross sectional area of the left trigone (**CSA Lt Tr**) at level of the splenium of corpus callosum (**Figs. 11, 12**).
  5. Cross sectional area of the right temporal horn (**CSA Rt TH**) at level of midbrain (**Fig. 13**).
  6. Cross sectional area of the left temporal horn (**CSA Lt TH**) at level of midbrain (**Fig. 13**).
  7. The ventricular hemispheric index (**V/H index**): is the ratio between the distances from the midline to the most lateral point of the lateral
-

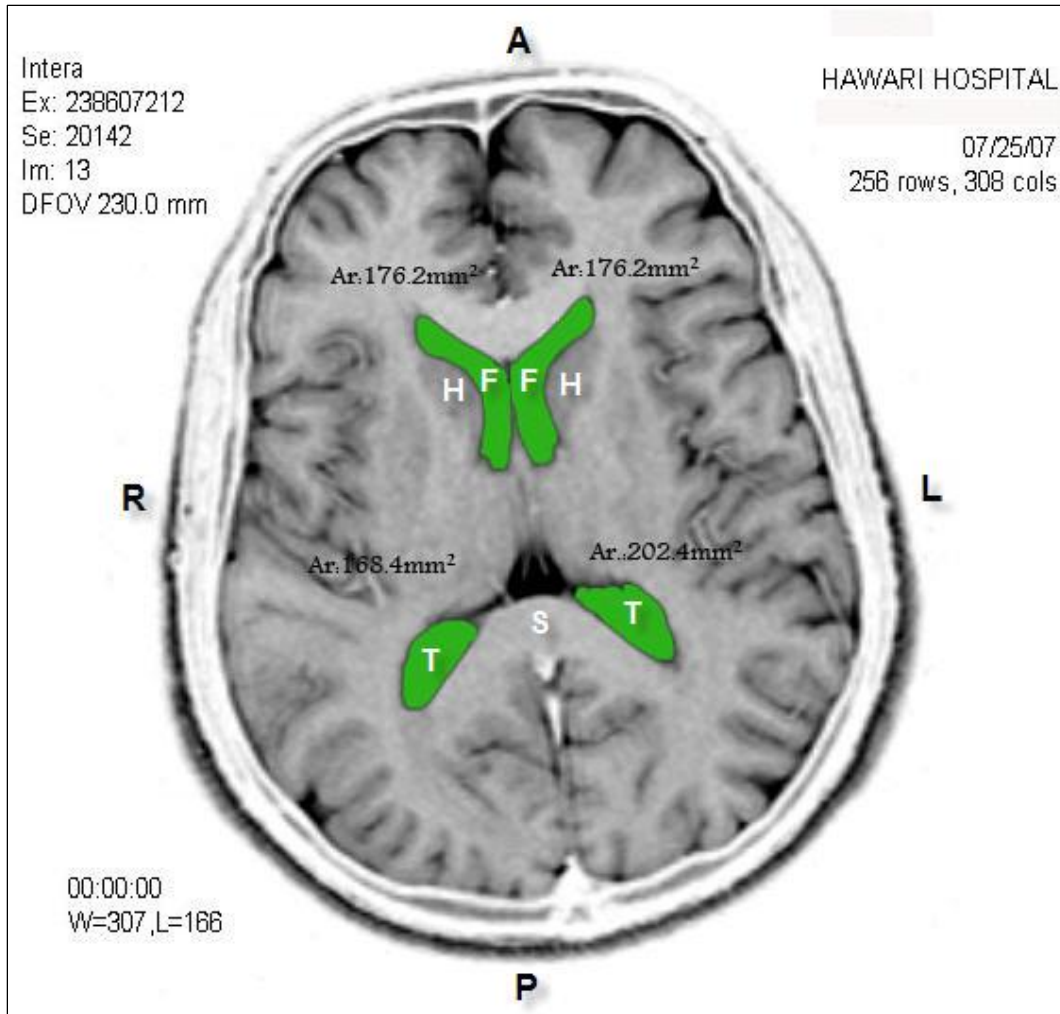
ventricle to the corresponding ipsilateral hemispheric width in the coronal plane at the level of the foramen of Monro (**Figs. 14, 15**).

8. The ventricular index (**VI; Evans' index**): is the ratio between the distance between anterior tips of the frontal horns and the bi-frontal diameter (from inner table of skull) at the same level (**Fig. 16**).

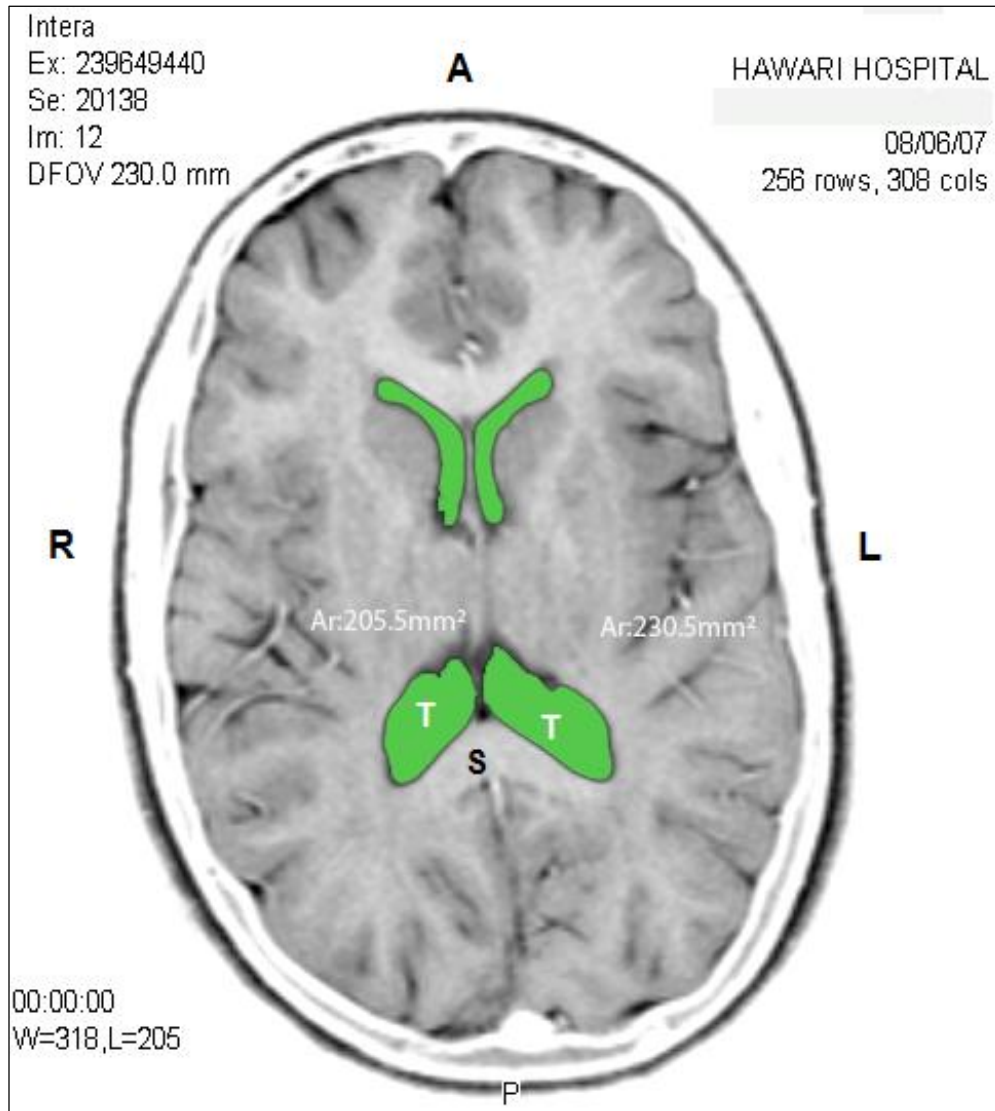
### **C. STATISTICAL ANALYSIS**

Data, expressed as means  $\pm$  SEM, were analyzed by SPSS/PC Student t-test software program. Probability less than 0.05 is considered significant.

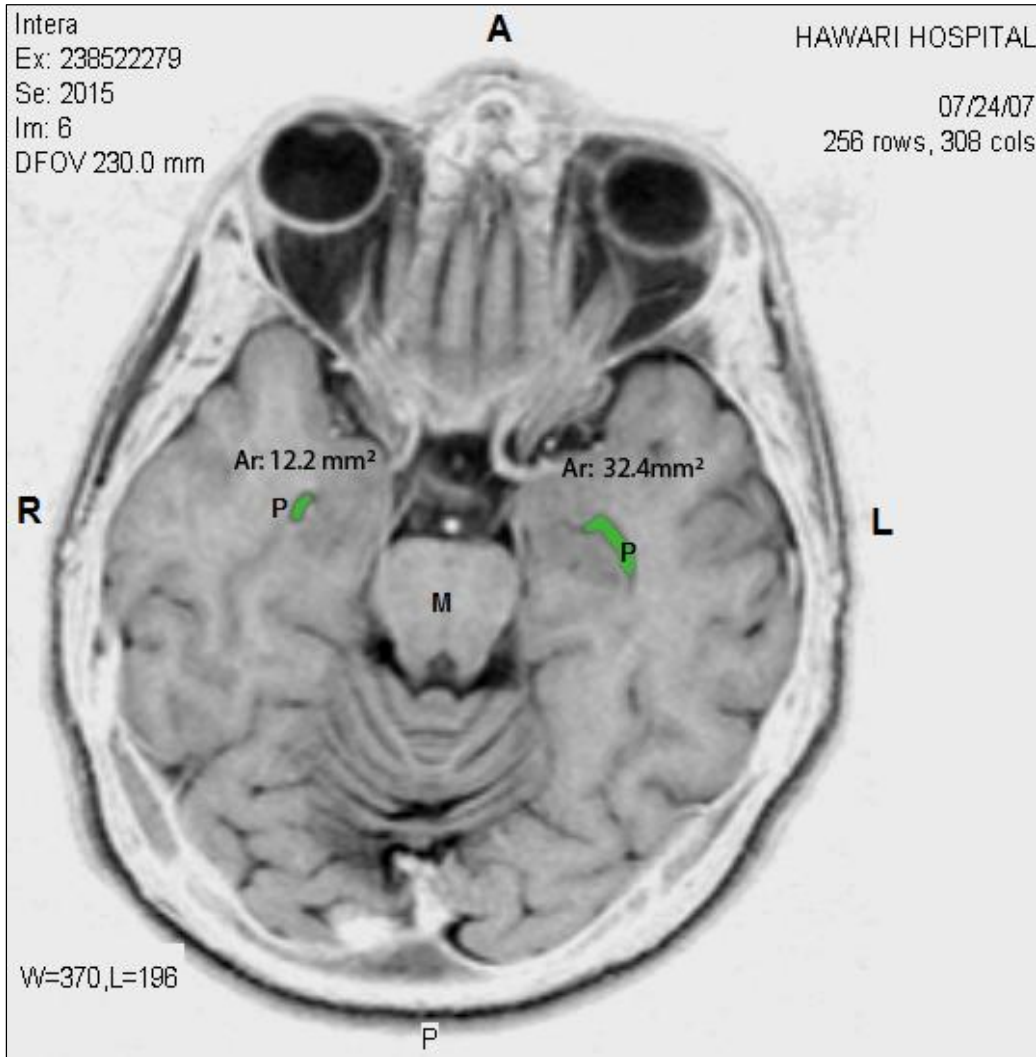
---



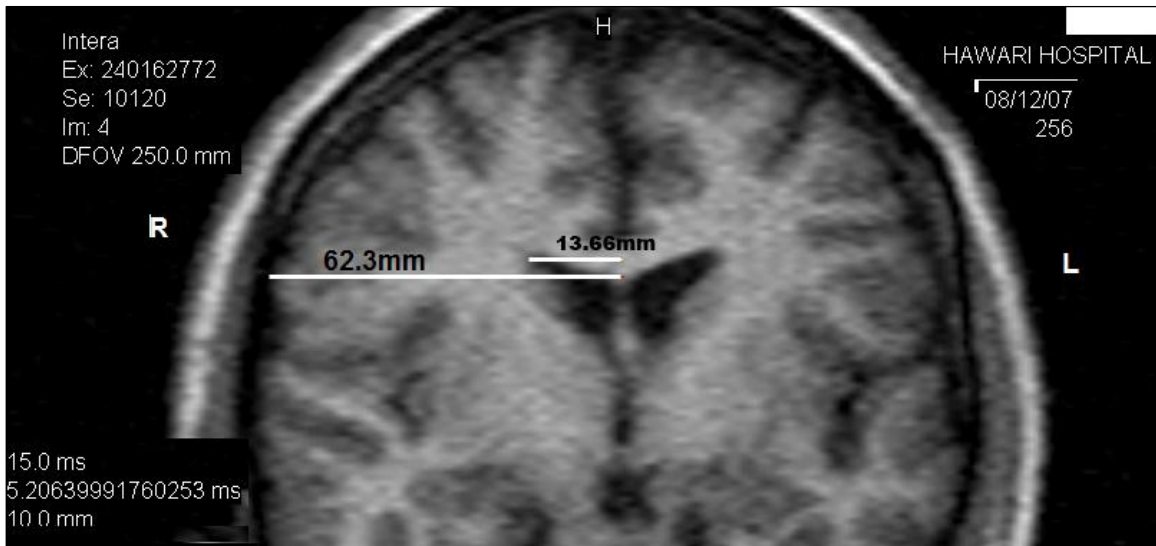
**Fig. 11.** T2 MR Image of axial plane of the brain at the level of the head of the caudate nucleus (H) and the splenium of the corpus callosum (S) of a male subject showing the values of the cross sectional area of the right and left frontal horn (F) and the trigone (T).



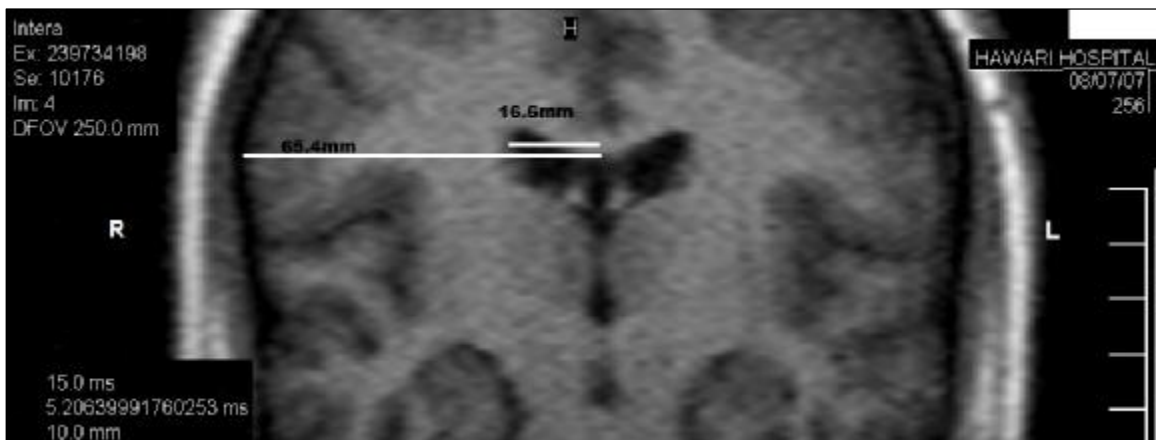
**Fig. 12.** T2 MR Image of axial plane of the brain at the level of the splenium of the corpus callosum (S) of a female subject showing the values of the cross sectional area of the right and left trigone (T).



**Fig. 13.** T2 MR Image of axial plane of the brain at the level of the midbrain (M) of a male subject showing the values of the cross sectional area of the right and left temporal horn (P).



**Fig. 14.** T2 MR Image of coronal plane of the brain at the level of the foramen of Monro of a male subject showing the calculation of the right V/H index



**Fig. 15.** T2 MR Image of coronal plane of the brain at the level of the foramen of Monro of a male subject showing the calculation of the right V/H index

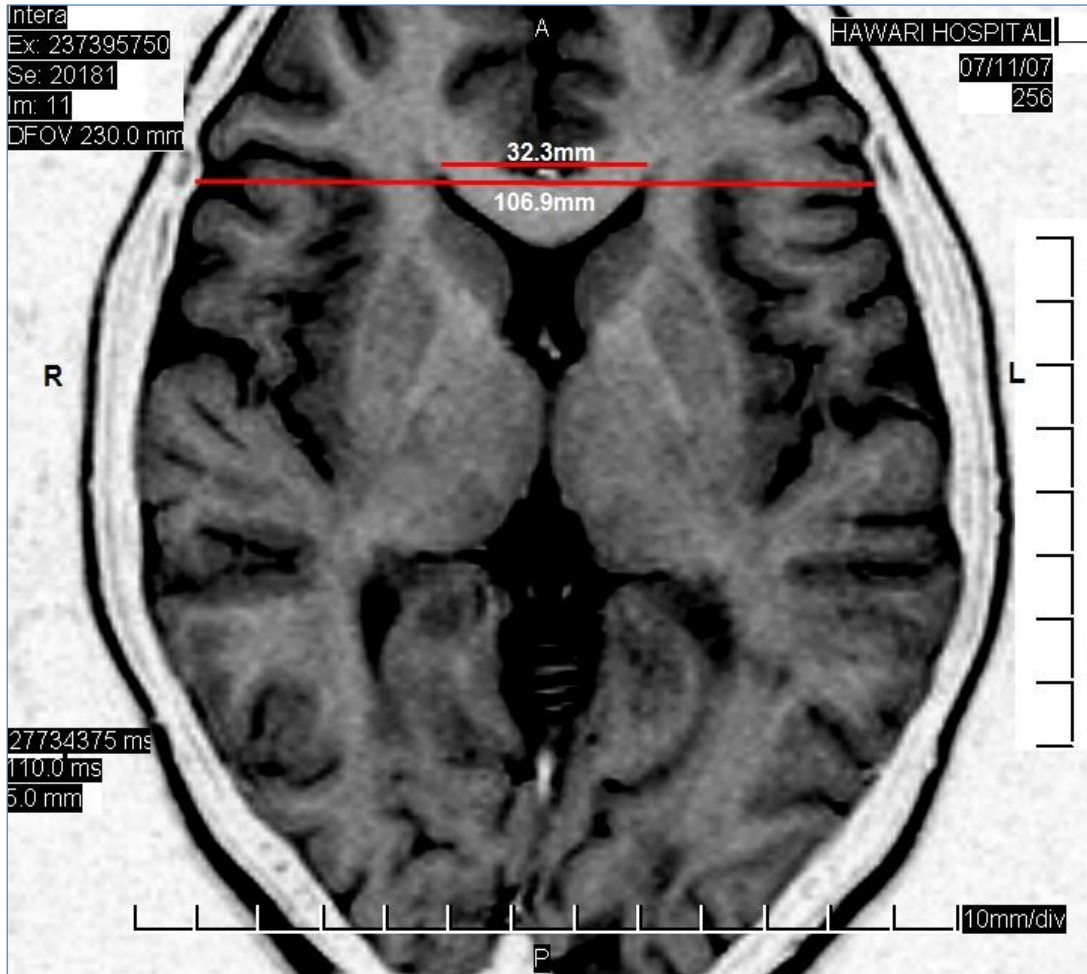

Fig. 16. T2 MR Image of axial plane of the brain at the level of the head of caudate nucleus of a female subject showing the calculation of the Evans' index.

# RESULTS

## **A. MORPHOMETRIC ANALYSIS OF THE LATERAL VENTRICLE IN BOTH SEXES**

Morphometric statistics and analysis of the left and right lateral ventricles of both male and female subjects are shown in **Table 1** for the values of the different parameters in the males, **Table 2** for the values of the different parameters in the females, **Table 3** for the values of the different parameters in all subjects, **Tables 4, 5, 6, 7, 8 & 9** for the cross sectional area of the frontal horn, **Tables 10,11,12,13,14 &15** for the cross sectional area of the trigone, **Tables 16, 17, 18, 19, 20 & 21** for the cross sectional area of the temporal horn, **Tables 22, 23, 24, 25, 26 & 27** for the ventricular/hemispheric (V/H) index and **Tables 28, 29 & 30** for the ventricular index (VI; Evans' Index).

The data (**Charts 1, 2, 3**) revealed that the values of the left lateral ventricle are significantly higher than those of the right lateral ventricle with the exception of the cross sectional area of the Trigone in the female which showed no significant difference between the two sides. The ventricular index (VI) appeared within the normal standard range (0.24 - 0.31). The ventricular index was measured as the ratio between the distance between anterior tips of the frontal horns and the bi-frontal diameter of the brain (from inner table of skull) at the same level.

---



## RESULTS

---

**Table 1: Different parameters of the lateral ventricle of the males**

<b>MALE SUBJECTS</b>	No	Minimum	Maximum	Mean	SD
AGE	80	20	60	40.15 year	13.982
LT Frontal Horn CSA	79	59.5	187.2	149.84 mm <sup>2</sup> *	33.4333
RT Frontal Horn CSA	79	49.6	191.0	140.44 mm <sup>2</sup>	36.3778
LT Trigone CSA	79	120.3	246.0	193.76 mm <sup>2</sup> *	38.7696
RT Trigone CSA	79	130.6	246.2	183.25 mm <sup>2</sup>	32.7894
LT Temporal Horn CSA	78	10.00	59.8	26.16 mm <sup>2</sup> *	9.5976
RT Temporal Horn CSA	78	7.40	42.0	23.87 mm <sup>2</sup>	9.2407
LT V/H Index	79	0.224	0.36	0.271*	2.60126
RT V/H Index	79	0.192	0.346	0.265	2.7653
VI INDEX	79	0.254	0.356	0.2919**	1.8669

\* Highly significant

**CSA:** cross sectional area

\*\* Within the normal standard range

**Table 2: Different parameters of the lateral ventricle of the females**

<b>FEMALE SUBJECTS</b>	No	Minimum	Maximum	Mean	SD
AGE	80	20.00	60.00	39.575 year	12.306
LT Frontal Horn CSA	78	57.80	242.40	130.338 mm <sup>2</sup> *	36.6169
RT Frontal Horn CSA	78	55.50	187.00	122.539 mm <sup>2</sup>	36.44
LT Trigone CSA	79	114.9	249.1	168.866 mm <sup>2</sup>	37.279
RT Trigone CSA	79	130.40	250.70	169.192 mm <sup>2</sup>	35.929
LT Temporal Horn CSA	78	9.9	40.60	20.517 mm <sup>2</sup> *	9.1937
RT Temporal Horn CSA	77	9.7	41.00	17.967 mm <sup>2</sup>	8.326
LT V/H Index	80	0.181	0.308	0.2582*	2.939
RT V/H Index	80	0.031	0.291	0.2441	3.5298
VI INDEX	80	0.226	0.310	0.2787**	1.672

\* Highly significant

**CSA:** cross sectional area

\*\* Within the normal standard range

---

## RESULTS

---

**Table 3: Mean values of the different parameters of the lateral ventricle of all subjects**

<b>ALL SUBJECTS</b>	No	Minimum	Maximum	Mean	SD
AGE	160	20	60	39.86 year	
LT Frontal Horn CSA	157	57.80	242.40	140.152 mm <sup>2</sup> *	36.2822
RT Frontal Horn CSA	157	49,60	191.00	131.549 mm <sup>2</sup>	37.387
LT Trigone CSA	158	114,9	249.10	181.315 mm <sup>2</sup> *	39.9144
RT Trigone CSA	158	130,4	250.7	176.219 mm <sup>2</sup>	35.0027
LT Temporal Horn CSA	156	9,90	59.80	23.330 mm <sup>2</sup> *	9.7859
RT Temporal Horn CSA	155	7.40	42.00	20.936 mm <sup>2</sup>	9.2555
LT V/H Index	159	0,181	0.3600	0.2647*	2.8438
RT V/H Index	159	0.0310	0.3460	0.2547	3.3386
VI INDEX	159	0.226	0.376	0.2948**	1.871

\* Highly significant

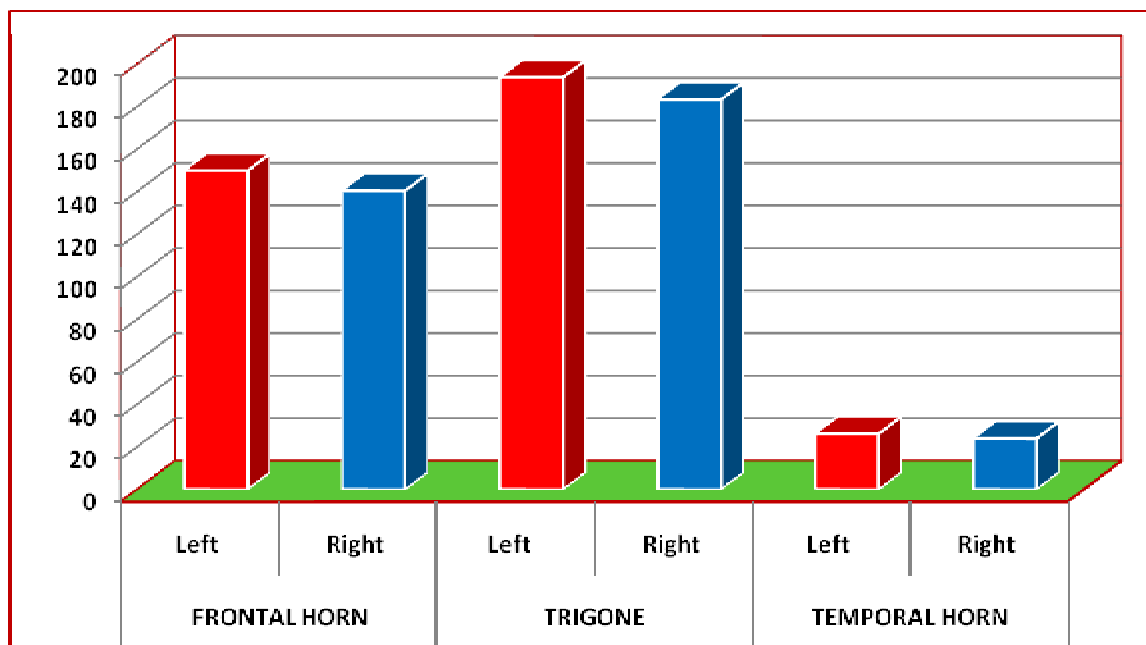
**CSA:** cross sectional area

\*\* Within the normal standard range

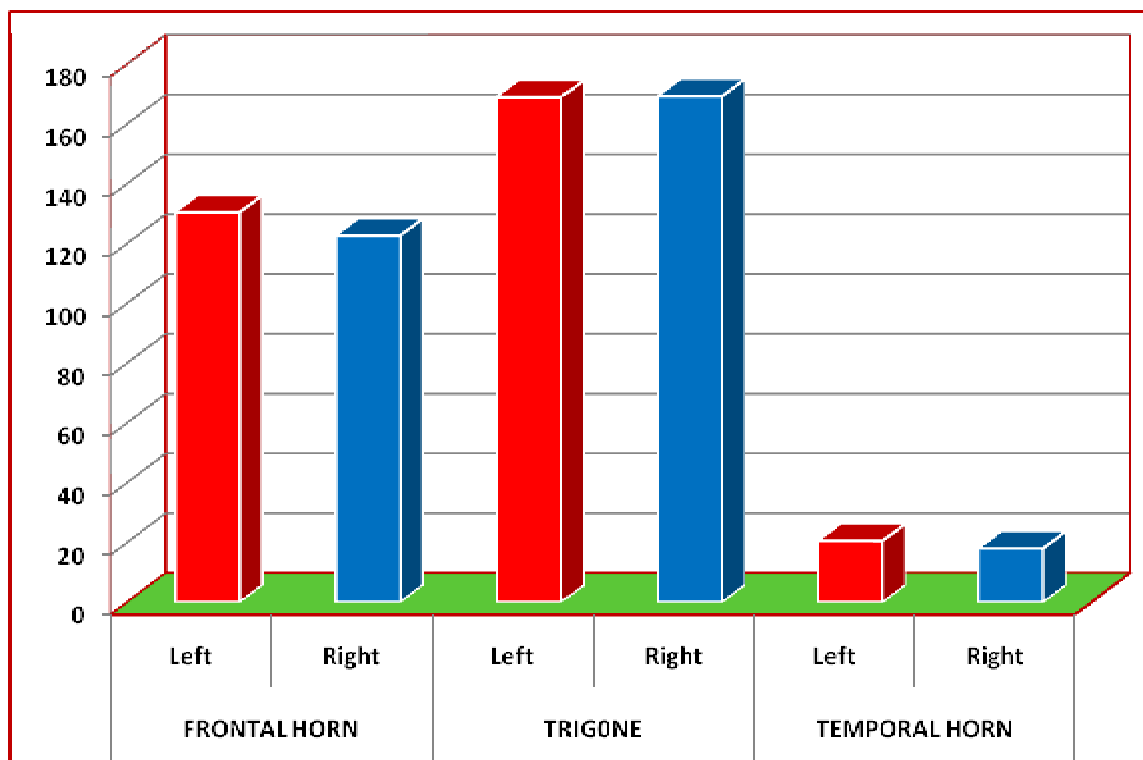
---

**RESULTS**

---



**CHART 1: COMPARISON BETWEEN THE CROSS SECTIONAL AREA OF THE LEFT AND RIGHT LATERAL VENTRICLES OF THE MALES**

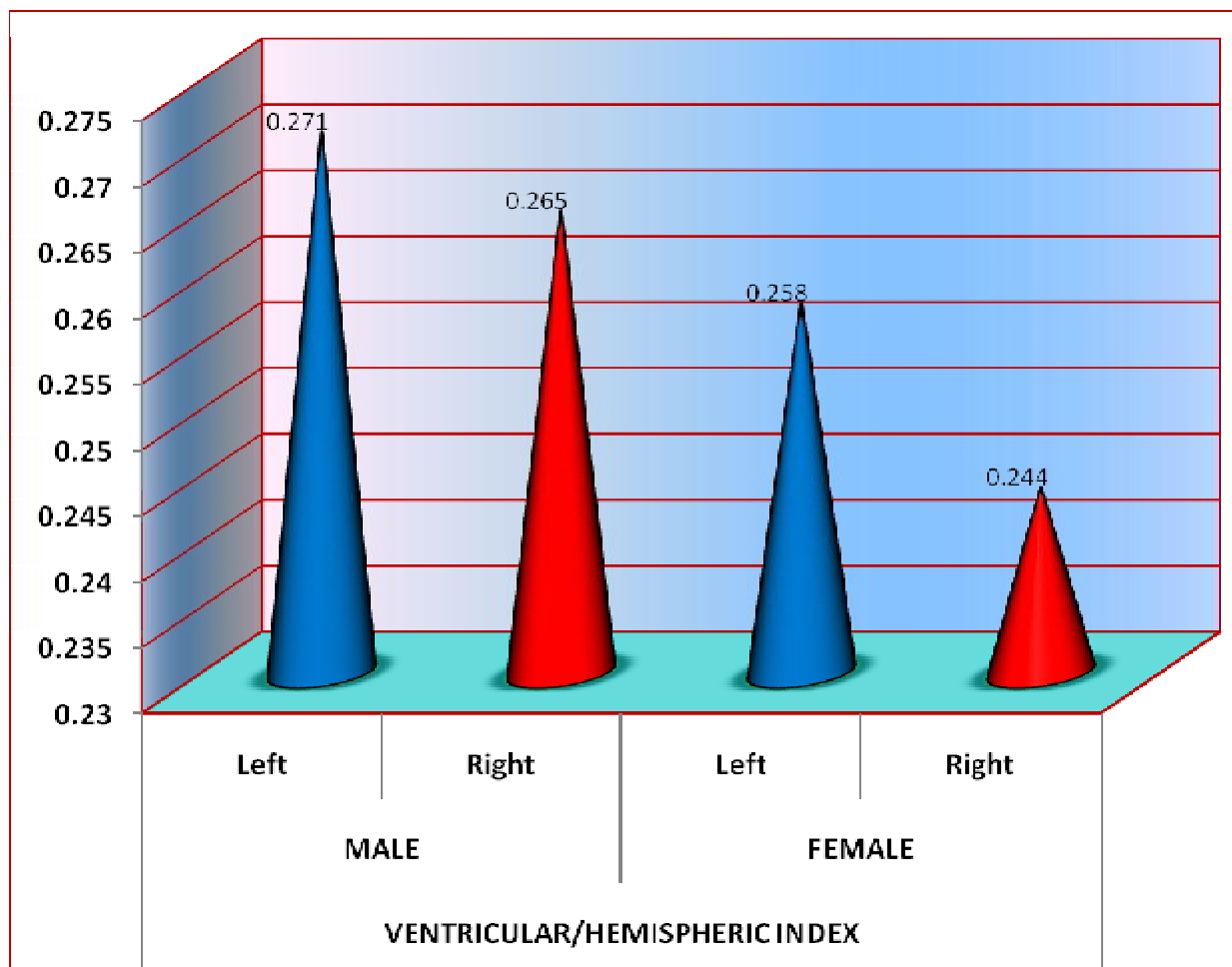


**CHART 2: COMPARISON BETWEEN THE CROSS SECTIONAL AREA OF THE LEFT AND RIGHT LATERAL VENTRICLES OF THE FEMALES**

---

**RESULTS**

---



**CHART 3: COMPARISON BETWEEN THE VENTRICULAR/HEMISPHERIC INDEX OF THE LEFT AND RIGHT LATERAL VENTRICLES OF THE MALES & FEMALES**

---

## RESULTS

---

### 1. FRONTAL HORN

Examination of the frontal horn of 79 male subjects (**Tables 4, 5**) (**Figs. 17-21**) revealed a highly significant increase ( $p > 0.000$ ) in the cross sectional area of the left frontal horn compared to that of the right frontal horn. The mean cross sectional area of the left frontal horn was  $149.84 \pm 3.76 \text{ mm}^2$  (mean  $\pm$  SEM), while the mean cross sectional area of the right frontal horn was  $140.44 \pm 4.09 \text{ mm}^2$  (mean  $\pm$  SEM).

**Table 4: Paired sample statistics of the cross sectional area of the left and right frontal horn of the male lateral ventricle**

MALE SUBJECTS	No	Mean cross sectional area $\text{mm}^2$	SD	SEM	Significance
LT Frontal Horn:	79	149.8418	33.4333	3.7615	0.000
RT Frontal Horn:	79	140.4443	36.3778	4.0928	

**Table 5: Paired sample analysis of the values of the cross sectional area of the left and right frontal horn of the male lateral ventricle**

	Paired Differences					t	df	Sig. 2-tailed
	Mean	SD	SEM	95% confidence interval of the difference				
				Lower	Upper			
LT Frontal Horn RT Frontal Horn	9.3975	28.09	3.16	3.11	15.69	2.974	78	0.004

---

## RESULTS

---

Examination of the frontal horn of 78 female subjects (**Tables 6, 7**) (**Figs. 22-26**) revealed a highly significant increase ( $p > 0.000$ ) in the cross sectional area of the left frontal horn compared to that of the right frontal horn. The mean cross sectional area of the left frontal horn was  $130.33 \pm 4.14 \text{ mm}^2$  (mean  $\pm$  SEM), while the mean cross sectional area of the right frontal horn was  $122.53 \pm 4.12 \text{ mm}^2$  (mean  $\pm$  SEM).

**Table 6: Paired sample statistics of the cross sectional area of the left and right frontal horn of the female lateral ventricle**

FEMALE SUBJECTS	No	Mean cross sectional area $\text{mm}^2$	SD	SEM	Significance
LT Frontal Horn:	78	130.3382	36.6169	4.1460	0.000
RT Frontal Horn:	78	122.5397	36.4410	4.1261	

**Table 7: Paired sample analysis of the values of the cross sectional area of the left and right frontal horn of the female lateral ventricle**

	Paired Differences					t	df	Sig. 2-tailed
	Mean	SD	SEM	95% confidence interval of the difference				
				Lower	Upper			
LT Frontal Horn RT Frontal Horn	7.7985	25.23	2.86	2.11	13.49	2.729	77	0.008

---

## RESULTS

---

Comparing the values of the right and left frontal horn of all subjects (157; 79 male & 78 female) (**Tables 8, 9**) revealed a highly significant increase ( $p > 0.000$ ) in the cross sectional area of the left frontal horn compared to that of the right frontal horn. The mean cross sectional area of the left frontal horn was  $140.15 \pm 2.89 \text{ mm}^2$  (mean  $\pm$  SEM), while the mean cross sectional area of the right frontal horn was  $131.55 \pm 2.98 \text{ mm}^2$  (mean  $\pm$  SEM).

**Table 8: Paired sample statistics of the cross sectional area of the left and right frontal horn of the lateral ventricle of all subjects**

ALL SUBJECTS	No	Mean cross sectional area $\text{mm}^2$	SD	SEM	Significance
LT Frontal Horn:	157	140.152	36.2822	2.8956	0.000
RT Frontal Horn:	157	131.549	37.3870	2.9838	

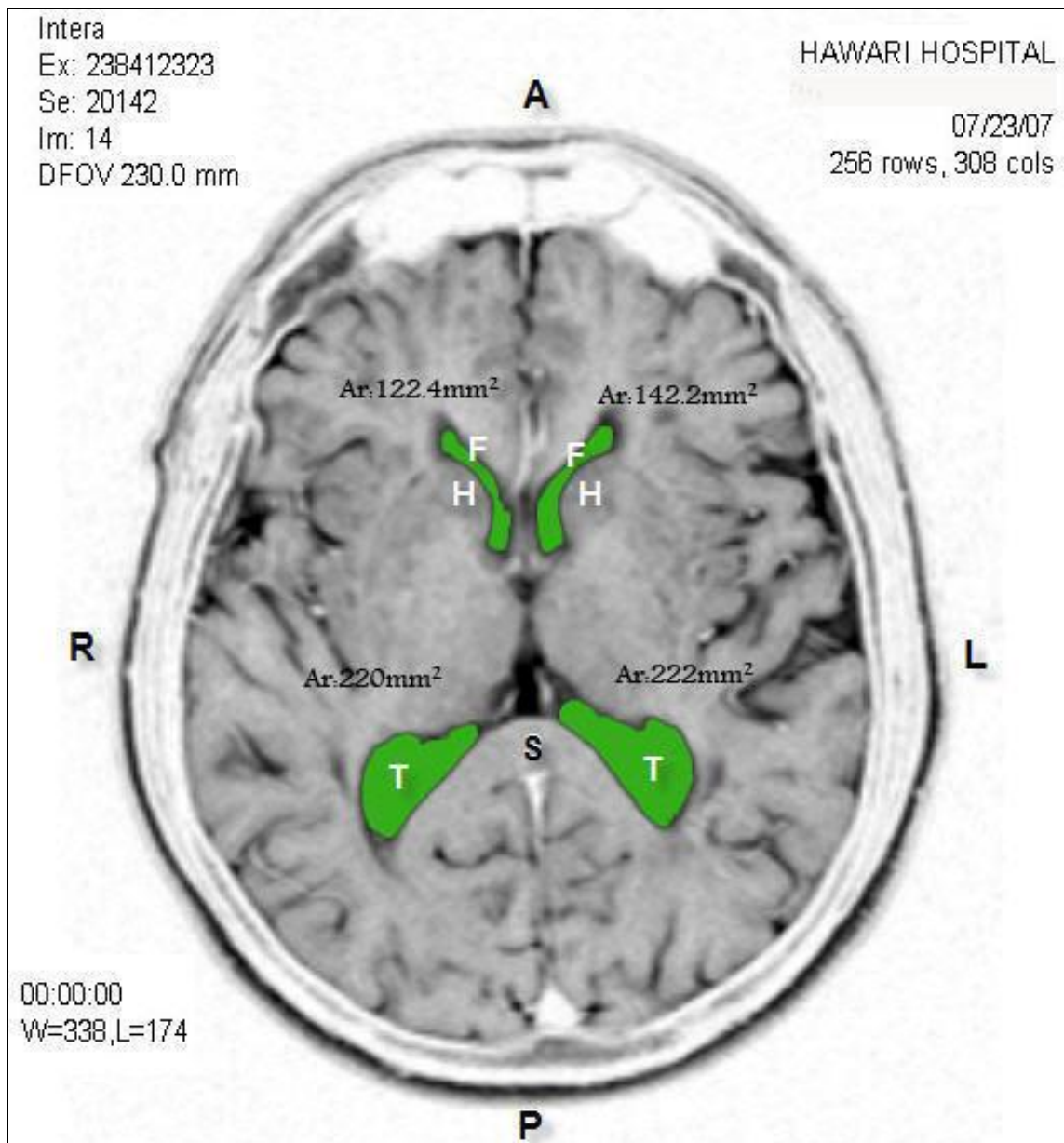
**Table 9: Paired sample analysis of the cross sectional area of the left and right frontal horn of the lateral ventricle of all subjects**

	Paired Differences					t	df	Sig. 2-tailed
	Mean	SD	SEM	95% confidence interval of the difference				
				Lower	Upper			
LT Frontal Horn RT Frontal Horn	8.6031	26.64	2.13	4.404	12.802	4.05	156	0.000

---

**RESULTS**

---

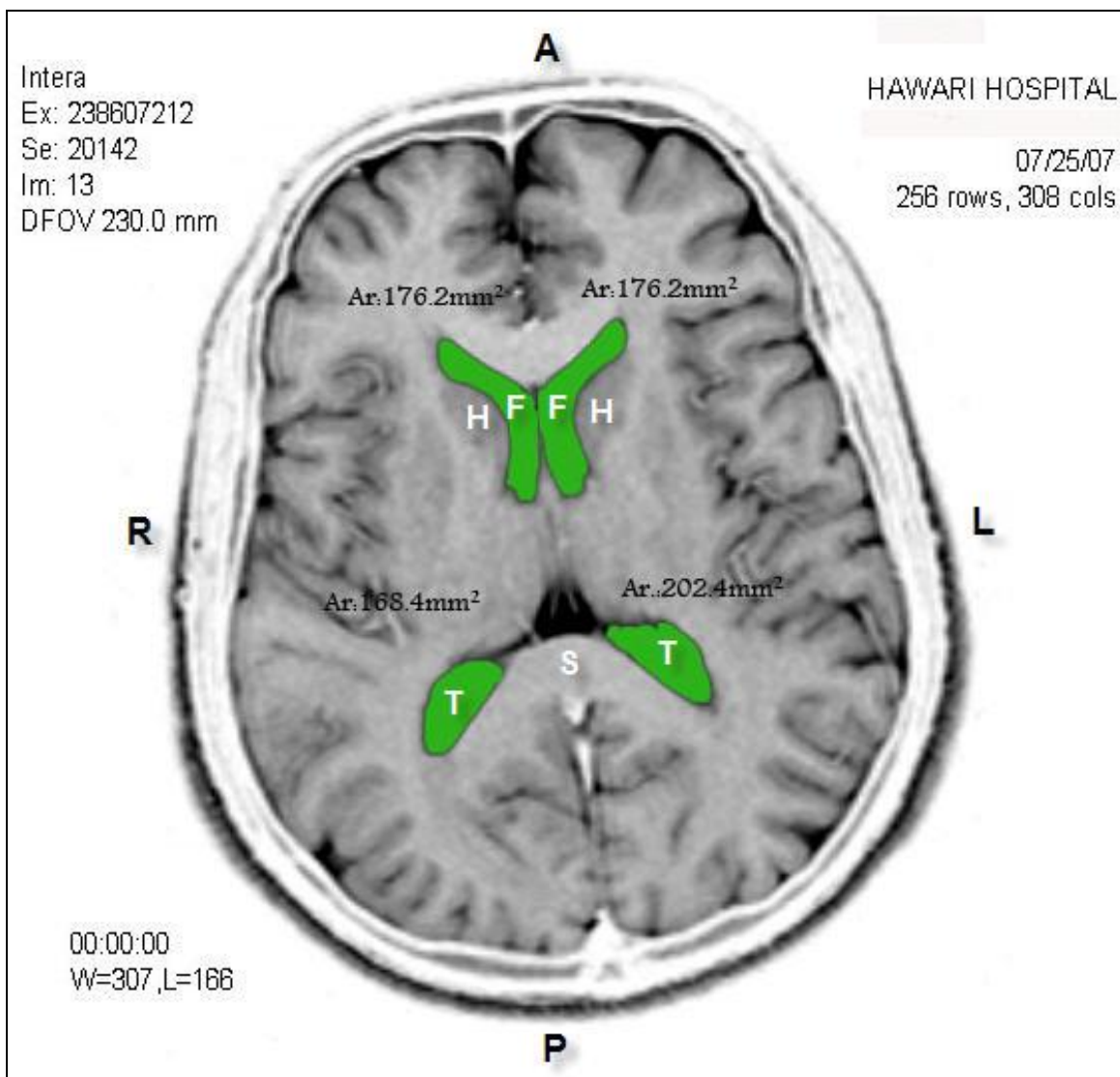


**Fig. 17.** T2 MR Image of axial plane of the brain at the level of the head of the caudate nucleus (H) and the splenium of the corpus callosum (S) of a 22 year old male subject showing the values of the cross sectional area of the right and left frontal horn (F) and the trigone (T).

---

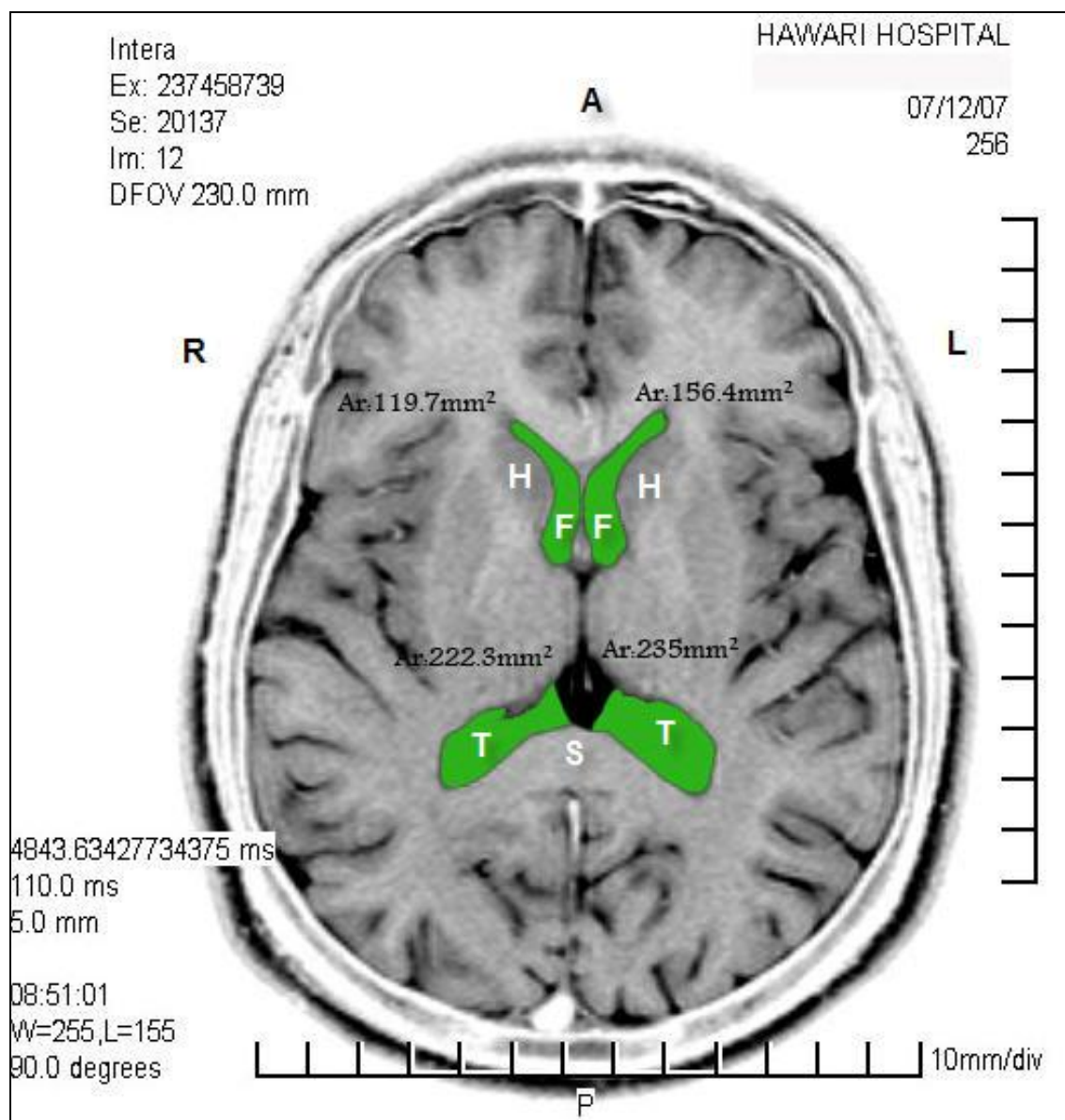


**RESULTS**



**Fig. 18.** T2 MR Image of axial plane of the brain at the level of the head of the caudate nucleus (H) and the splenium of the corpus callosum (S) of a 46 years old male subject showing the values of the cross sectional area of the right and left frontal horn (F) and the trigone (T).

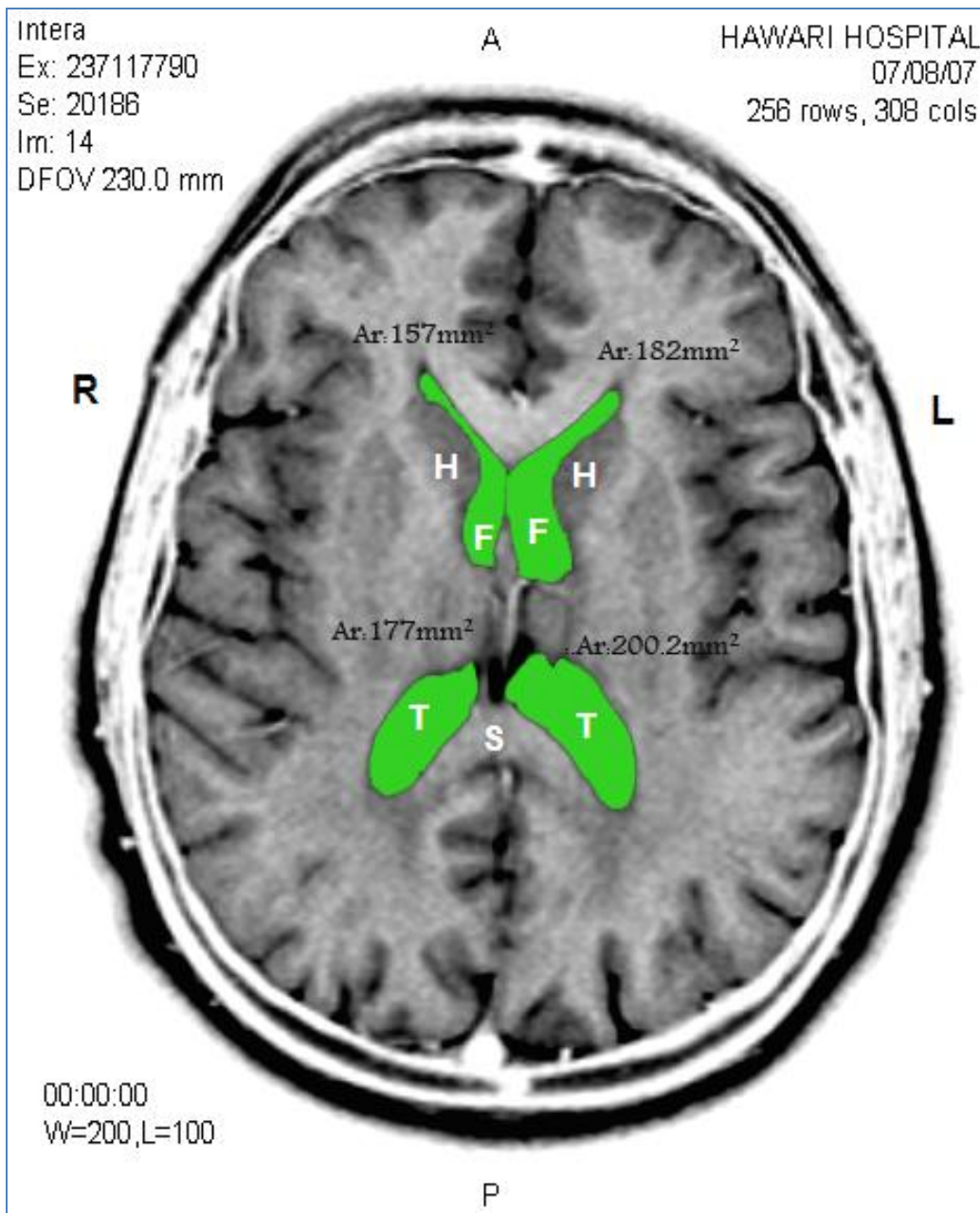
**RESULTS**



**Fig. 19.** T2 MR Image of axial plane of the brain at the level of the head of the caudate nucleus (H) and the splenium of the corpus callosum (S) of a 35 years old male subject showing the values of the cross sectional area of the right and left frontal horn (F) and the trigone (T).

**RESULTS**

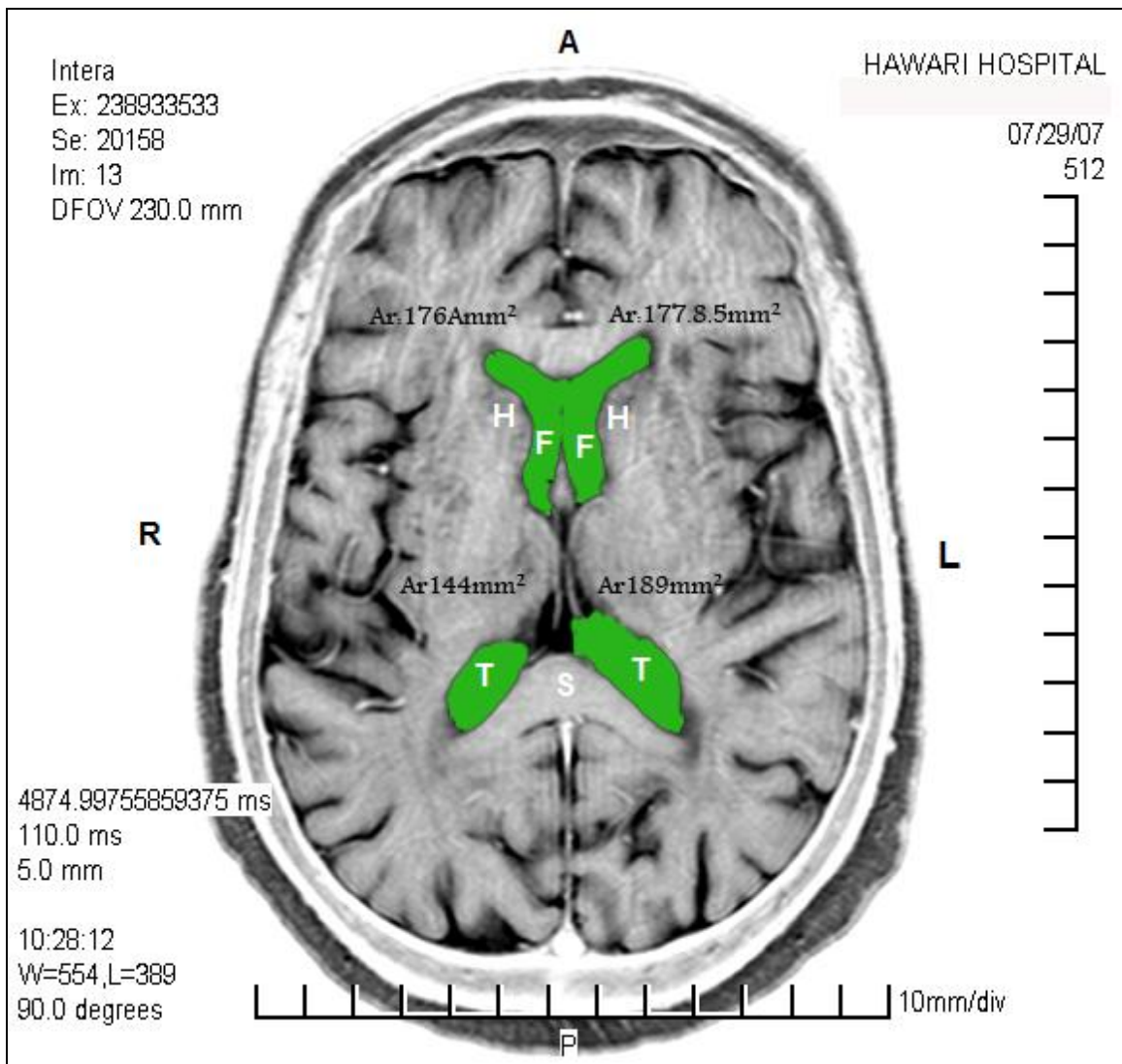
---



**Fig. 20.** T2 MR Image of axial plane of the brain at the level of the head of the caudate nucleus (H) and the splenium of the corpus callosum (S) of a 58 years old male subject showing the values of the cross sectional area of the right and left frontal horn (F) and the trigone (T).

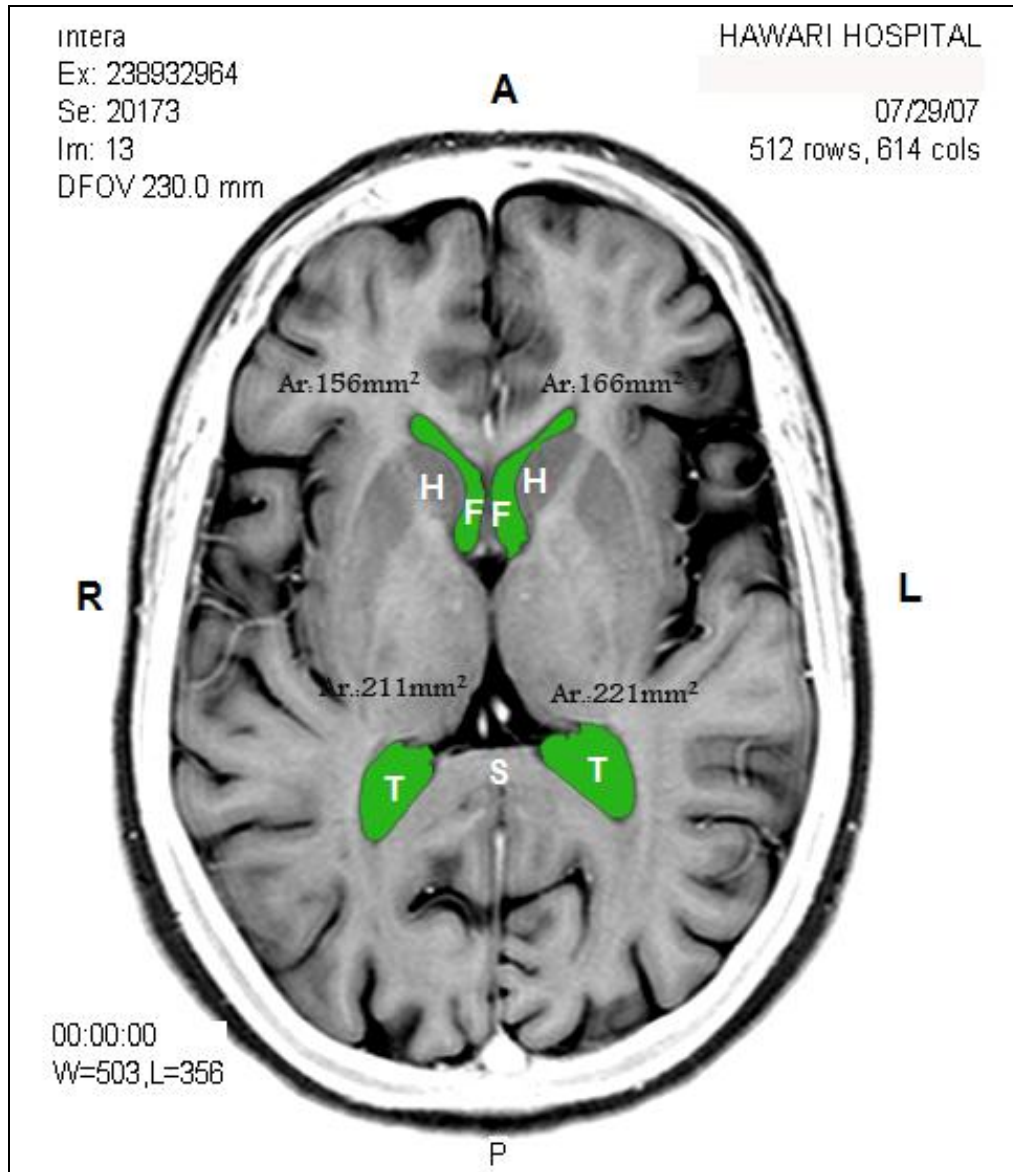
---

**RESULTS**



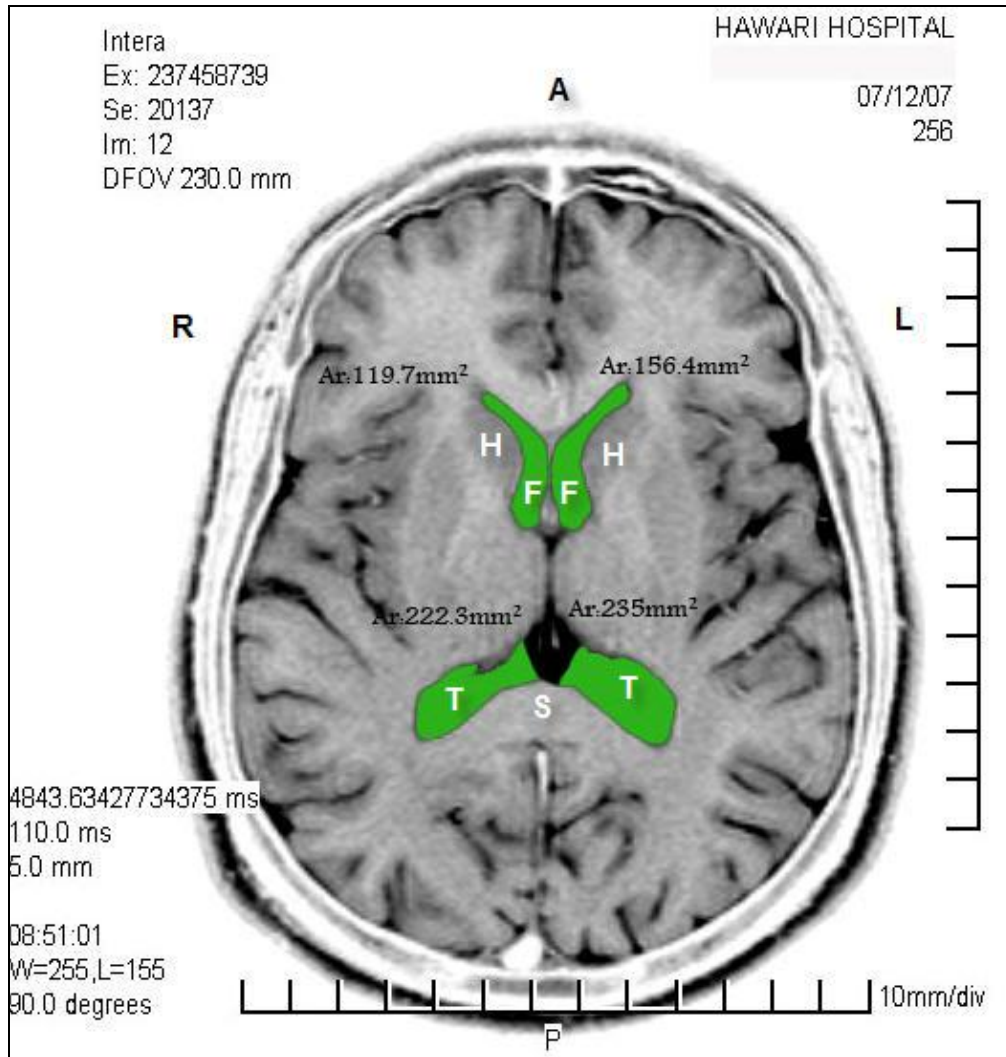
**Fig. 21.** T2 MR Image of axial plane of the brain at the level of the head of the caudate nucleus (H) and the splenium of the corpus callosum (S) of a 39 years old male subject showing the values of the cross sectional area of the right and left frontal horn (F) and the trigone (T).

**RESULTS**



**Fig. 22.** T2 MR Image of axial plane of the brain at the level of the head of the caudate nucleus (H) and the splenium of the corpus callosum (S) of a 52 years old female subject showing the values of the cross sectional area of the right and left frontal horn (F) and the trigone (T).

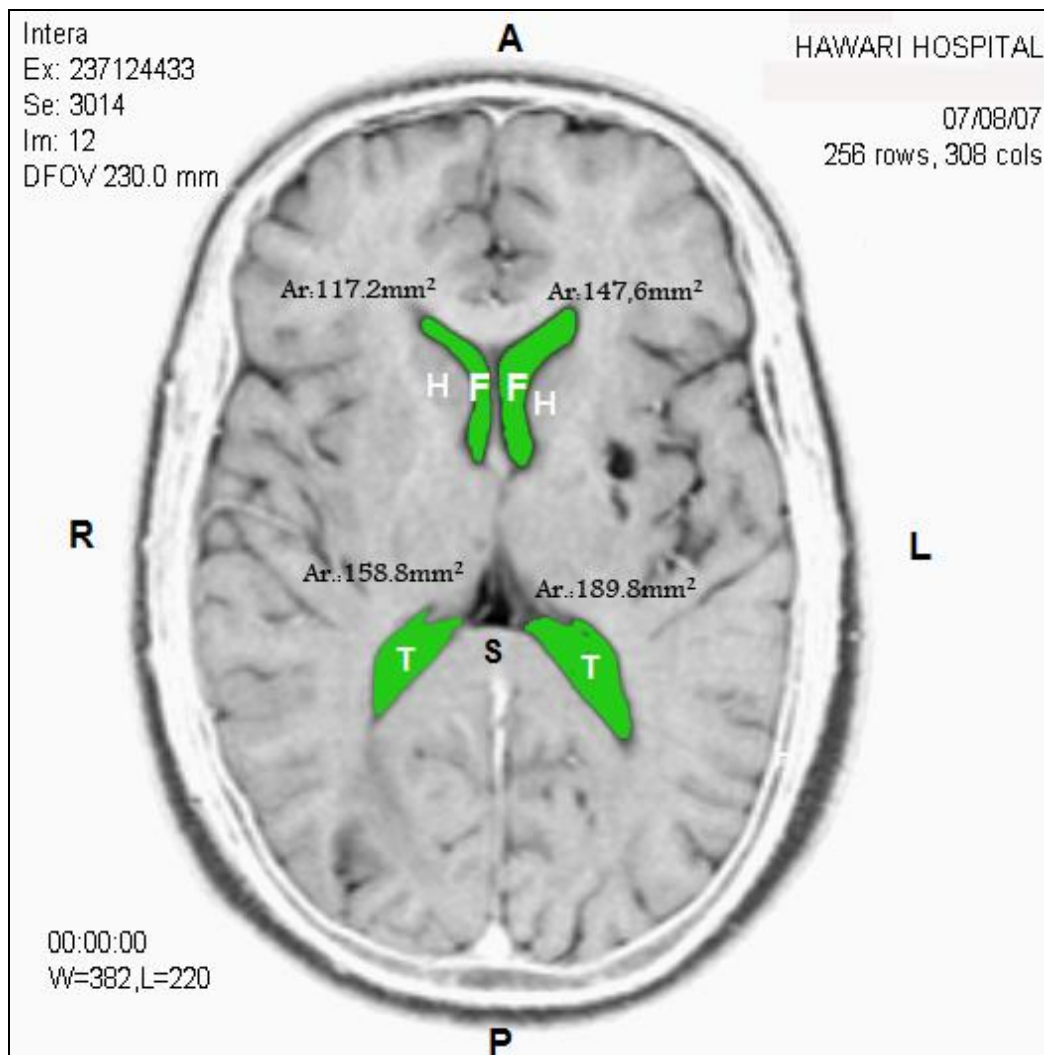
**RESULTS**



**Fig. 23.** T2 MR Image of axial plane of the brain at the level of the head of the caudate nucleus (H) and the splenium of the corpus callosum (S) of a 44 years old female subject showing the values of the cross sectional area of the right and left frontal horn (F) and the trigone (T).

**RESULTS**

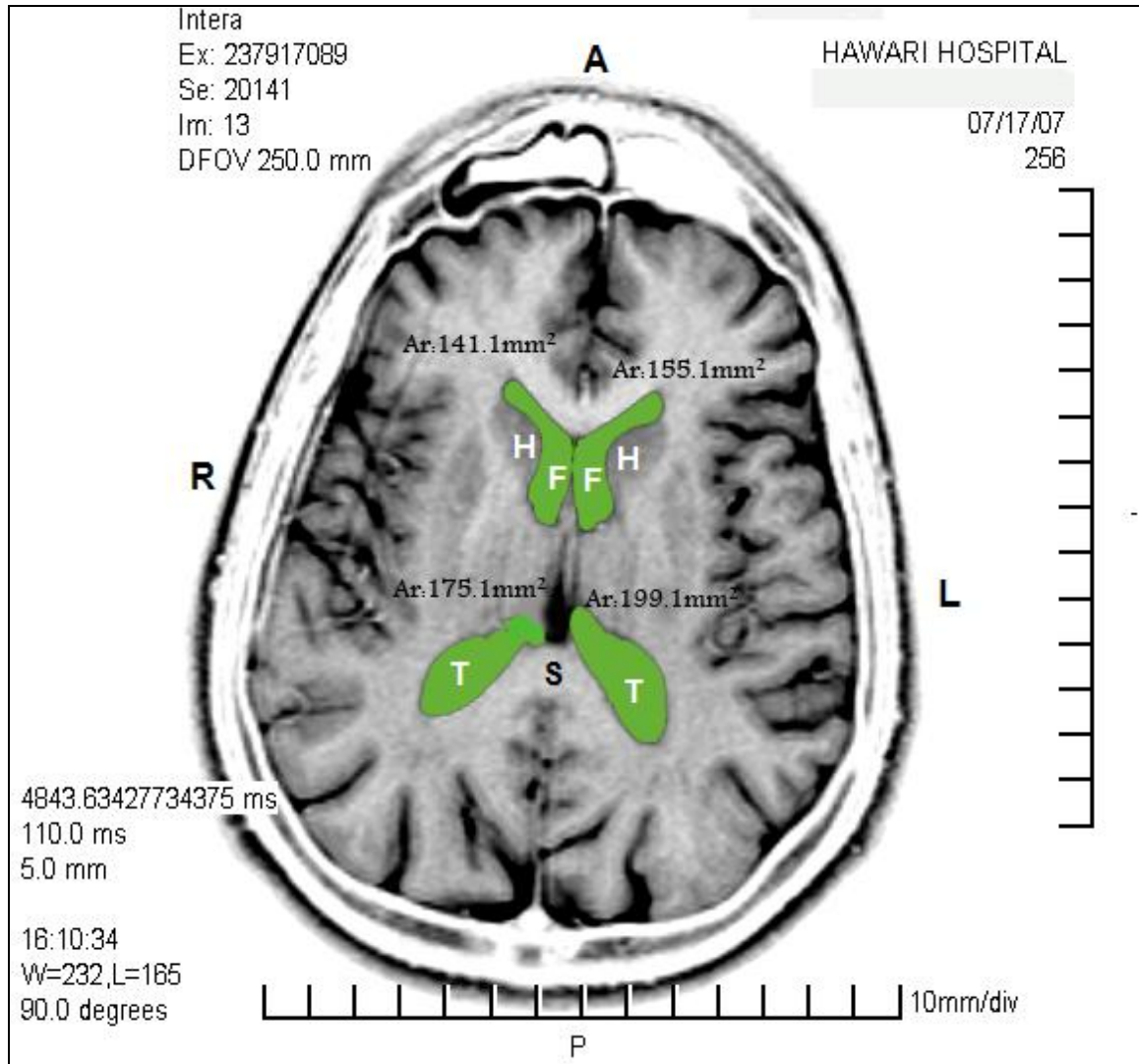
---



**Fig. 24.** T2 MR Image of axial plane of the brain at the level of the head of the caudate nucleus (H) and the splenium of the corpus callosum (S) of a 30 years old female subject showing the values of the cross sectional area of the right and left frontal horn (F) and the trigone (T).

---

**RESULTS**

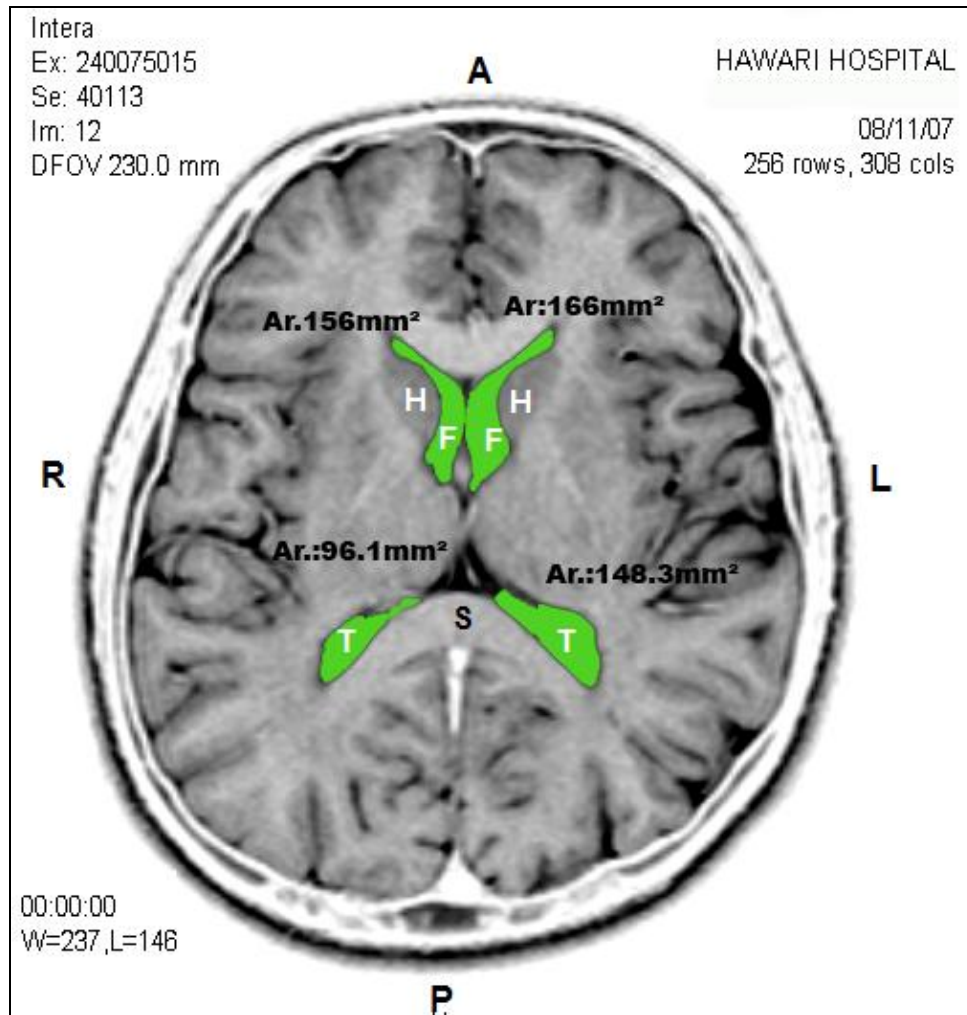


**Fig. 25.** T2 MR Image of axial plane of the brain at the level of the head of the caudate nucleus (H) and the splenium of the corpus callosum (S) of a 29 years old female subject showing the values of the cross sectional area of the right and left frontal horn (F) and the trigone (T).



**RESULTS**

---



**Fig.26.** T2 MR Image of axial plane of the brain at the level of the head of the caudate nucleus (H) and the splenium of the corpus callosum (S) of a 21 years old female subject showing the values of the cross sectional area of the right and left frontal horn (F) and the trigone (T).

---

## **2. TRIGONE**

Examination of the trigone of 79 male subjects (**Tables 10, 11**) (**Figs. 17 - 21**) revealed a highly significant increase ( $p > 0.000$ ) in the cross sectional area of the left trigone compared to that of the right trigone. The mean cross sectional area of the left trigone was  $193.76 \pm 4.36 \text{ mm}^2$  (mean  $\pm$  SEM), while the mean cross sectional area of the right trigone was  $183.25 \pm 3.69 \text{ mm}^2$  (mean  $\pm$  SEM).

**Table 10: Paired sample statistics of the cross sectional area of the left and right Trigone of the male lateral ventricle**

<b>MALE SUBJECTS</b>	<b>No</b>	<b>Mean cross sectional area mm<sup>2</sup></b>	<b>SD</b>	<b>SEM</b>	<b>Significance</b>
<b>LT Trigone:</b>	79	193.7633	38.7696	4.3619	0.000
<b>RT Trigone :</b>	79	183.2456	32.7894	3.6891	

**Table 11: Paired sample analysis of the values of the cross sectional area of the left and right Trigone of the male lateral ventricle**

	Paired Differences					t	df	Sig. 2-tailed
	Mean	SD	SEM	95% confidence interval of the difference				
				Lower	Upper			
<b>LT Trigone RT Trigone</b>	10.518	32.342	3.6387	3.2736	17.7618	2.891	78	0.005

---

## RESULTS

---

Examination of the trigone of 79 female subjects (**Tables 12, 13**) (**Figs. 22 - 28**) revealed no significant differences ( $p > 0.975$ ) in the cross sectional area of the left trigone compared to that of the right trigone. The mean cross sectional area of the left trigone was  $169.1924 \pm 4.04 \text{ mm}^2$  (mean  $\pm$  SEM) compared to  $168.86 \pm 4.04 \text{ mm}^2$  (mean  $\pm$  SEM) for the mean cross sectional area of the right trigone.

**Table 12: Paired sample statistics of the cross sectional area of the left and right Trigone of the female lateral ventricle**

FEMALE SUBJECTS	No	Mean cross sectional area $\text{mm}^2$	SD	SEM	Significance
LT Trigone:	79	168.8667	37.2796	4.1943	0.975
RT Trigone:	79	169.1924	35.9296	4.0424	

**Table 13: Paired sample analysis of the values of the cross sectional area of the left and right Trigone of the female lateral ventricle**

	Paired Differences					t	df	Sig. 2-tailed
	Mean	SD	SEM	95% confidence interval of the difference				
				Lower	Upper			
LT Trigone RT Trigone	-0.3257	27.0979	3.0488	-6.395	5.7439	-0.107	78	0.915

---

**RESULTS**

---

Comparing the values of the right and left trigone of all subjects (158; 79 male & 79 female) (**Tables 14, 15**) revealed a highly significant increase ( $p > 0.000$ ) in the cross sectional area of the left trigone compared to that of the right trigone. The mean cross sectional area of the left trigone was  $181.315 \pm 3.175 \text{ mm}^2$  (mean  $\pm$  SEM), while the mean cross sectional area of the right trigone was  $176.219 \pm 2.785 \text{ mm}^2$  (mean  $\pm$  SEM).

**Table 14: Paired sample statistics of the cross sectional area of the left and right Trigone of the lateral ventricle of all subjects**

ALL SUBJECTS	No	Mean cross sectional area $\text{mm}^2$	SD	SEM	Significance
LT Trigone:	158	181.3150	39.9144	3.1754	0.000
RT Trigone:	158	176.2190	35.0027	2.7847	

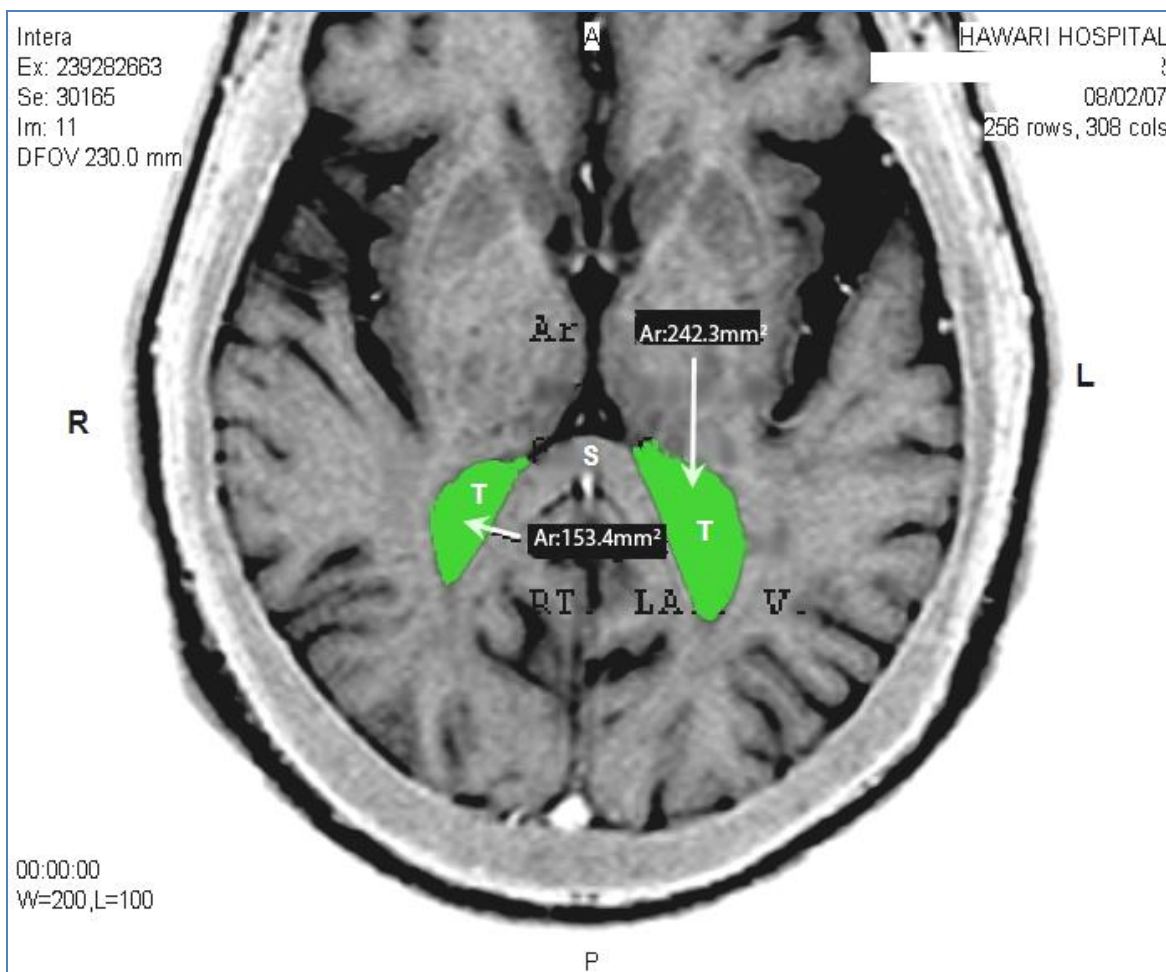
**Table 15: Paired sample analysis of the values of the cross sectional area of the left and right Trigone of the lateral ventricle of all subjects**

	Paired Differences					t	df	Sig. 2-tailed
	Mean	SD	SEM	95% confidence interval of the difference				
				Lower	Upper			
<b>LT Trigone RT Trigone</b>	5.096	30.233	2.405	0.3452	9.8468	2.119	157	0.036

---

**RESULTS**

---

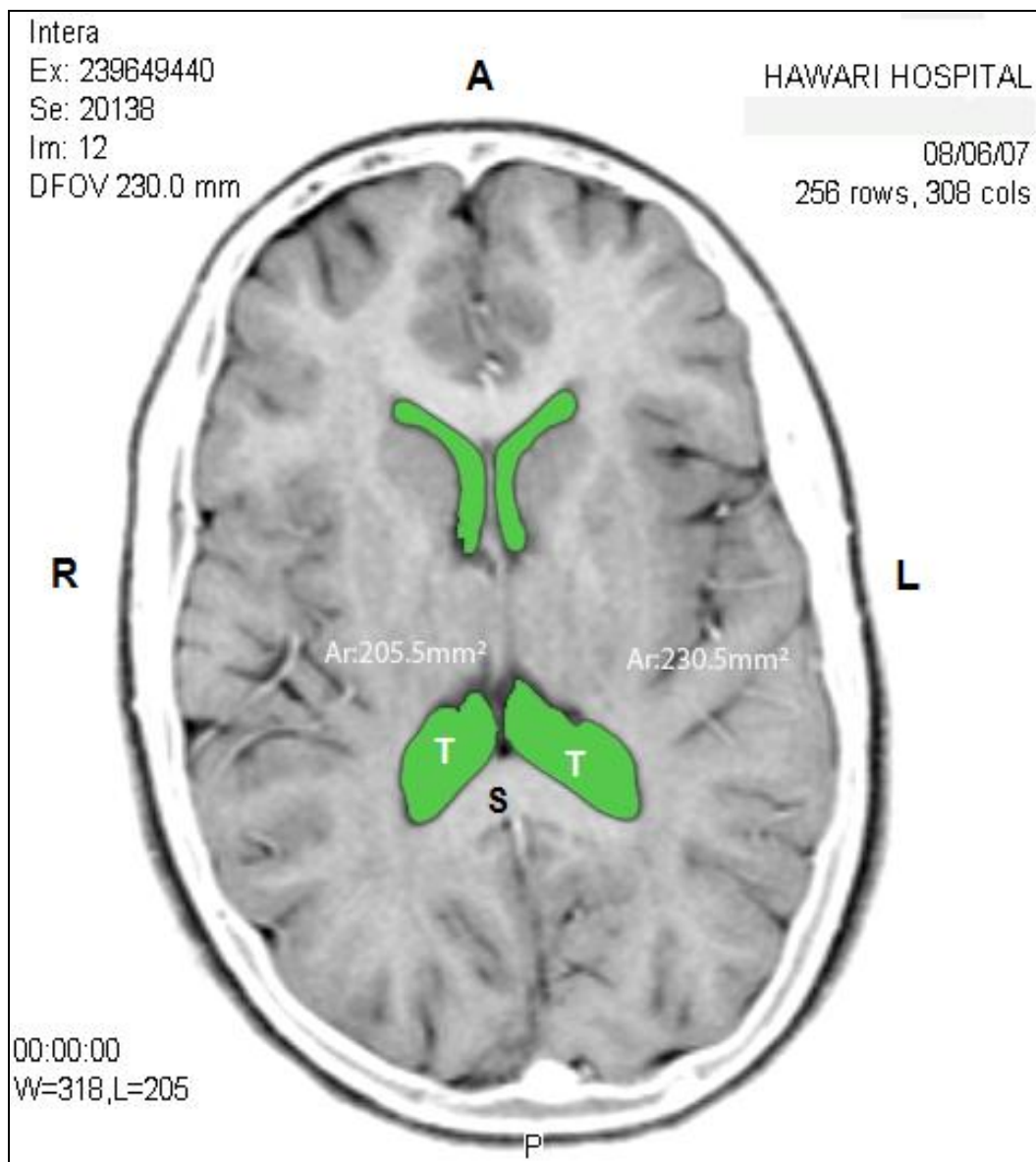


**Fig. 27.** T2 MR Image of axial plane of the brain at the level of the splenium of the corpus callosum (S) of a female subject showing the values of the cross sectional area of the right and left trigone (T).

---

**RESULTS**

---



**Fig. 28.** T2 MR Image of axial plane of the brain at the level of the splenium of the corpus callosum (S) of a female subject showing the values of the cross sectional area of the right and left trigone (T).

---

### **3. TEMPORAL HORN**

Examination of the temporal horn of 78 male subjects (**Tables 16, 17**) (**Figs. 29- 33**) revealed a highly significant increase ( $p > 0.000$ ) in the cross sectional area of the left temporal horn compared to that of the right temporal horn. The mean cross sectional area of the left temporal horn was  $26.16 \pm 1.09 \text{ mm}^2$  (mean  $\pm$  SEM), while the mean cross sectional area of the right temporal horn was  $23.87 \pm 1.04 \text{ mm}^2$  (mean  $\pm$  SEM).

**Table 16: Paired sample statistics of the cross sectional area of the left and right temporal horn of the male lateral ventricle**

<b>MALE SUBJECTS</b>	<b>No</b>	<b>Mean cross sectional area <math>\text{mm}^2</math></b>	<b>SD</b>	<b>SEM</b>	<b>Significance</b>
<b>LT Temporal horn:</b>	78	26.1615	9.5976	1.0867	0.000
<b>RT Temporal horn :</b>	78	23.8667	9.2407	1.0407	

**Table 17: Paired sample analysis of the values of the cross sectional area of the left and right temporal horn of the male lateral ventricle**

	Paired Differences					t	df	Sig. 2-tailed
	Mean	SD	SEM	95% confidence interval of the difference				
				Lower	Upper			
<b>LT Temp. horn RT Temp. horn</b>	2.295	6.992	0.7917	0.7184	3.8713	2.899	77	0.005

---

## RESULTS

---

Examination of the temporal horn of 77 female subjects (**Tables 18, 19**) (**Figs. 34 - 38**) revealed a highly significant increase ( $p > 0.000$ ) in the cross sectional area of the left temporal horn compared to that of the right temporal horn. The mean cross sectional area of the left temporal horn was  $20.36 \pm 1.04 \text{ mm}^2$  (mean  $\pm$  SEM), while the mean cross sectional area of the right temporal horn was  $17.97 \pm 0.95 \text{ mm}^2$  (mean  $\pm$  SEM).

**Table 18: Paired sample statistics of the cross sectional area of the left and right temporal horn of the female lateral ventricle**

FEMALE SUBJECTS	No	Mean cross sectional area $\text{mm}^2$	SD	SEM	Significance
LT Temporal horn	77	20.3610	9.1482	1.0425	0.000
RT Temporal horn	77	17.9675	8.3261	0.9488	

**Table 19: Paired sample analysis of the values of the cross sectional area of the left and right temporal horn of the female lateral ventricle**

	Paired Differences					t	df	Sig. 2-tailed
	Mean	SD	SEM	95% confidence interval of the difference				
				Lower	Upper			
LT Temp. horn RT Temp. horn	2.394	8.333	0.9496	0.5022	4.2848	2.521	76	0.014

---



## RESULTS

---

Comparing the values of the right and left temporal horn of all subjects (155; 78 male & 77 female) (**Tables 20, 21**) revealed a highly significant increase ( $p > 0.000$ ) in the cross sectional area of the left temporal horn compared to that of the right temporal horn. The mean cross sectional area of the left temporal horn was  $23.28 \pm 0.79 \text{ mm}^2$  (mean  $\pm$  SEM), while the mean cross sectional area of the right temporal horn was  $20.94 \pm 0.74 \text{ mm}^2$  (mean  $\pm$  SEM).

**Table 20: Paired sample statistics of the cross sectional area of the left and right temporal horn of the lateral ventricle of all subjects**

ALL SUBJECTS	No	Mean cross sectional area $\text{mm}^2$	SD	SEM	Significance
LT Temp. horn:	155	23.280	9.789	0.7863	0.000
RT Temp. horn:	155	20.9361	9.2555	0.7434	

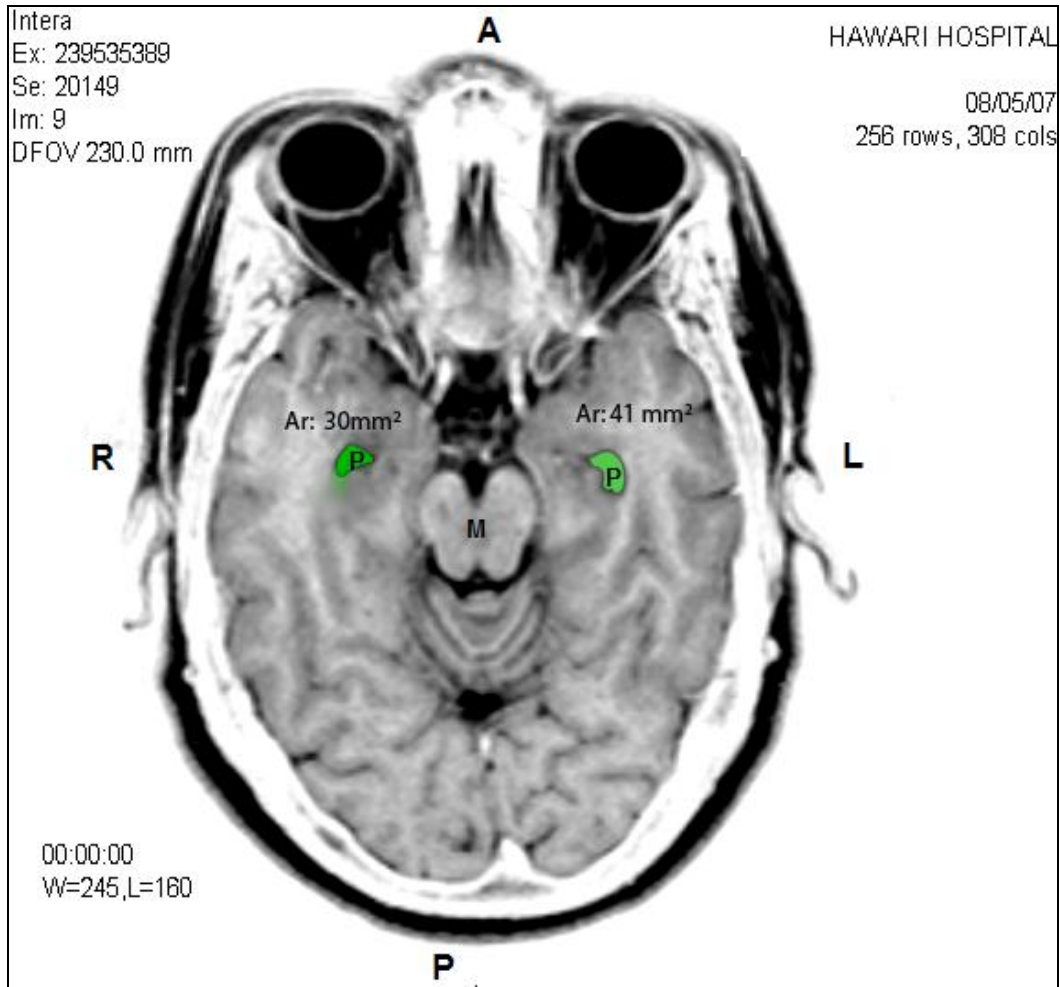
**Table 21: Paired sample analysis of the values of the cross sectional area of the left and right temporal horn of the lateral ventricle of all subjects**

	Paired Differences					t	df	Sig. 2-tailed
	Mean	SD	SEM	95% confidence interval of the difference				
				Lower	Upper			
LT Temp. horn RT Temp. horn	2.344	7.663	0.616	1.128	3.5597	3.808	154	.000

---

**RESULTS**

---

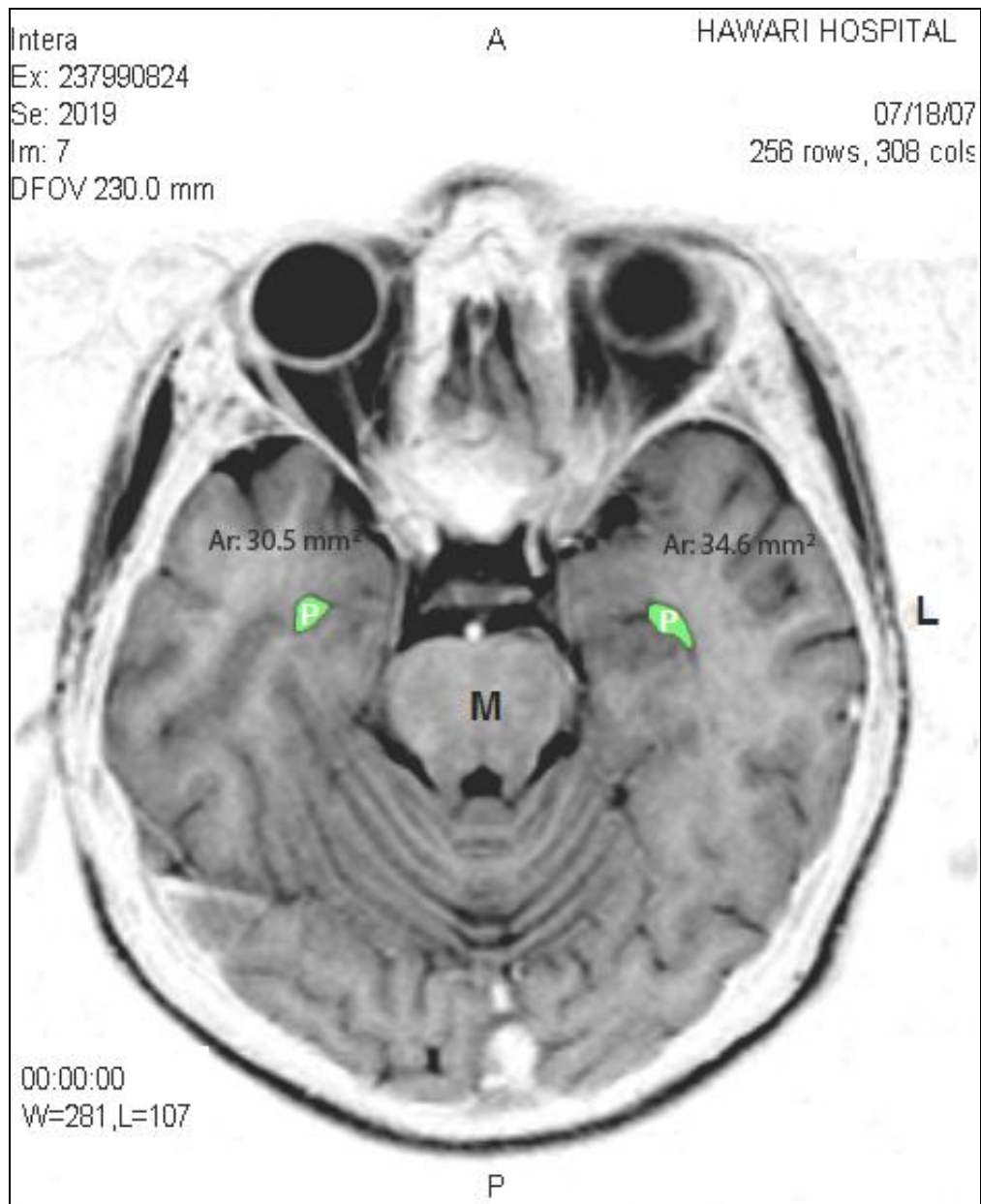


**Fig. 29.** T2 MR Image of axial plane of the brain at the level of the midbrain (M) of a 55 years old male subject showing the values of the cross sectional area of the right and left temporal horn (P).

---

**RESULTS**

---

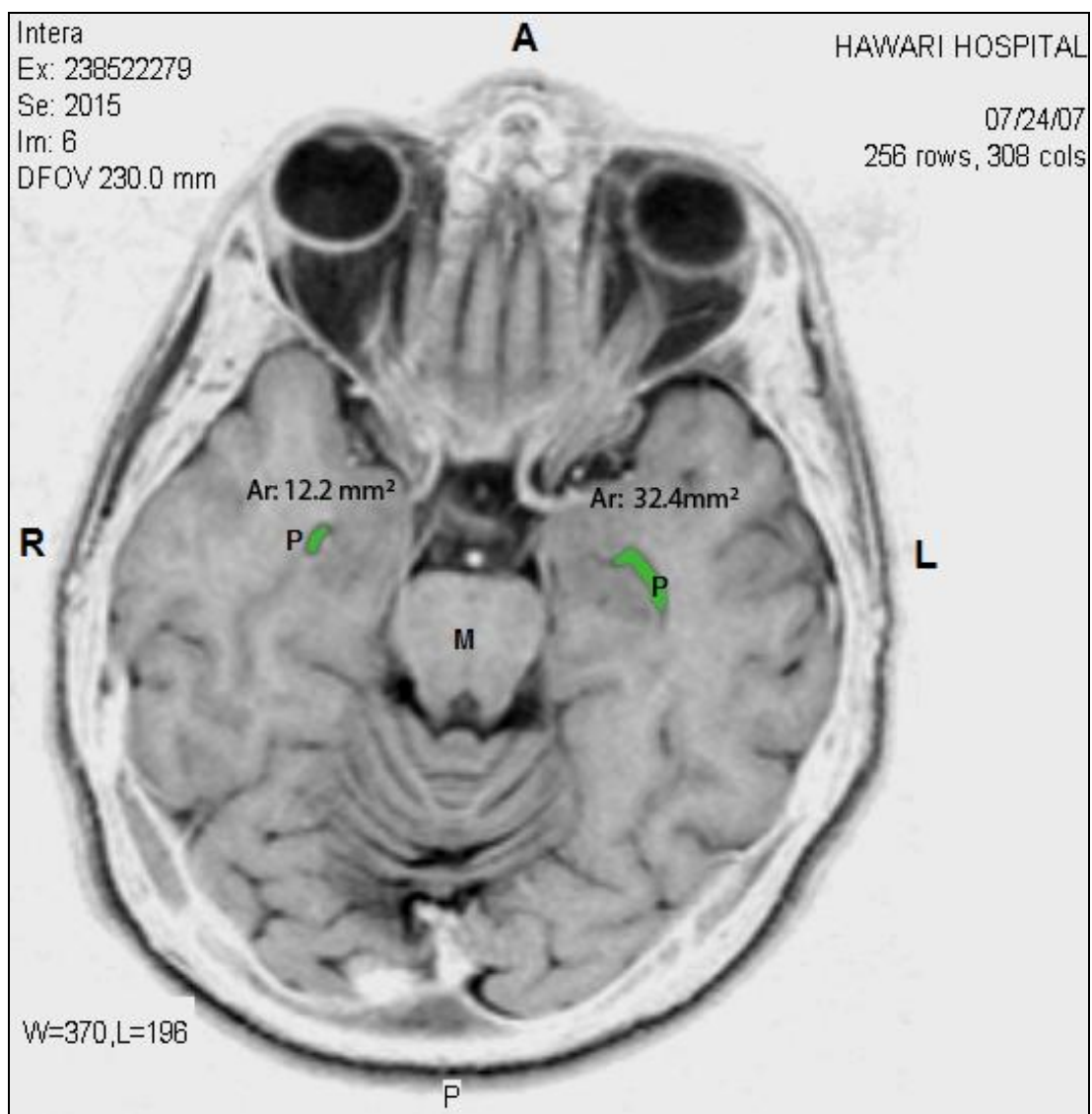


**Fig. 30.** T2 MR Image of axial plane of the brain at the level of the midbrain (M) of a 39 years old male subject showing the values of the cross sectional area of the right and left temporal horn (P).

---

**RESULTS**

---

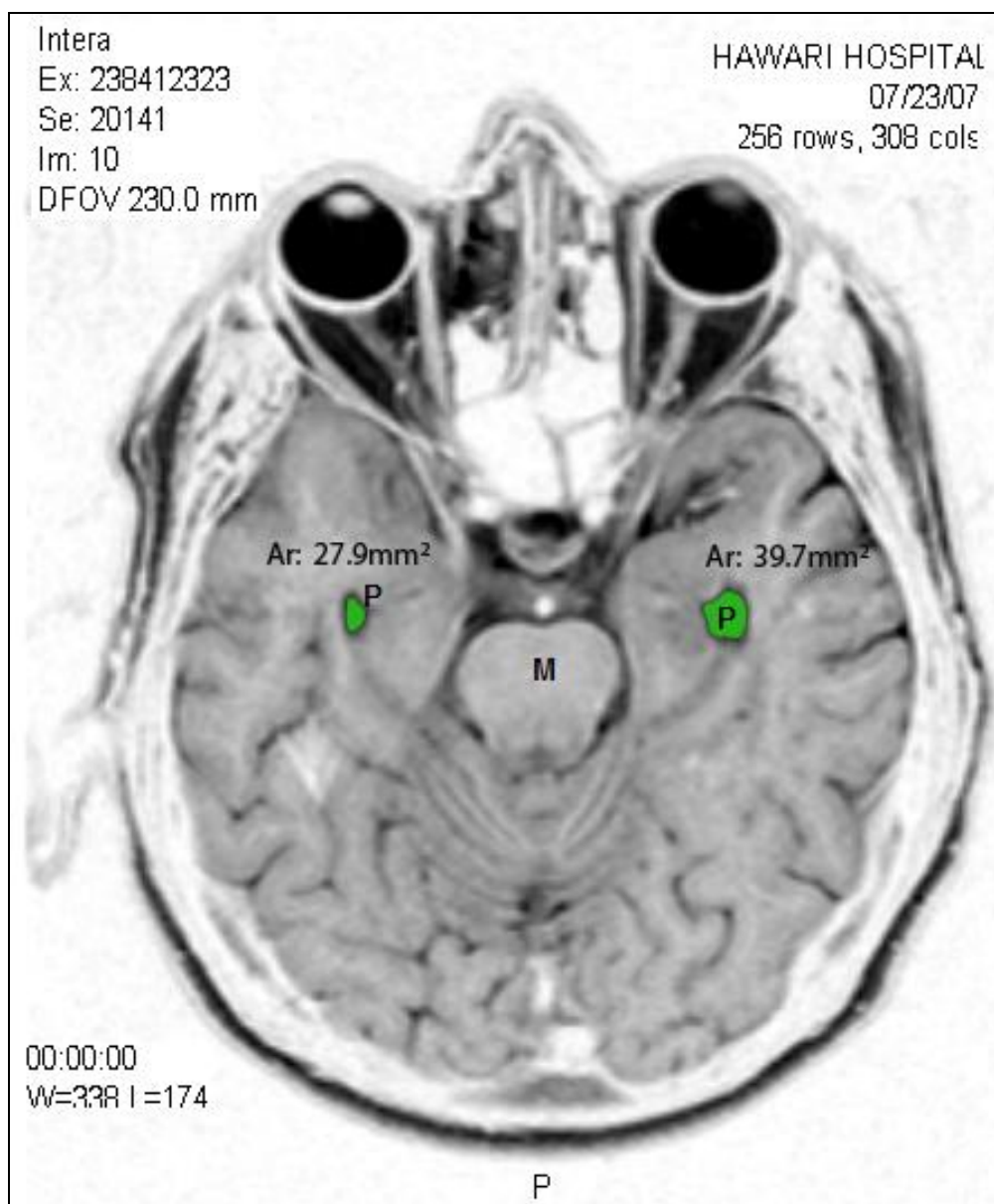


**Fig. 31.** T2 MR Image of axial plane of the brain at the level of the midbrain (M) of a 28 years old male subject showing the values of the cross sectional area of the right and left temporal horn (P).

---

**RESULTS**

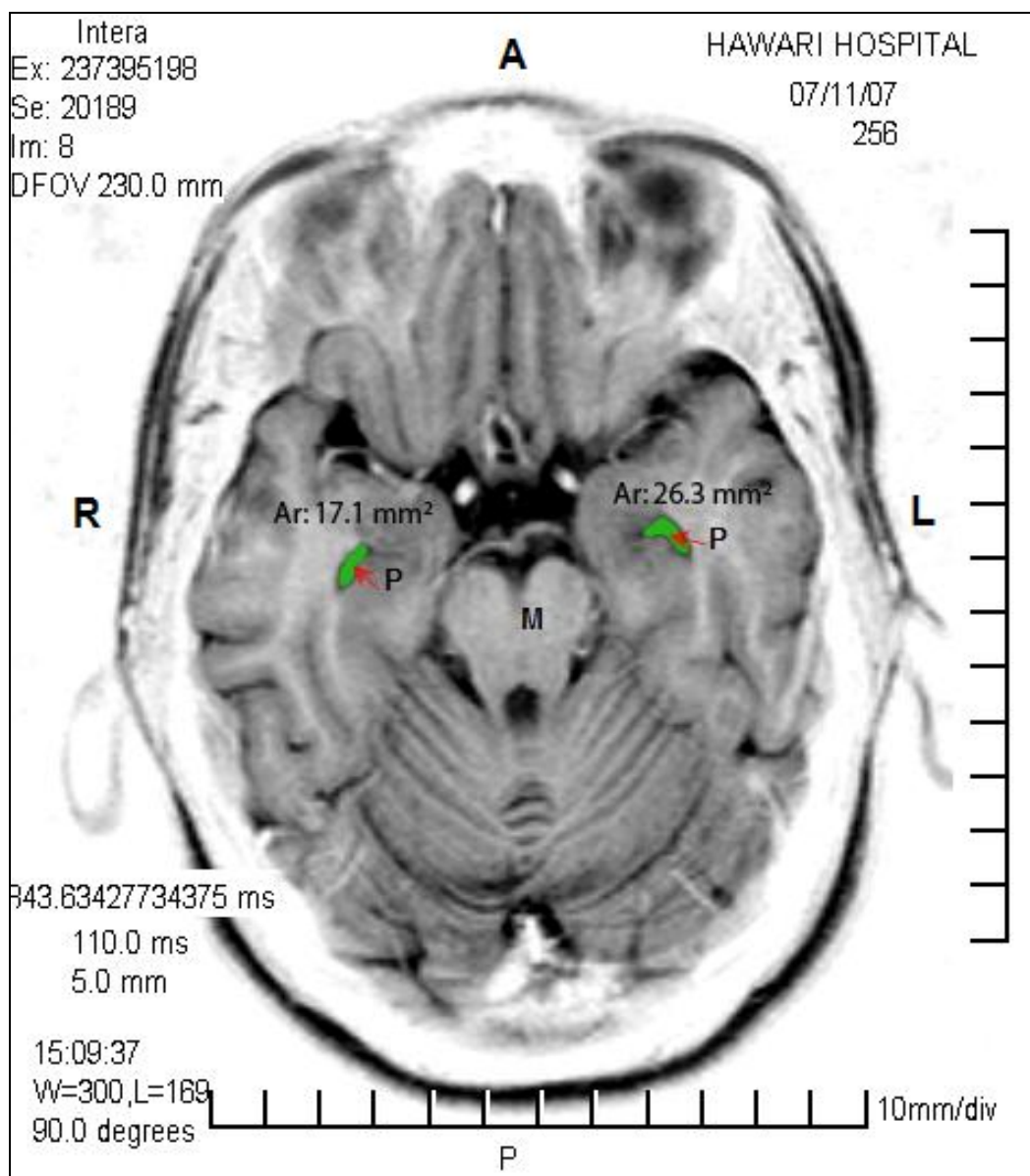
---



**Fig. 32.** T2 MR Image of axial plane of the brain at the level of the midbrain (M) of a 48 years old male subject showing the values of the cross sectional area of the right and left temporal horn (P).

---

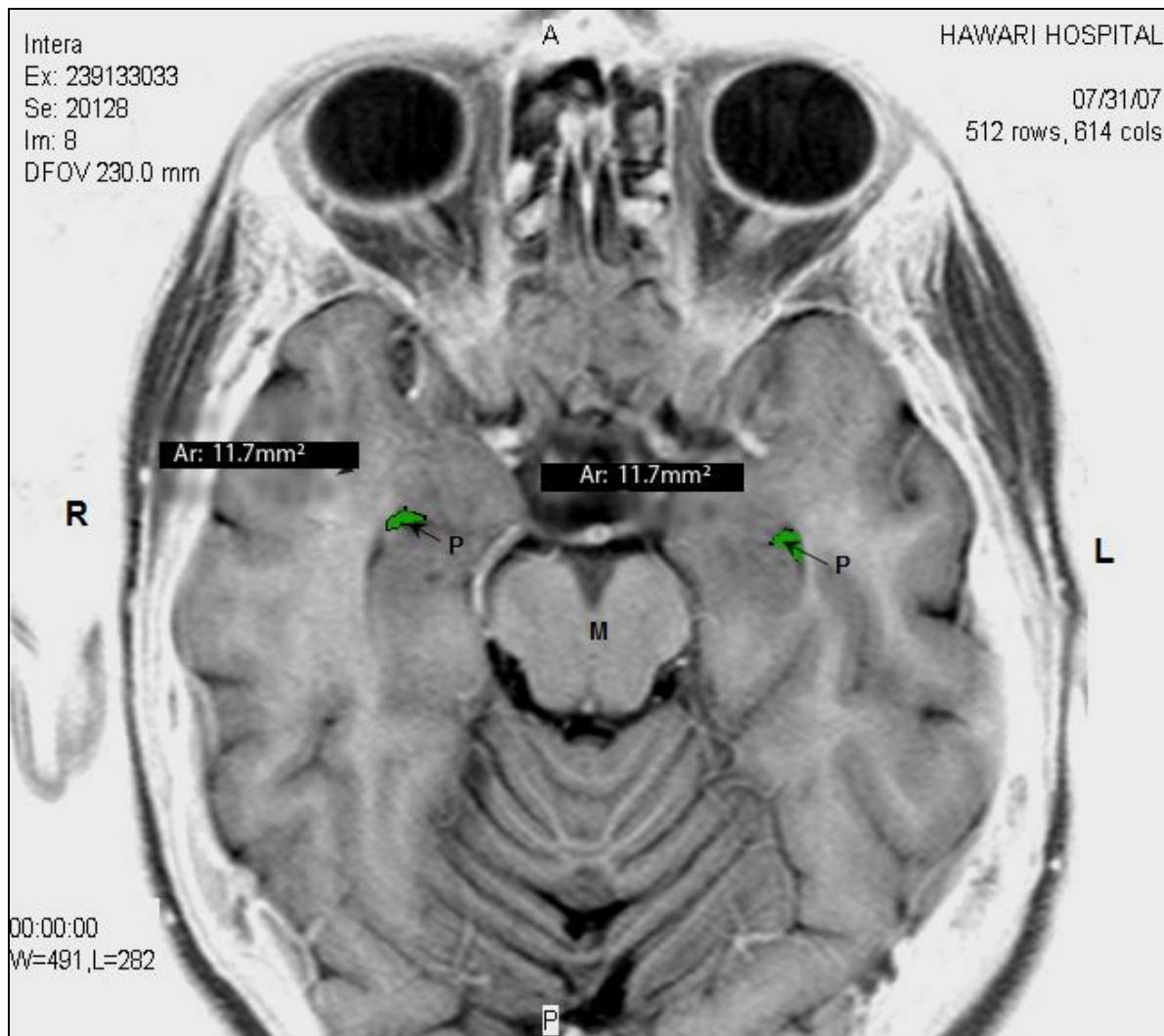
**RESULTS**



**Fig. 33.** T2 MR Image of axial plane of the brain at the level of the midbrain (M) of a 22 years old male subject showing the values of the cross sectional area of the right and left temporal horn (P).

**RESULTS**

---

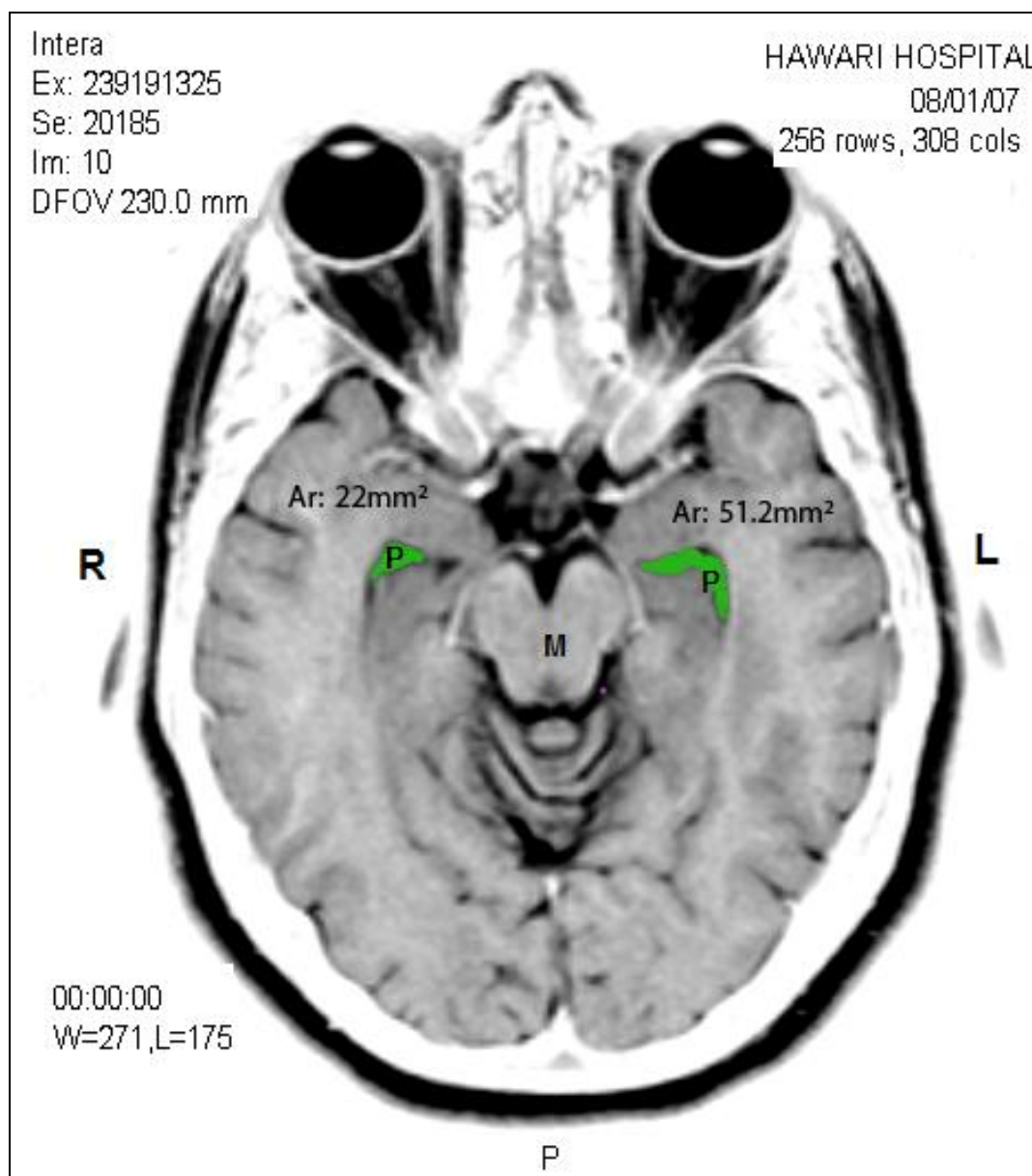


**Fig. 34.** T2 MR Image of axial plane of the brain at the level of the midbrain (M) of a 23 years old female subject showing the values of the cross sectional area of the right and left temporal horn (P).

---

**RESULTS**

---



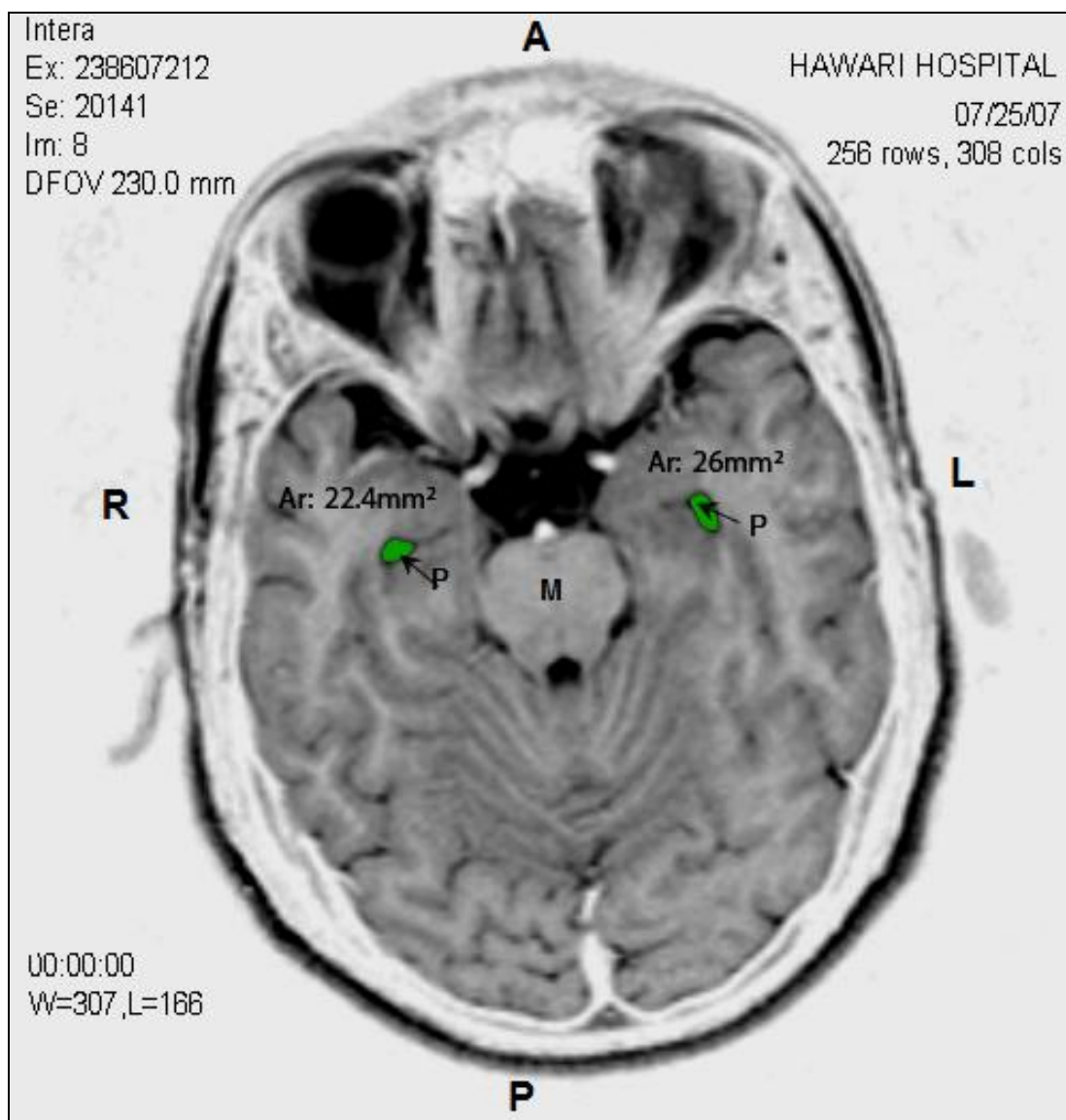
**Fig. 35.** T2 MR Image of axial plane of the brain at the level of the midbrain (M) of a 54 years old female subject showing the values of the cross sectional area of the right and left temporal horn (P).

---



**RESULTS**

---

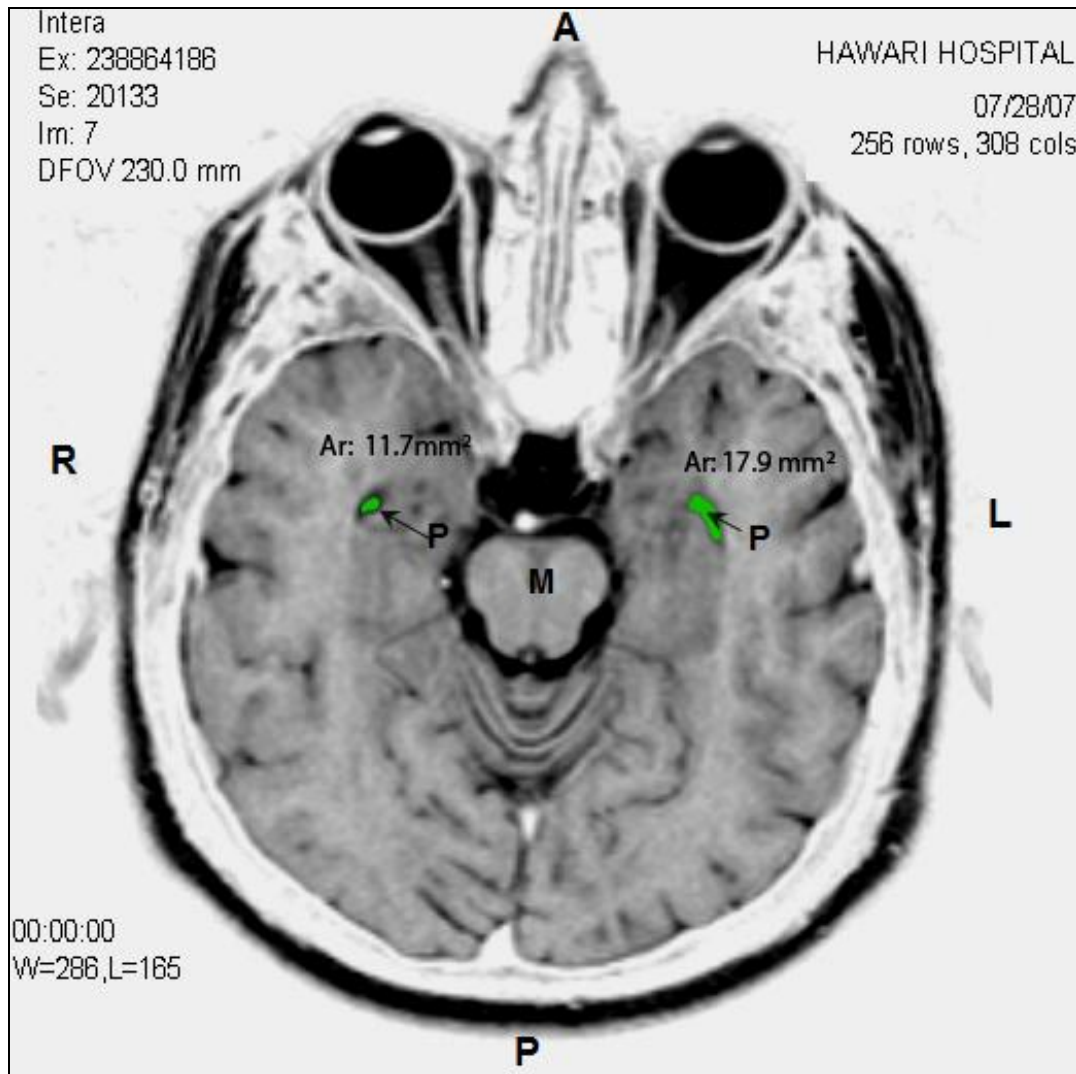


**Fig. 36.** T2 MR Image of axial plane of the brain at the level of the midbrain (M) of a 41 years old female subject showing the values of the cross sectional area of the right and left temporal horn (P).

---

**RESULTS**

---

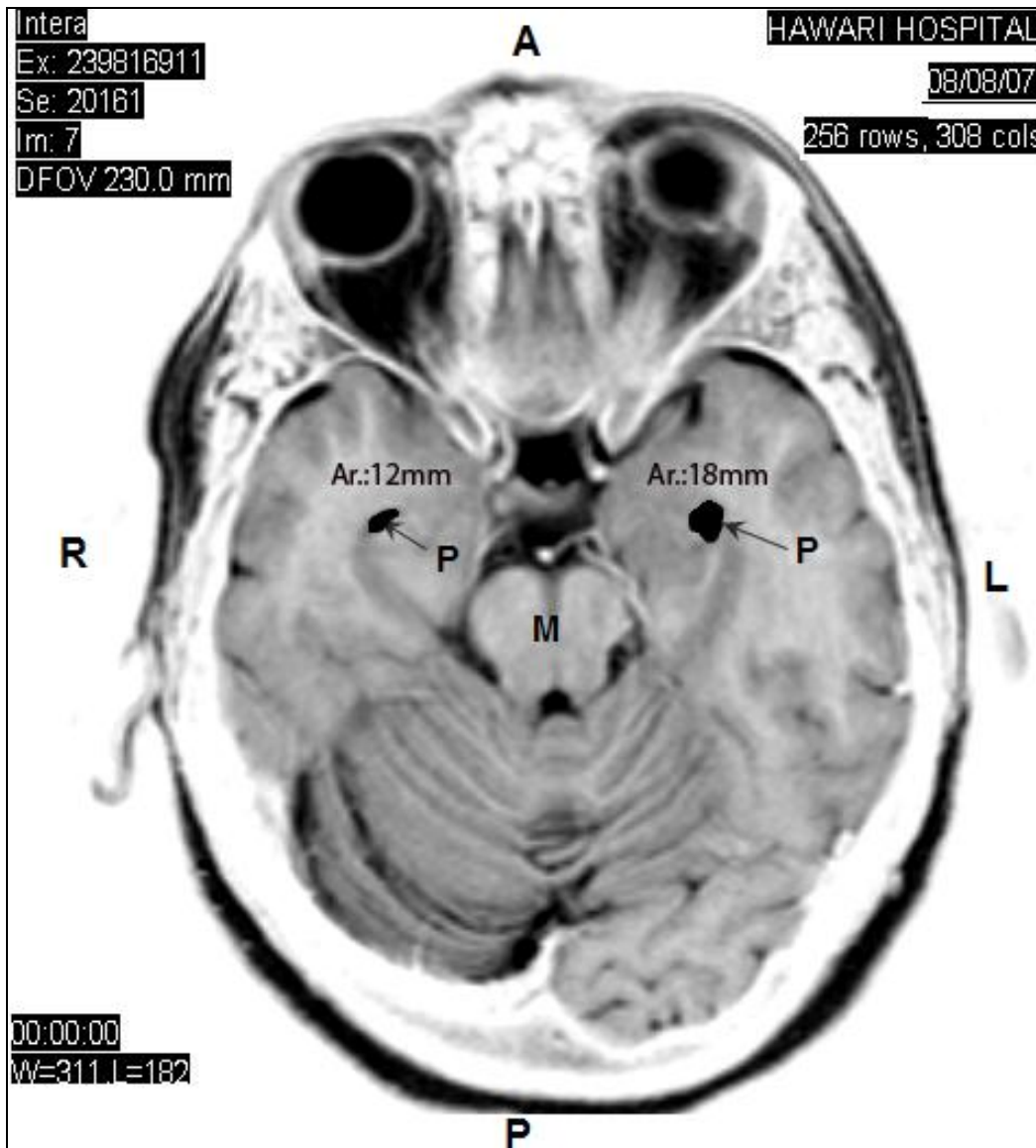


**Fig. 37.** T2 MR Image of axial plane of the brain at the level of the midbrain (M) of a 25 years old female subject showing the values of the cross sectional area of the right and left temporal horn (P).

---

**RESULTS**

---



**Fig. 38.** T2 MR Image of axial plane of the brain at the level of the midbrain (M) of a 30 years old female subject showing the values of the cross sectional area of the right and left temporal horn (P).

---

### **4. VENTRICULAR/HEMISPHERIC (V/H) INDEX**

The ventricular/hemispheric index (V/H index) was measured as the ratio between the distance from the midline to the most lateral point of the lateral ventricle to the corresponding ipsilateral hemispheric width in the coronal plane at the level of the foramen of Monro. Examination of the V/H index of 79 male subjects (**Tables 22, 23**) (**Figs. 39- 48**) revealed a highly significant increase ( $p > 0.000$ ) in the left V/H index compared to that of the right V/H index. The mean left V/H index was  $0.27 \pm 2.93$  (mean  $\pm$  SEM) while the mean right V/H index was  $0.26 \pm 3.11$  (mean  $\pm$  SEM).

**Table 22: Paired sample statistics of the left and right ventricular/hemispheric (V/H) index of the male lateral ventricle**

<b>MALE SUBJECTS</b>	<b>No</b>	<b>Mean V/H INDEX</b>	<b>SD</b>	<b>SEM</b>	<b>Significance</b>
<b>LT V/H INDEX:</b>	79	0.2713	2.6013	2.93	0.000
<b>RT V/H INDEX:</b>	79	0.2654	2.7654	3.11	

**Table 23: Paired sample analysis of the values of the left and right ventricular/hemispheric (V/H) index of the male lateral ventricle**

	Paired Differences					t	df	Sig. 2-tailed
	Mean	SD	SEM	95% confidence interval of the difference				
				Lower	Upper			
<b>LT V/H INDEX RT V/H INDEX</b>	6.03	2.02	2.603	7.504	1.102	2.281	78	0.025

---

**RESULTS**

---

Examination of the V/H Index of 80 female subjects (**Tables 24, 25**) (**Figs. 49 - 54**) revealed a highly significant increase ( $p > 0.000$ ) in the left V/H Index compared to that of the right V/H Index. The mean left V/H Index was  $0.258 \pm 3.29$  (mean  $\pm$  SEM), while the mean right V/H Index was  $0.244 \pm 3.95$  (mean  $\pm$  SEM).

**Table 24: Paired sample statistics of the left and right ventricular/hemispheric (V/H) index of the female lateral ventricle**

FEMALE SUBJECTS	No	Mean V/H INDEX	SD	SEM	Significance
LT V/H INDEX:	80	0.2583	2.939	3.29	0.000
RT V/H INDEX:	80	0.2441	2.530	3.95	

**Table 25: Paired sample analysis of the values of left and right ventricular/hemispheric (V/H) index of the female lateral ventricle**

	Paired Differences					t	df	Sig. 2-tailed
	Mean	SD	SEM	95% confidence interval of the difference				
				Lower	Upper			
LT V/H INDEX RT V/H INDEX	1.42	3.3475	3.74	6.72	2.16	3.786	79	.000

---

## RESULTS

---

Comparing the left and right V/H Index of all subjects (159; 79 males & 80 females) (**Tables 26, 27**) revealed a highly significant increase ( $p > 0.000$ ) in the left V/H Index compared to that of the right V/H Index. The mean left V/H Index was  $0.26 \pm 2.93$  (mean  $\pm$  SEM), while the mean right V/H Index was  $0.25 \pm 3.11$  (mean  $\pm$  SEM).

**Table 26: Paired sample statistics of the left and right ventricular/hemispheric (V/H) index of the lateral ventricle of all subjects**

MALE SUBJECTS	No	Mean V/H INDEX	SD	SEM	Significance
LT V/H INDEX:	159	0.2648	2.8438	2.93	0.000
RT V/H INDEX:	159	0.2547	3.3386	3.11	

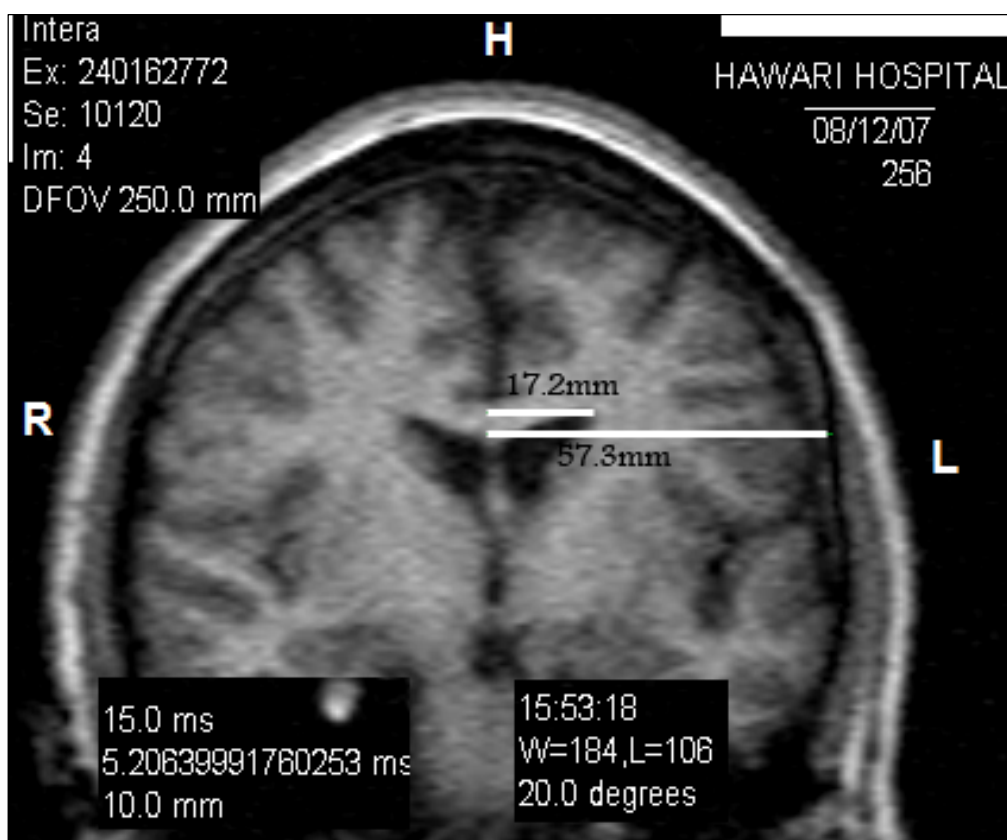
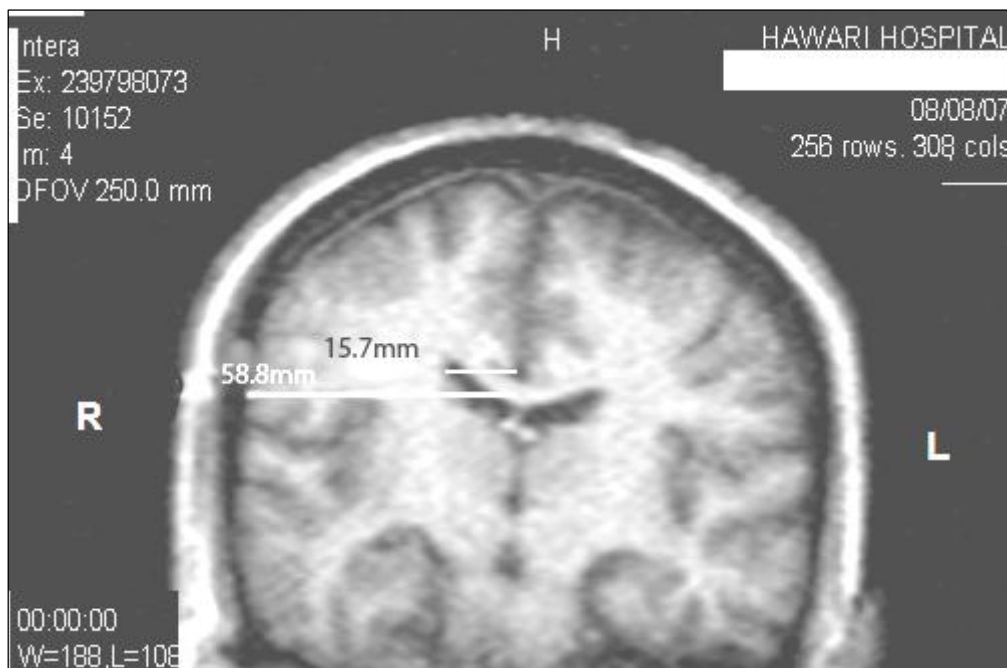
**Table 27: Paired sample analysis of the left and right ventricular/hemispheric (V/H) index of the lateral ventricle of all subjects**

	Paired Differences					t	df	Sig. 2-tailed
	Mean	SD	SEM	95% confidence interval of the difference				
				Lower	Upper			
LT V/H INDEX RT V/H INDEX	1.02	2.897	2.303	5.504	1.502	4.381	**	.000

---

**RESULTS**

---

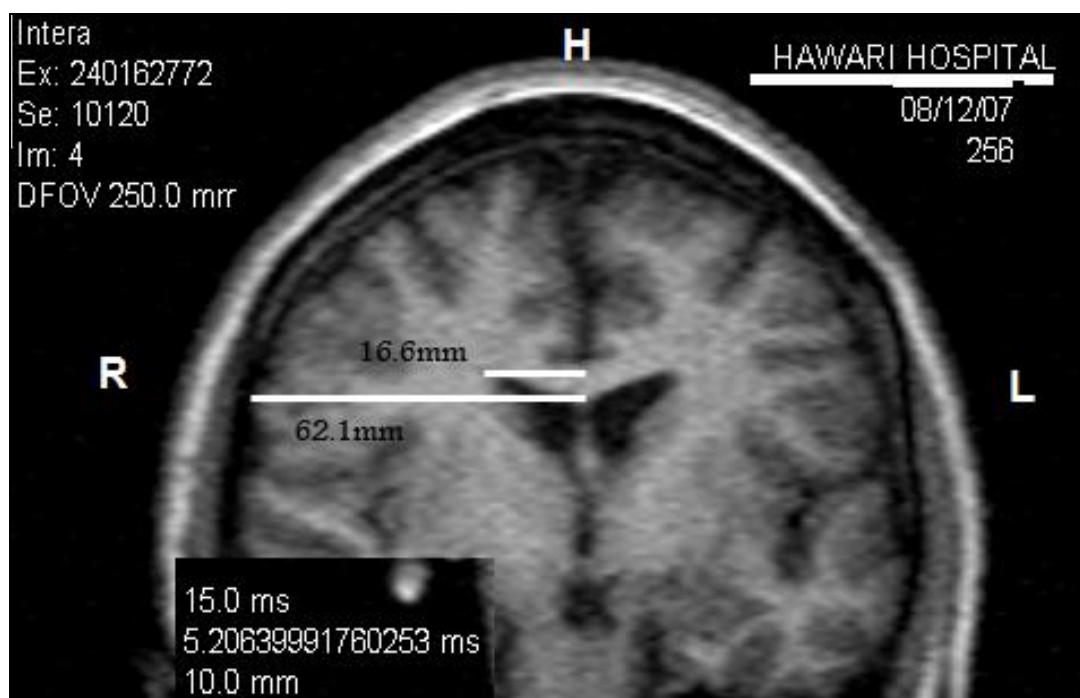


**Figs. 39 & 40.** T2 MR Images of coronal plane of the brain at the level of the foramen of Monro of male subjects showing the calculation of the left V/H index.

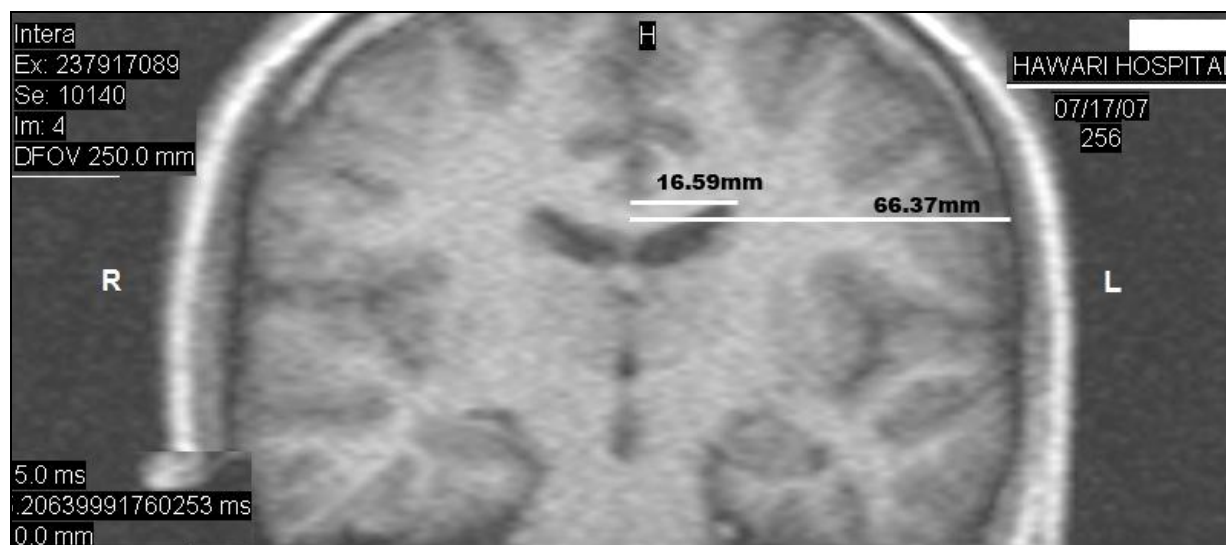
---

**RESULTS**

---



**Fig. 41.** T2 MR Image of coronal plane of the brain at the level of the foramen of Monro of a male subject showing the calculation of the right V/H index.



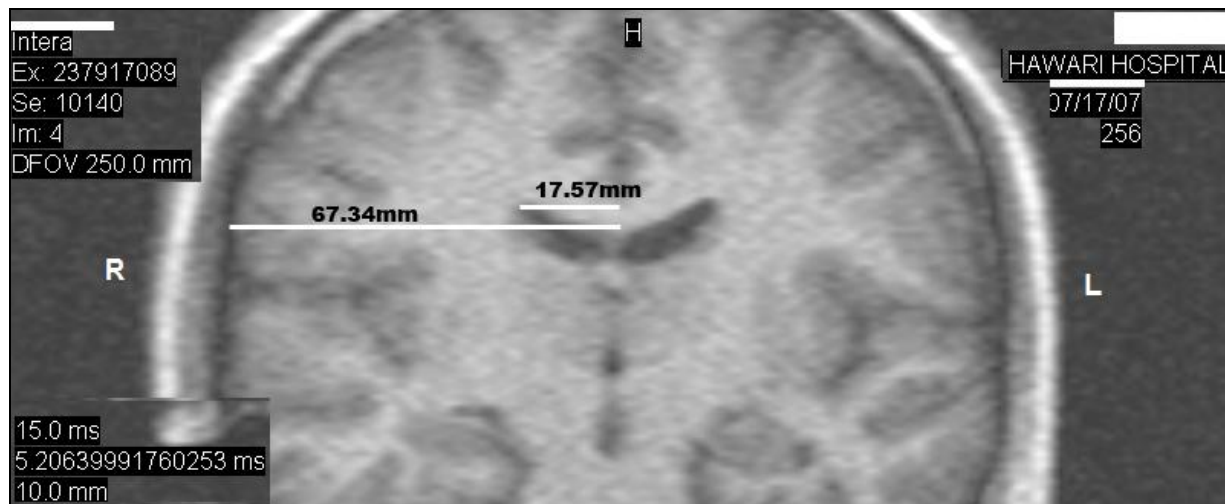
**Fig. 42.** T2 MR Image of coronal plane of the brain at the level of the foramen of Monro of a male subject showing the calculation of the left V/H index.

---

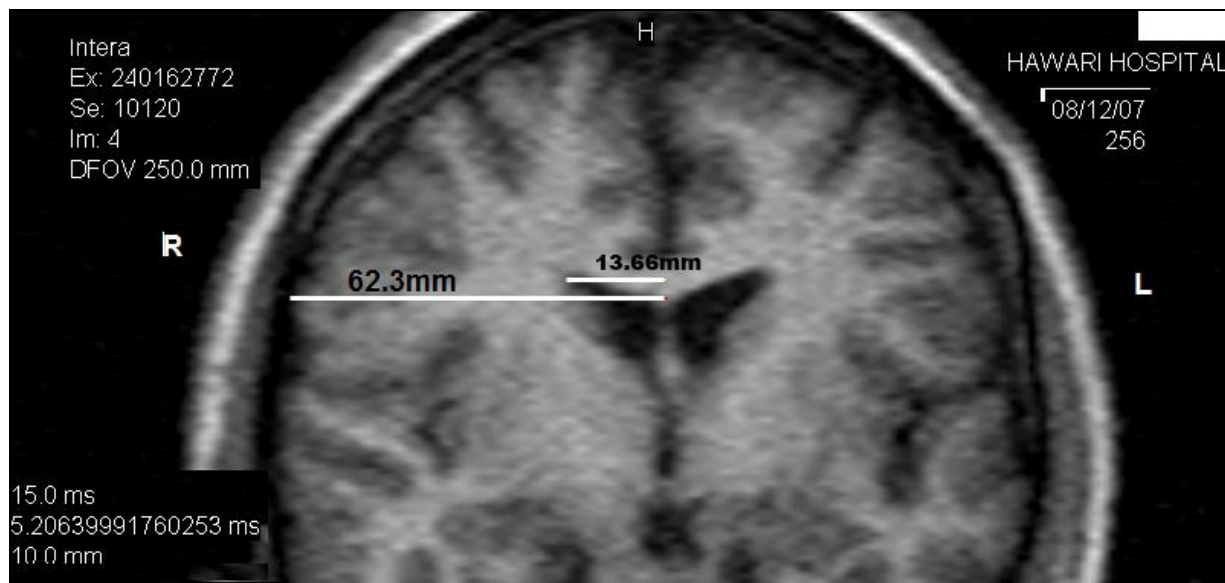


**RESULTS**

---



**Fig. 43.** T2 MR Image of coronal plane of the brain at the level of the foramen of Monro of a male subject showing the calculation of the right V/H index.

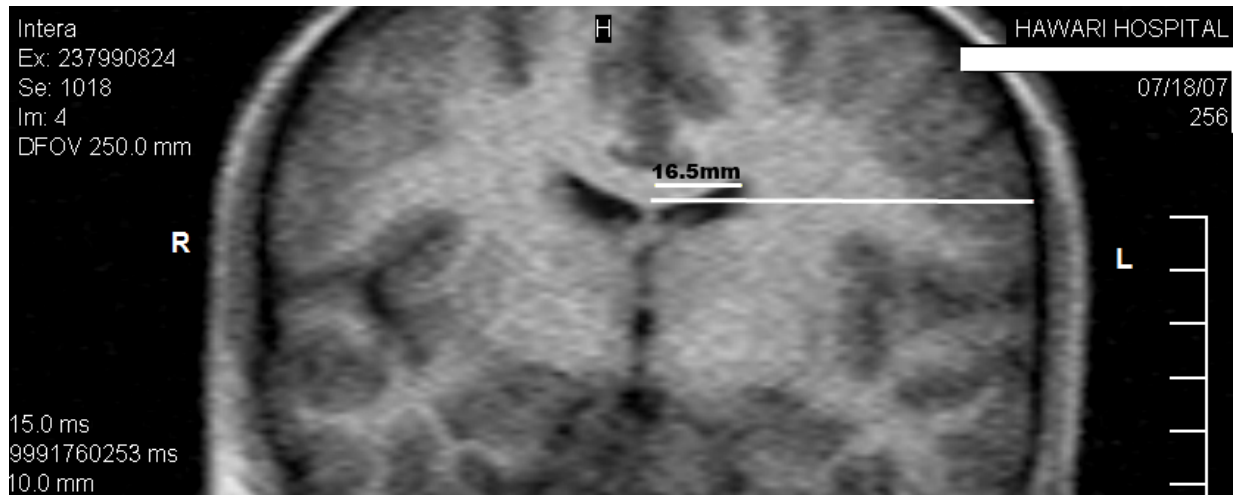


**Fig. 44.** T2 MR Image of coronal plane of the brain at the level of the foramen of Monro of a male subject showing the calculation of the right V/H index.

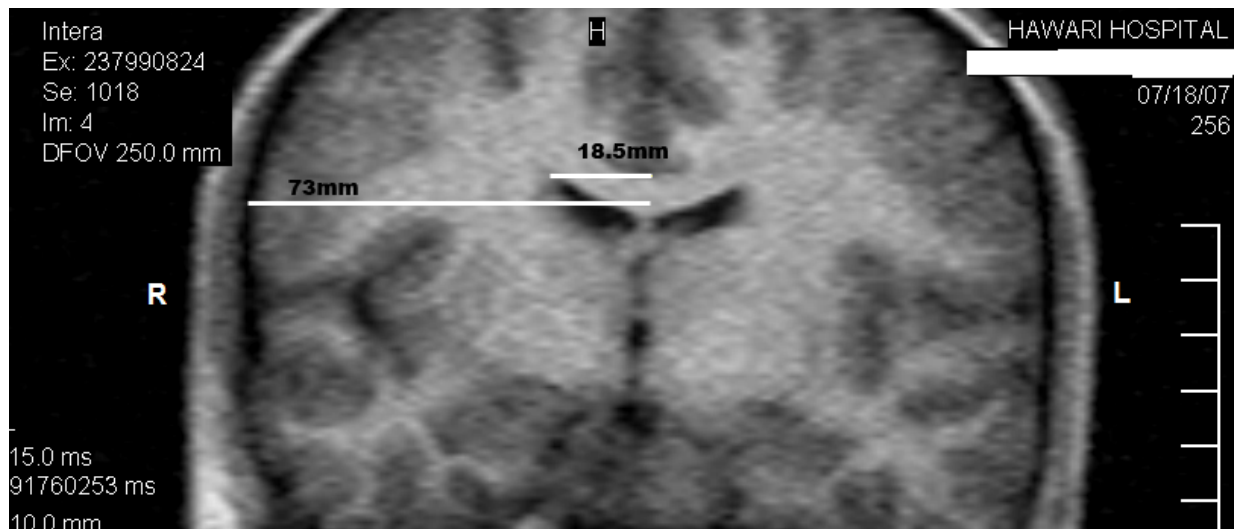
---

**RESULTS**

---



**Fig. 45.** T2 MR Image of coronal plane of the brain at the level of the foramen of Monro of a male subject showing the calculation of the left V/H index.

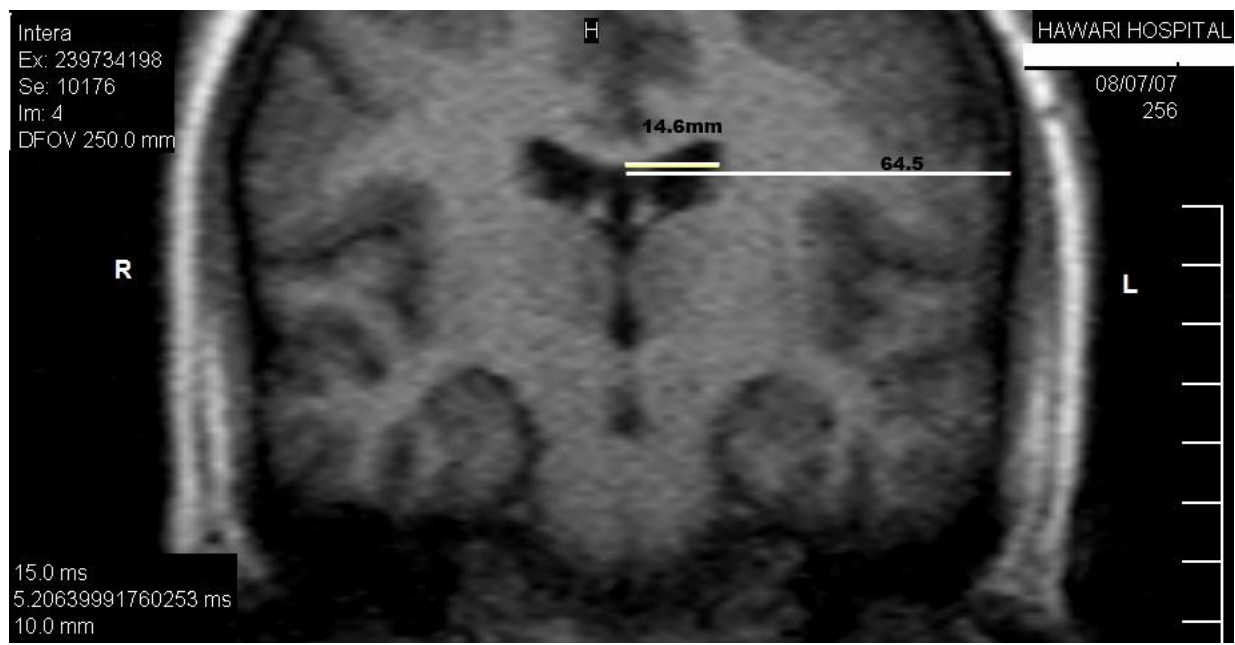


**Fig. 46.** T2 MR Image of coronal plane of the brain at the level of the foramen of Monro of a male subject showing the calculation of the right V/H index.

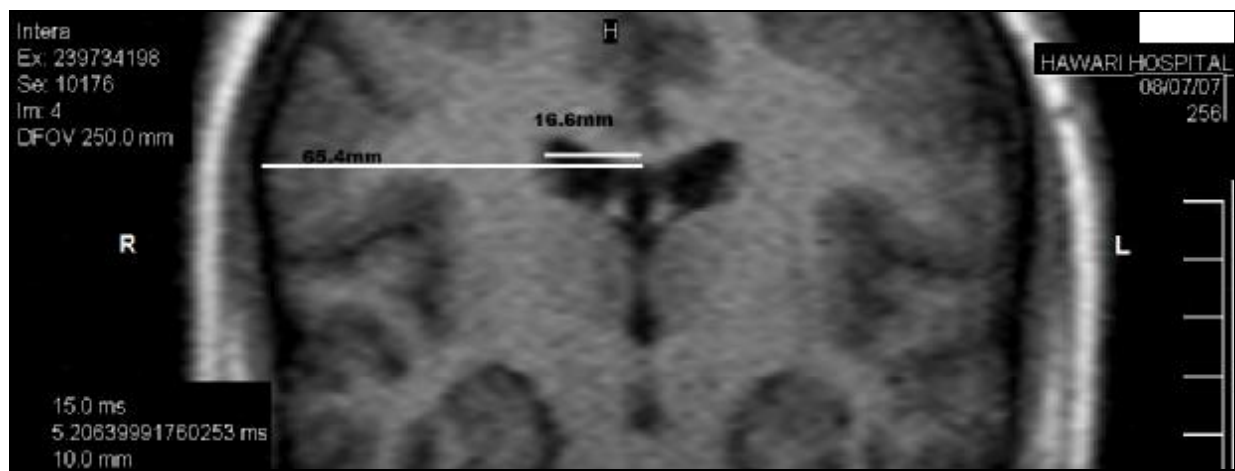
---

**RESULTS**

---



**Fig. 47.** T2 MR Image of coronal plane of the brain at the level of the foramen of Monro of a male subject showing the calculation of the left V/H index.

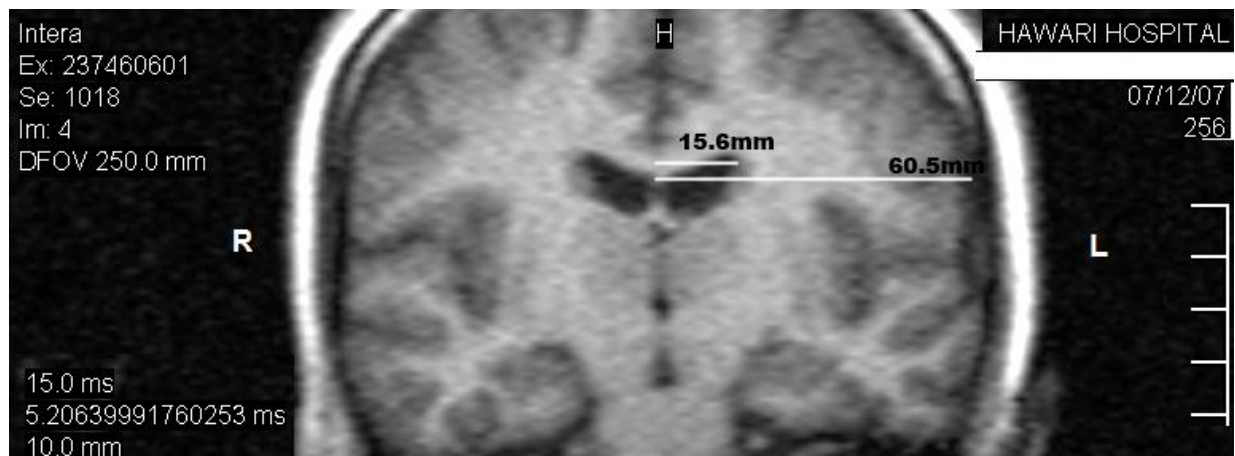


**Fig. 48.** T2 MR Image of coronal plane of the brain at the level of the foramen of Monro of a male subject showing the calculation of the right V/H index.

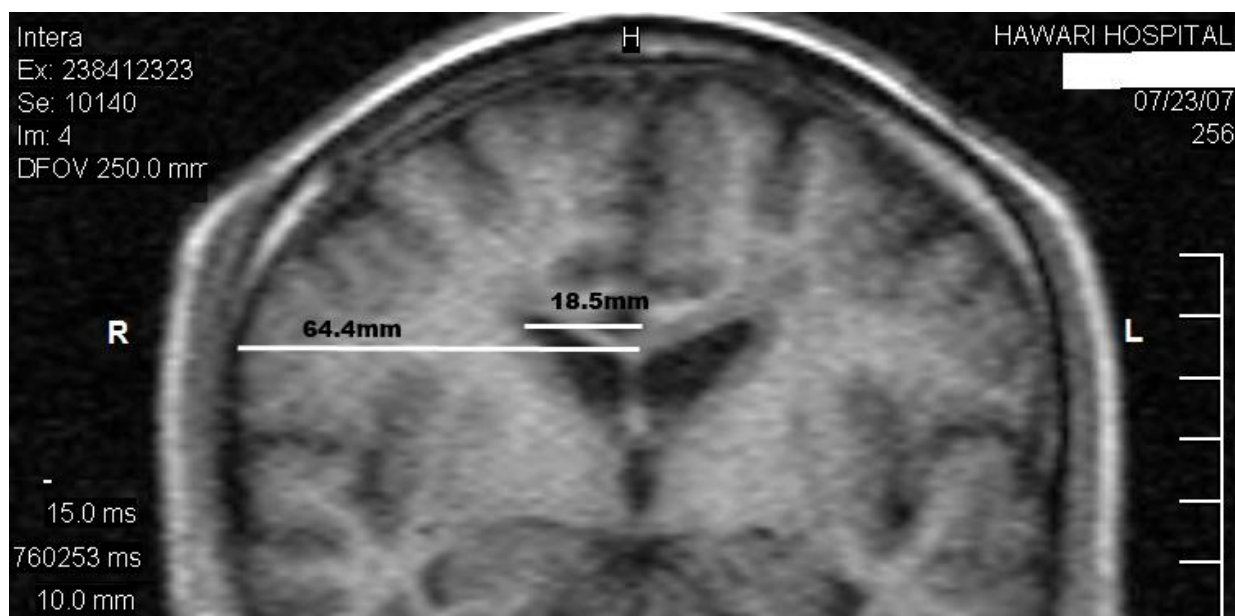
---

**RESULTS**

---



**Fig. 49.** T2 MR Image of coronal plane of the brain at the level of the foramen of Monro of a female subject showing the calculation of the left V/H index.

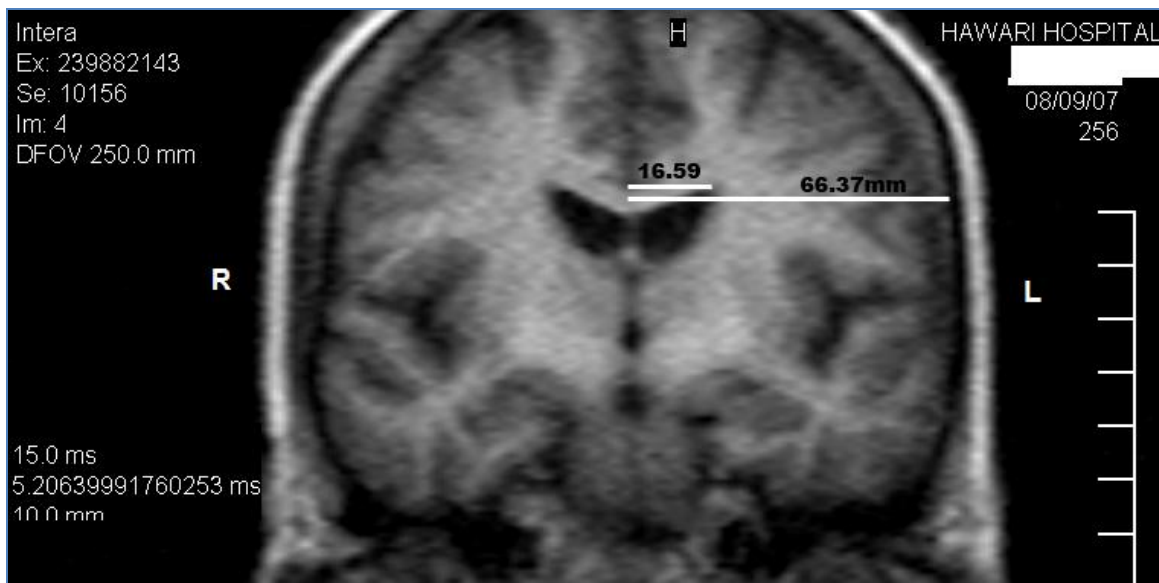


**Fig. 50.** T2 MR Image of coronal plane of the brain at the level of the foramen of Monro of a female subject showing the calculation of the right V/H index.

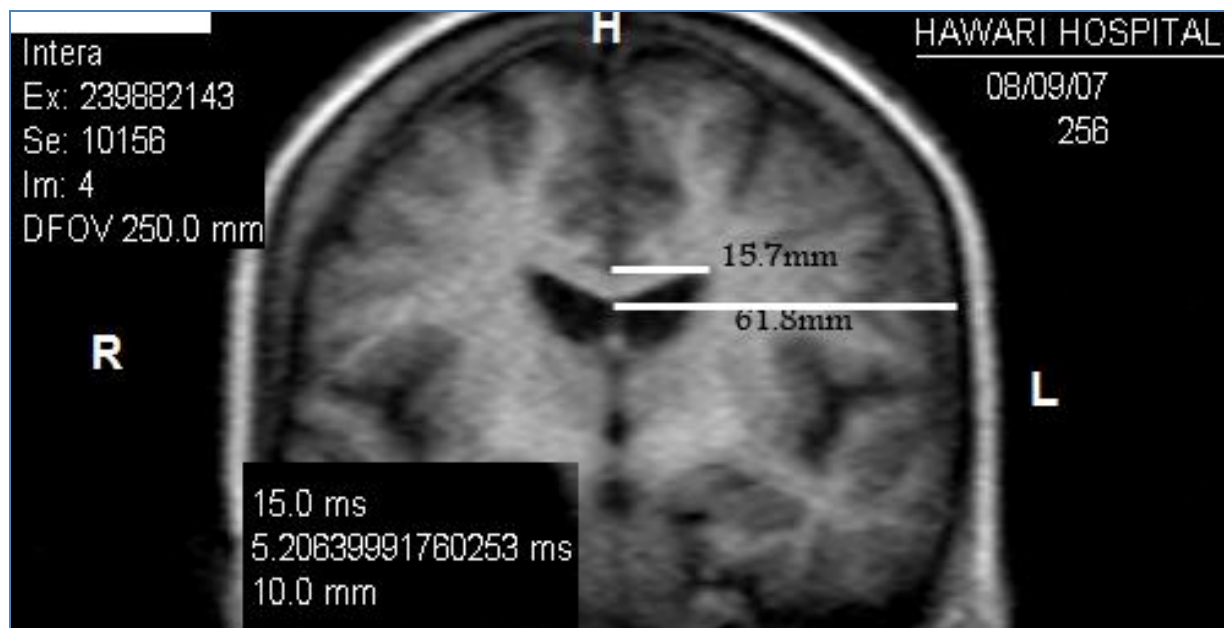
---

**RESULTS**

---



**Fig. 51.** T2 MR Image of coronal plane of the brain at the level of the foramen of Monro of a female subject showing the calculation of the left V/H index.

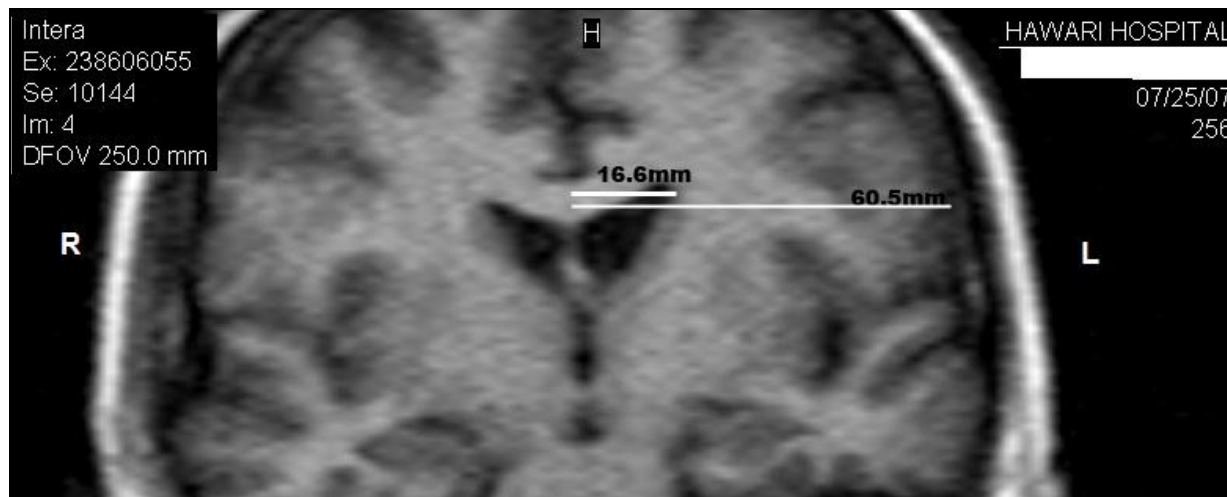


**Fig. 52.** T2 MR Image of coronal plane of the brain at the level of the foramen of Monro of a female subject showing the calculation of the left V/H index.

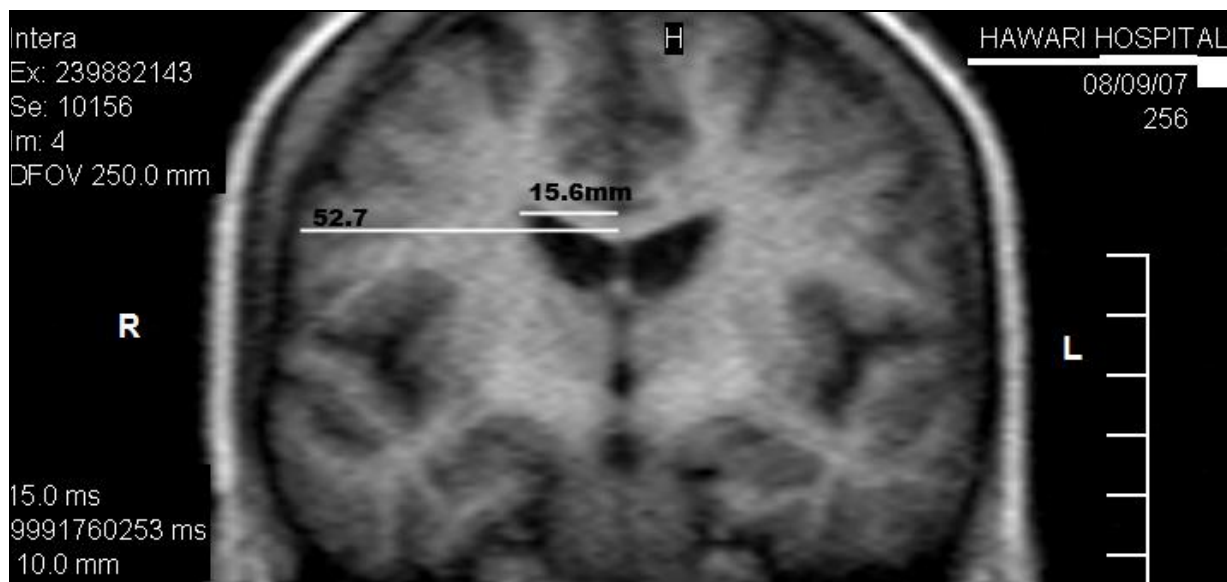
---

**RESULTS**

---



**Fig. 53.** T2 MR Image of coronal plane of the brain at the level of the foramen of Monro of a female subject showing the calculation of the left V/H index.



**Fig. 54.** T2 MR Image of coronal plane of the brain at the level of the foramen of Monro of a female subject showing the calculation of the right V/H index.

---

## **5. VENTRICULAR INDEX (VI) (EVANS' INDEX)**

The ventricular index (VI; Evans' Index) was measured as the ratio between the distance between the anterior tips of the frontal horns and the bi-frontal diameter of the brain (from inner table of skull) at the same level. We compared the **VI** of the male, female and total subjects with the international standard values of the **VI**. The standard normal Evans' Index averaged 0.28 (range, 0.24 – 0.31) for normal adult brain (**Brunberg et al., 2002**). In the present investigation, the male Evans' Index was  $0.291 \pm 0.002$  (**Table 28**) (**Figs. 55 – 59**), the female Evans' Index was  $0.278 \pm 0.001$  (**Table 29**) (**Figs. 60 – 64**), while Evans' Index of all subjects was  $0.278 \pm 0.001$  (**Table 30**).

**Table 28: The VI of the lateral ventricle of the male subjects**

MALE SUBJECTS	NO.	MEAN OF THE VI	SD	SDM	99% confidence interval of the difference	
					UPPER	LOWER
	80	0.29183	0.01992	.00223	0.29711	0.28654

---

**RESULTS**

---

**Table 29: The VI of the lateral ventricle of the female subjects**

FEMALE SUBJECTS	NO.	MEAN OF THE VI	SD	SDM	99% confidence interval of the difference	
					UPPER	LOWER
	80	0.27869	0.01672	0.00187	0.28313	0.27425

**Table 30: The VI of the lateral ventricle of the all subjects**

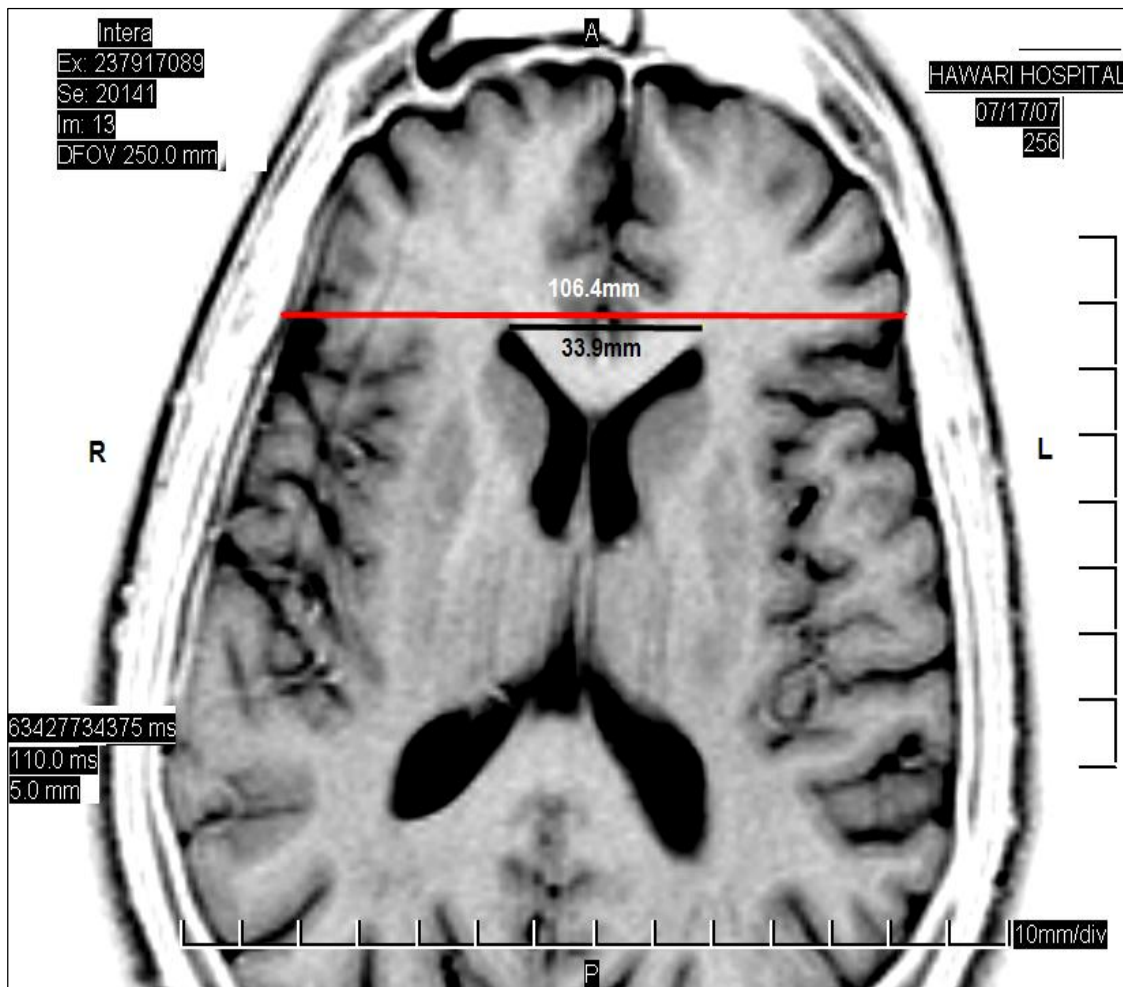
ALL SUBJECTS	NO.	MEAN OF THE VI	SD	SDM	99% confidence interval of the difference	
					UPPER	LOWER
	160	0.28526	0.01948	0.00154	0.28888	0.28164

---



**RESULTS**

---

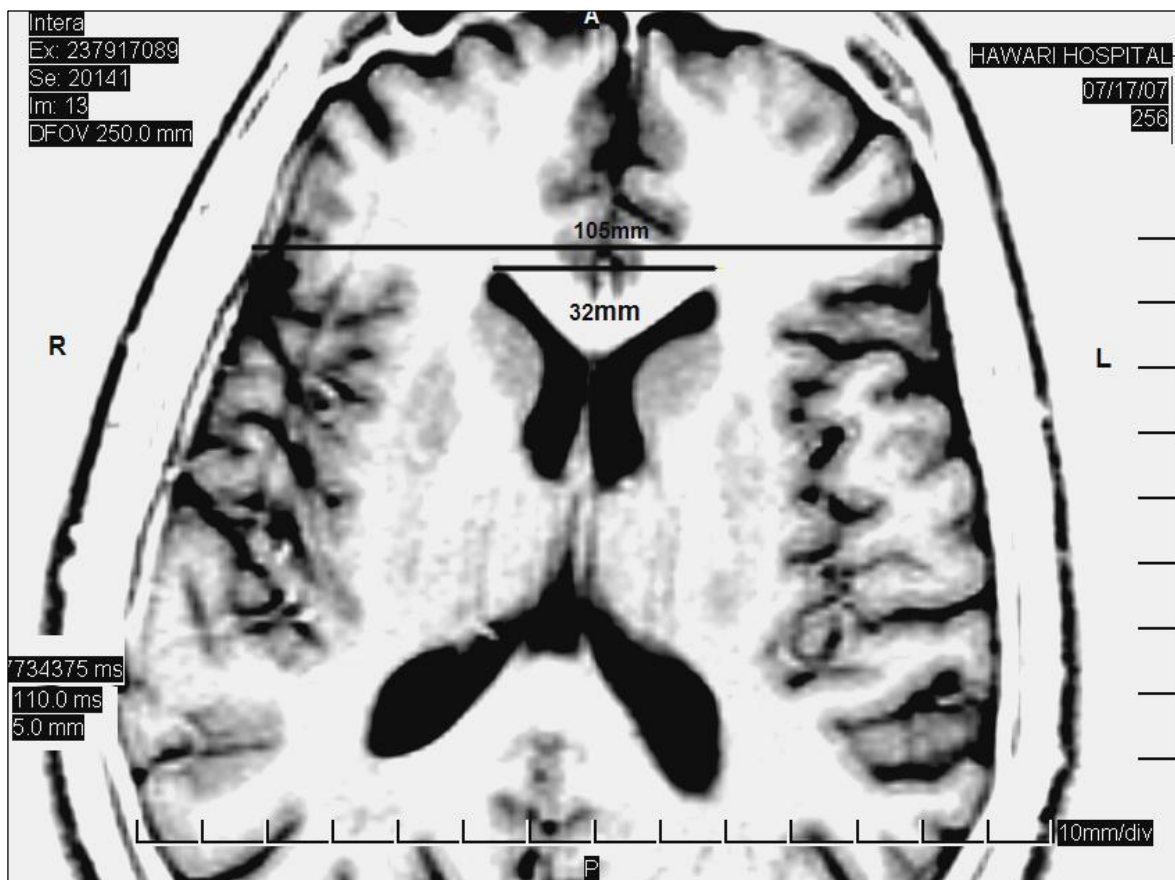


**Fig. 55.** T2 MR Image of axial plane of the brain at the level of the head of caudate nucleus of a male subject showing the calculation of Evans' index.

---

**RESULTS**

---

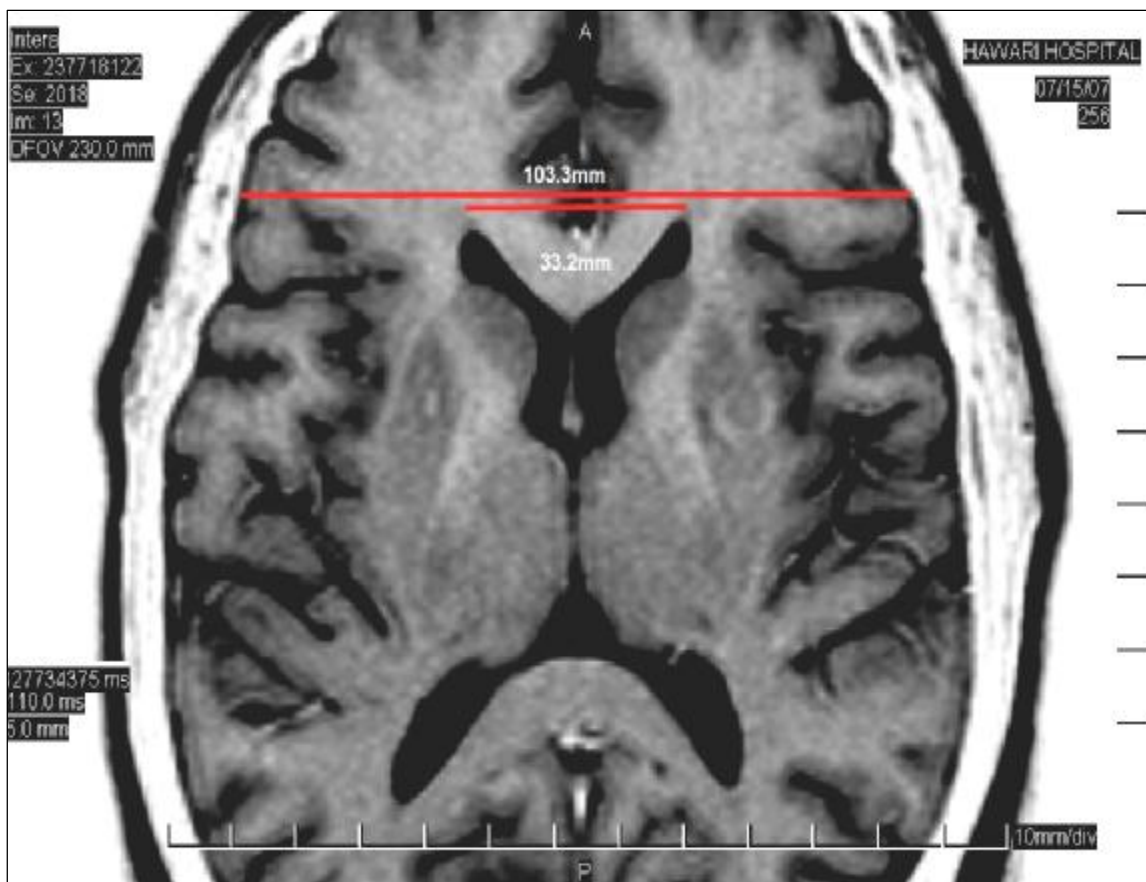


**Fig.56.** T2 MR Image of axial plane of the brain at the level of the head of caudate nucleus of a male subject showing the calculation of Evans' index.

---

**RESULTS**

---

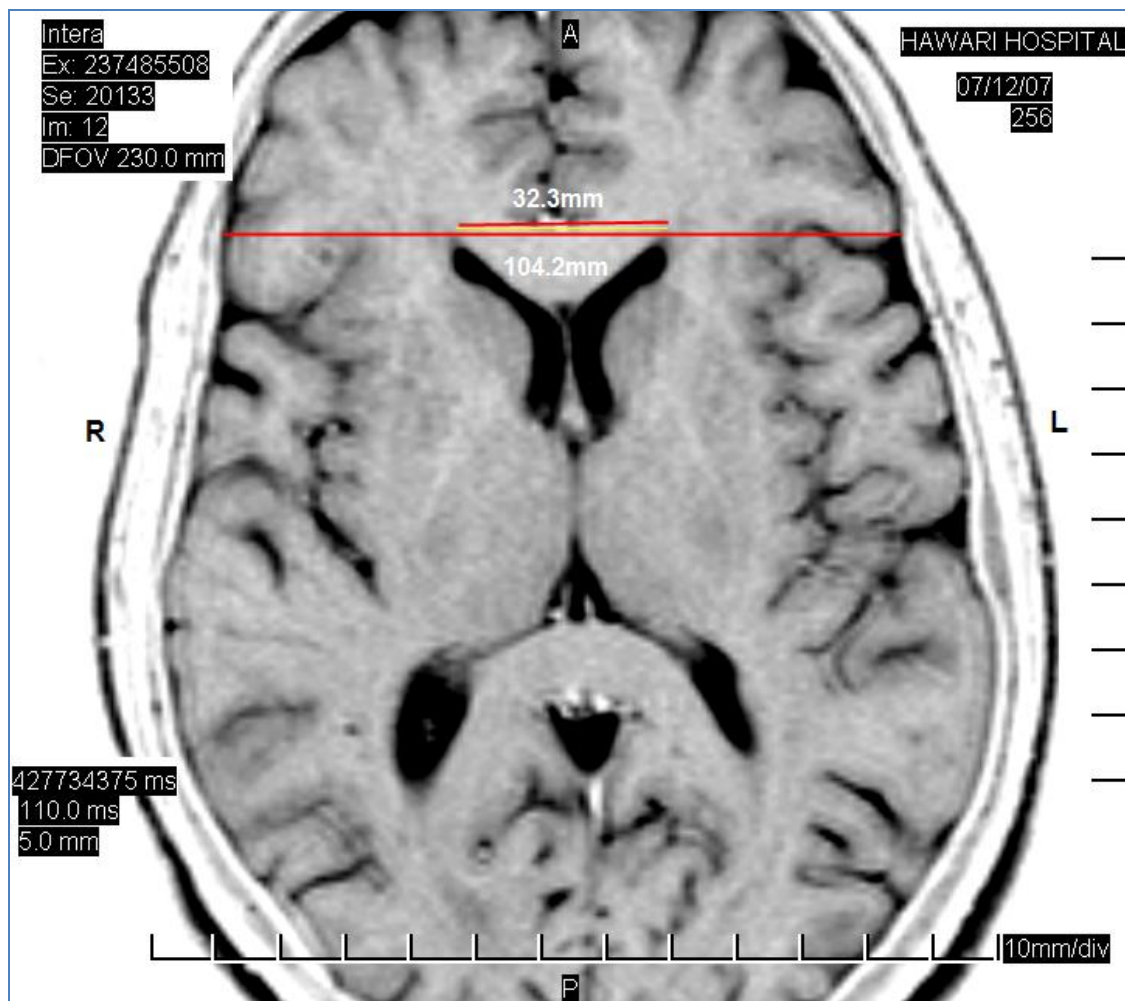


**Fig. 57.** T2 MR Image of axial plane of the brain at the level of the head of caudate nucleus of a male subject showing the calculation of Evans' index.

---

**RESULTS**

---

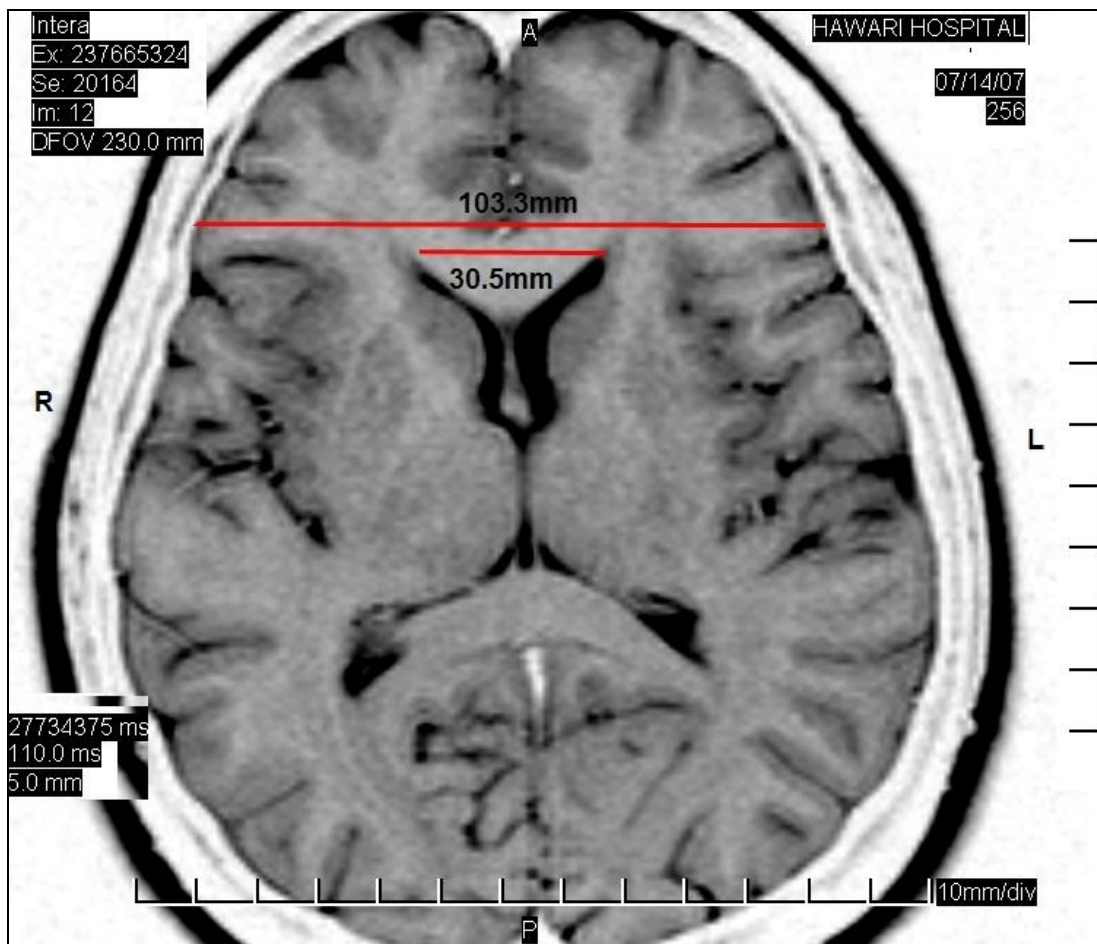


**Fig.58.** T2 MR Image of axial plane of the brain at the level of the head of caudate nucleus of a male subject showing the calculation of Evans' index.

---

**RESULTS**

---

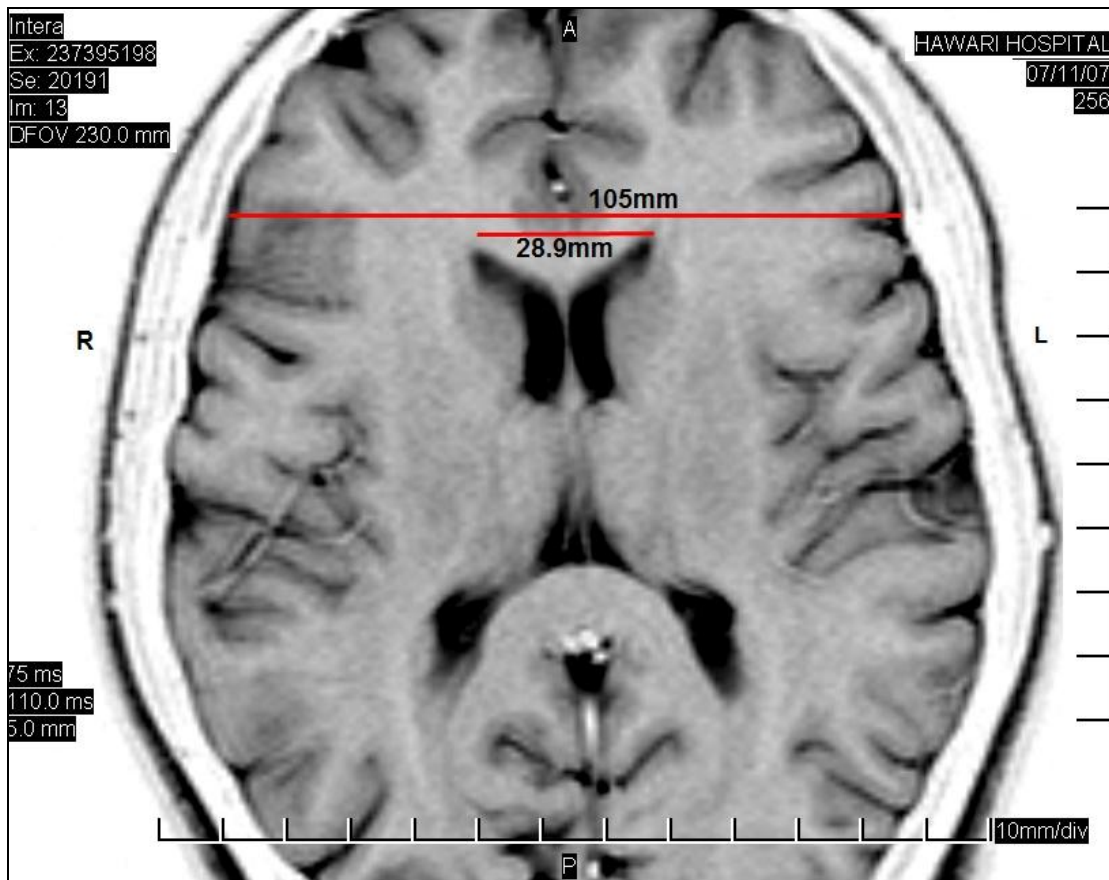


**Fig. 59.** T2 MR Image of axial plane of the brain at the level of the head of caudate nucleus of a male subject showing the calculation of Evans' index.

---

**RESULTS**

---

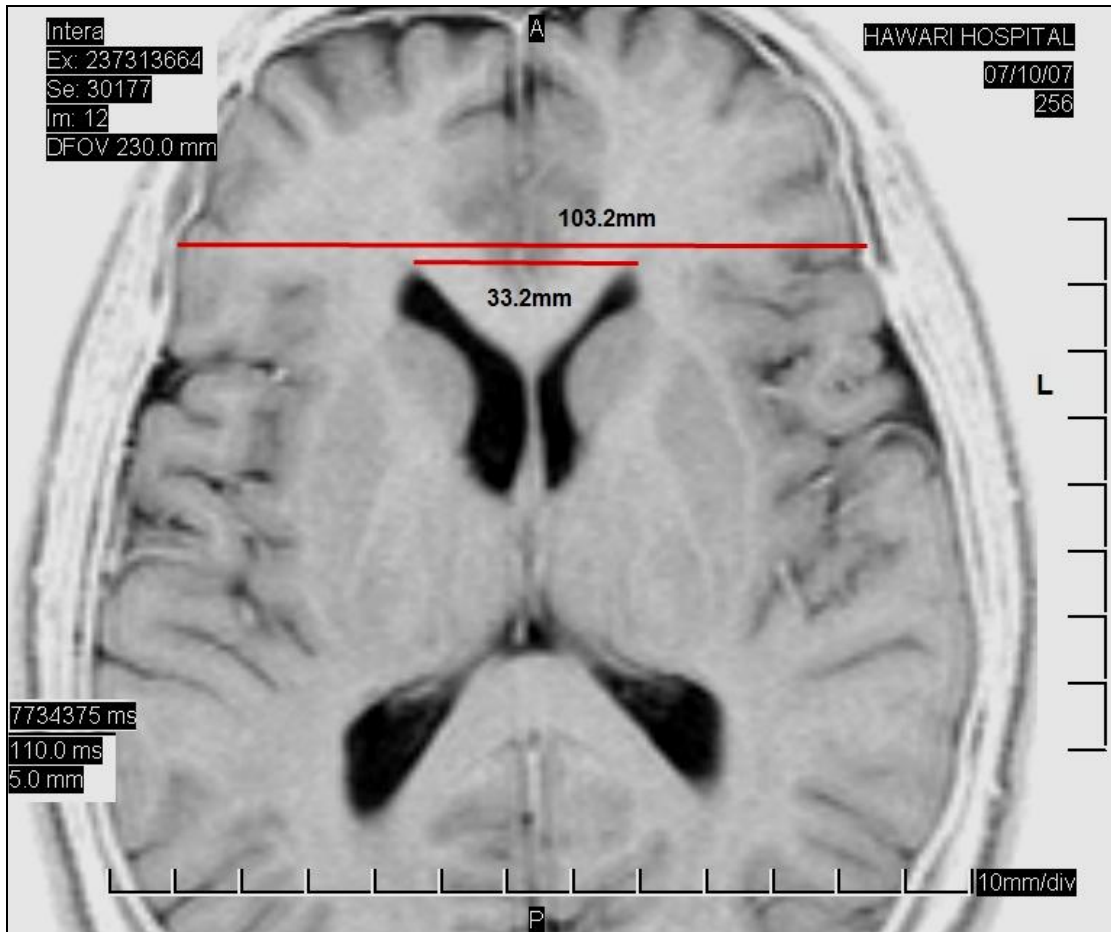


**Fig. 60.** T2 MR Image of axial plane of the brain at the level of the head of caudate nucleus of a female subject showing the calculation of Evans' index.

---

**RESULTS**

---

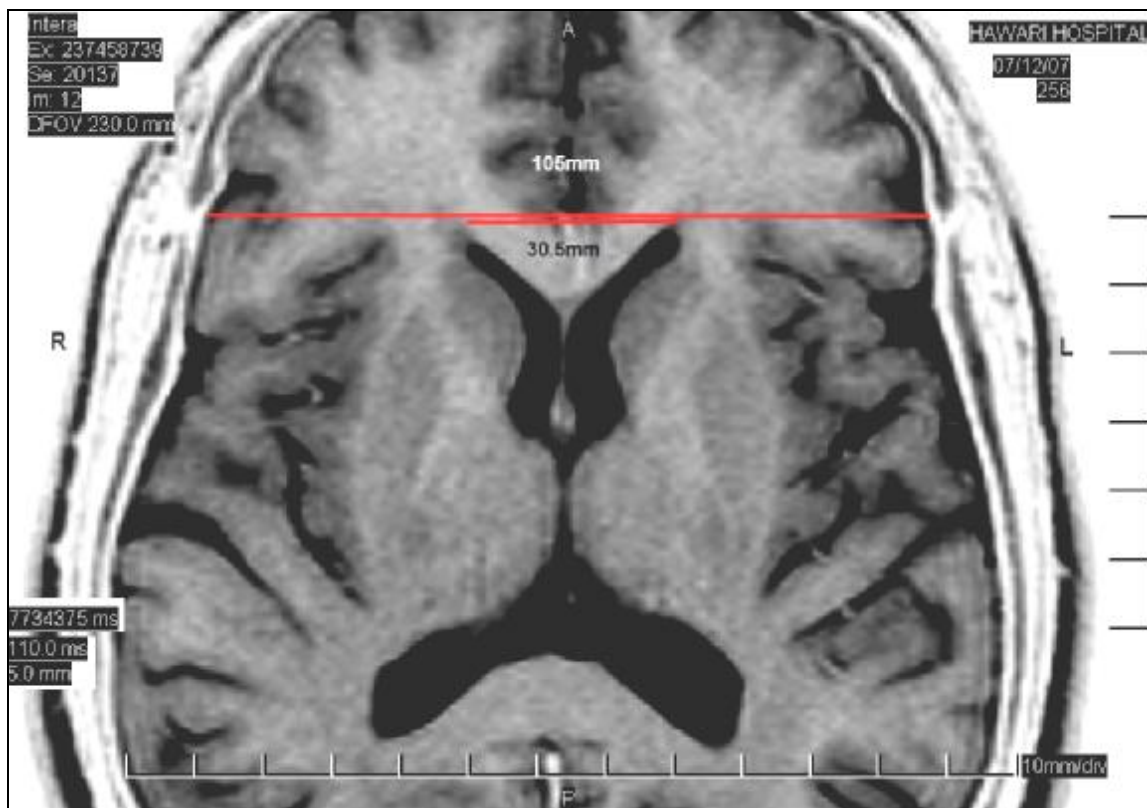


**Fig. 61.** T2 MR Image of axial plane of the brain at the level of the head of caudate nucleus of a female subject showing the calculation of Evans' index.

---

**RESULTS**

---



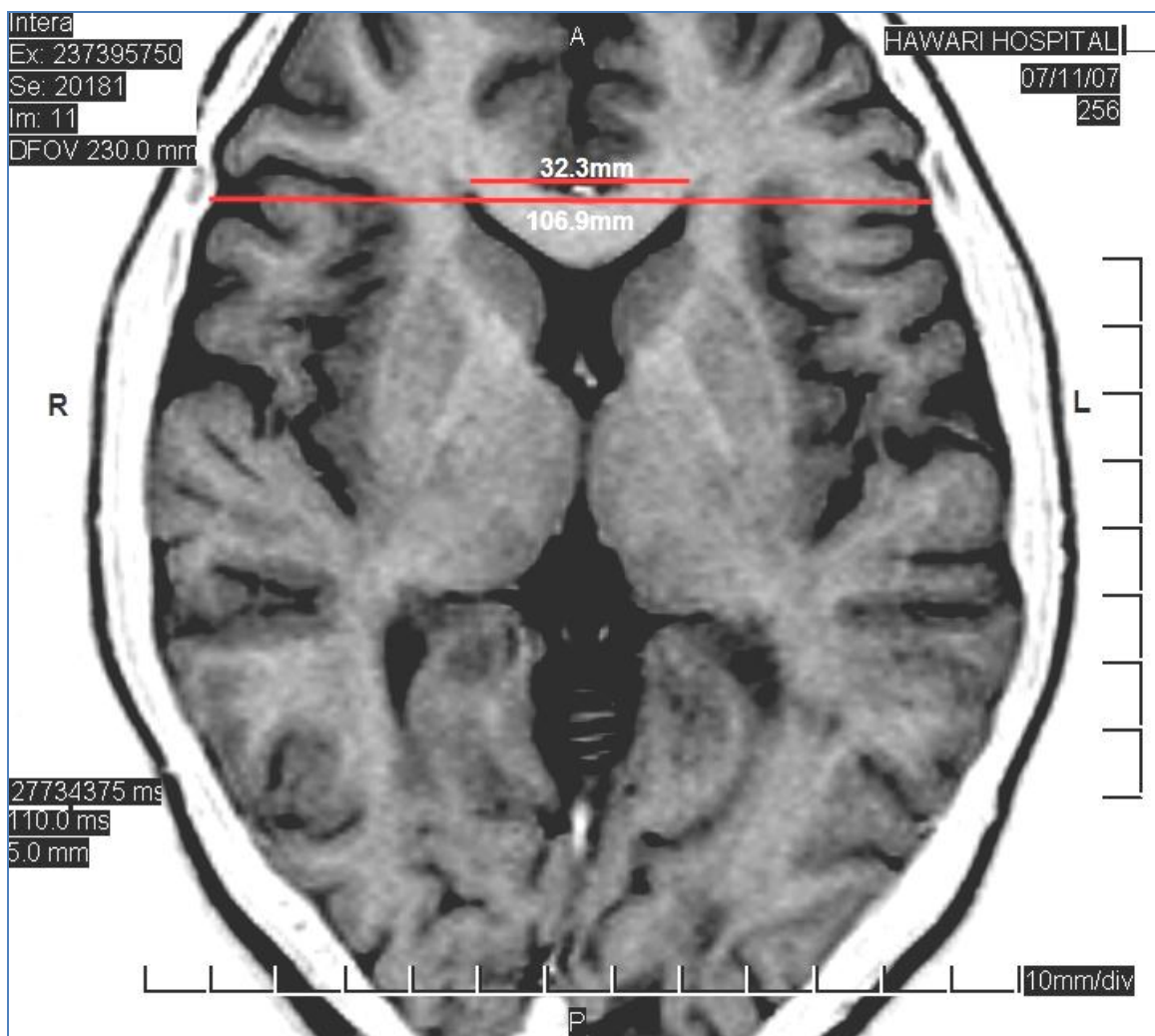**Fig. 62.** T2 MR Image of axial plane of the brain at the level of the head of caudate nucleus of a female subject showing the calculation of Evans' index.

---



**RESULTS**

---

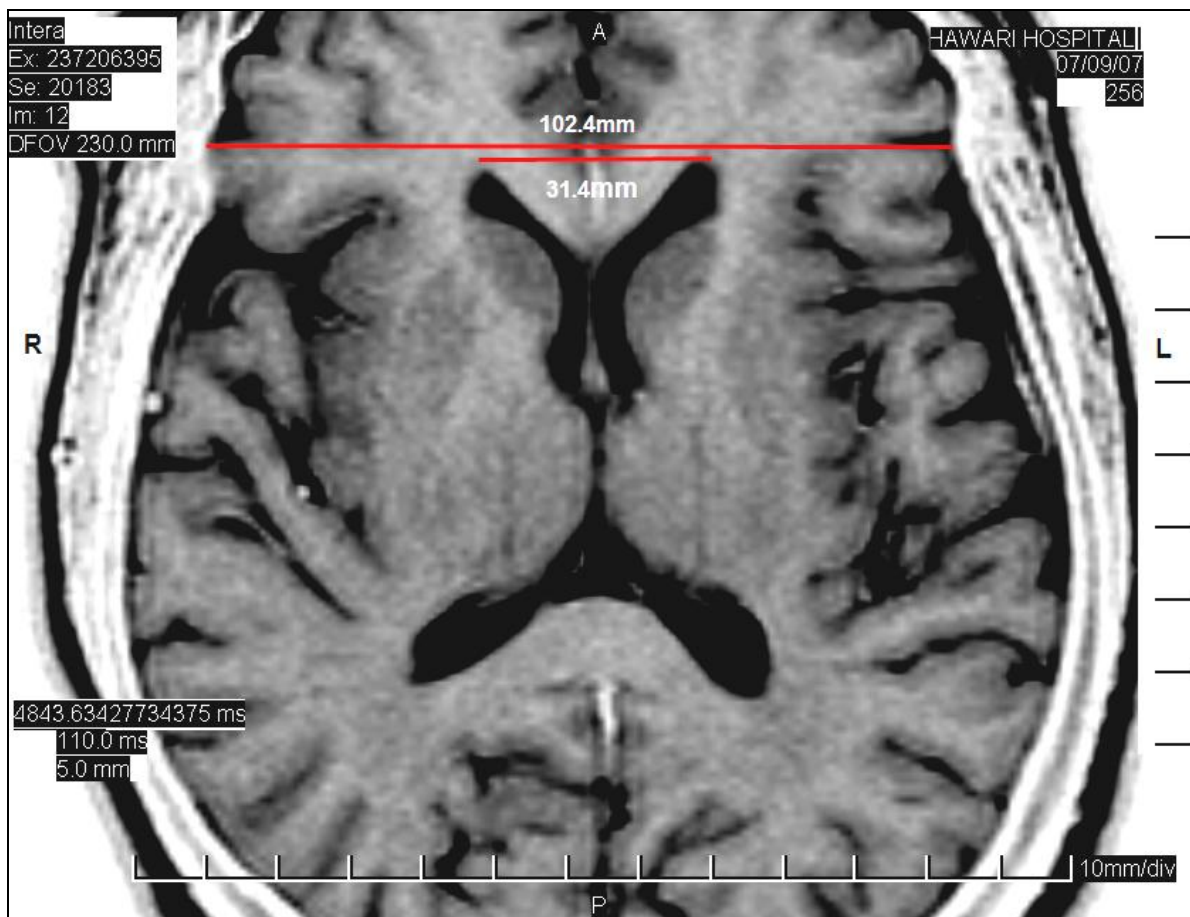


**Fig. 63.** T2 MR Image of axial plane of the brain at the level of the head of caudate nucleus of a female subject showing the calculation of Evans' index.

---

**RESULTS**

---



**Fig. 64.** T2 MR Image of axial plane of the brain at the level of the head of caudate nucleus of a female subject showing the calculation of the Evans' index.

---

## **B. SEX DIFFERENCES IN THE LATERAL VENTRICLE**

Comparing the parameters of the male lateral ventricle with those of the female lateral ventricle (**Table 31**) (**Charts 4, 5**) revealed significant differences in all the parameters in favor of the male. The data revealed that the cross sectional area of the male frontal horn was highly significant greater than that of the female ( $149.84 \pm 3.76$  for the male left frontal horn compared to  $130.34 \pm 4.15$  for the female left frontal horn;  $140.44 \pm 4.08$  for the male right frontal horn compared to  $122.54 \pm 4.13$  for the female right frontal horn). The cross sectional area of the male trigone was significantly greater than that of the female ( $193.76 \pm 4.36$  for the male left trigone compared to  $168.87 \pm 4.19$  for the female left trigone;  $183.25 \pm 3.69$  for the male right trigone compared to  $169.19 \pm 4.04$  for the female right trigone). The cross sectional area of the male temporal horn was highly significant greater than that of the female ( $26.26 \pm 1.09$  for the male left temporal horn compared to  $20.52 \pm 1.04$  for the female left temporal horn;  $23.87 \pm 1.05$  for the male right temporal horn compared to  $17.97 \pm 0.95$  for the female right temporal horn). The V/H Index of the male lateral ventricle was highly significant greater than that of the female ( $0.261 \pm 2.93$  for the male left V/H Index compared to  $0.258 \pm 3.29$  for the female left V/H Index;  $0.265 \pm 3.11$  for the male right V/H Index compared to  $0.244 \pm 3.95$  for the female right V/H Index). Evans' Index of the male lateral ventricle was highly significant greater than that of the female ( $0.292 \pm 2.1$  for the male compared to  $0.279 \pm 1.87$  for the female Evans' Index).

---

---

**RESULTS**

---

**Table 31:** Sex differences between the different parameters of the lateral ventricle. The values of the male are significantly greater than those of the female

THE PARAMETER	No.	SEX	MEAN	SD	SEM
LT. FRONTAL HORN	M**	79	149.8418	33.4333	3.7615
	F	78	130.3382	36.6169	4.1460
RT. FRONTAL HORN	M**	79	140.44	36.5358	4.0848
	F	78	122.5397	36.4410	4.1261
LT. TRIGONE	M**	79	193.7633	38.7696	4.3619
	F	79	168.8667	37.2796	4.1943
RT. TRIGONE	M*	79	183.2456	32.7894	3.6891
	F	79	169.1924	35.9296	4.0424
LT. TEMPORAL HORN	M**	78	26.1615	9.5976	1.0867
	F	78	20.5179	9.1937	1.0410
RT. TEMPORAL HORN	M**	78	23.8667	9.2407	1.0463
	F	77	17.9675	8.3261	0.9488
LT. VH INDEX	M**	79	0.271330	2.601	2.93
	F	80	0.258288	2.93901	3.29
RT. VH INDEX	M**	79	0.265423	2.76536	3.11
	F	80	0.244119	3.5298	3.95
EVANIS INDEX	M**	79	0.29183	1.8669	2.10
	F	80	0.27869	1.6720	1.87

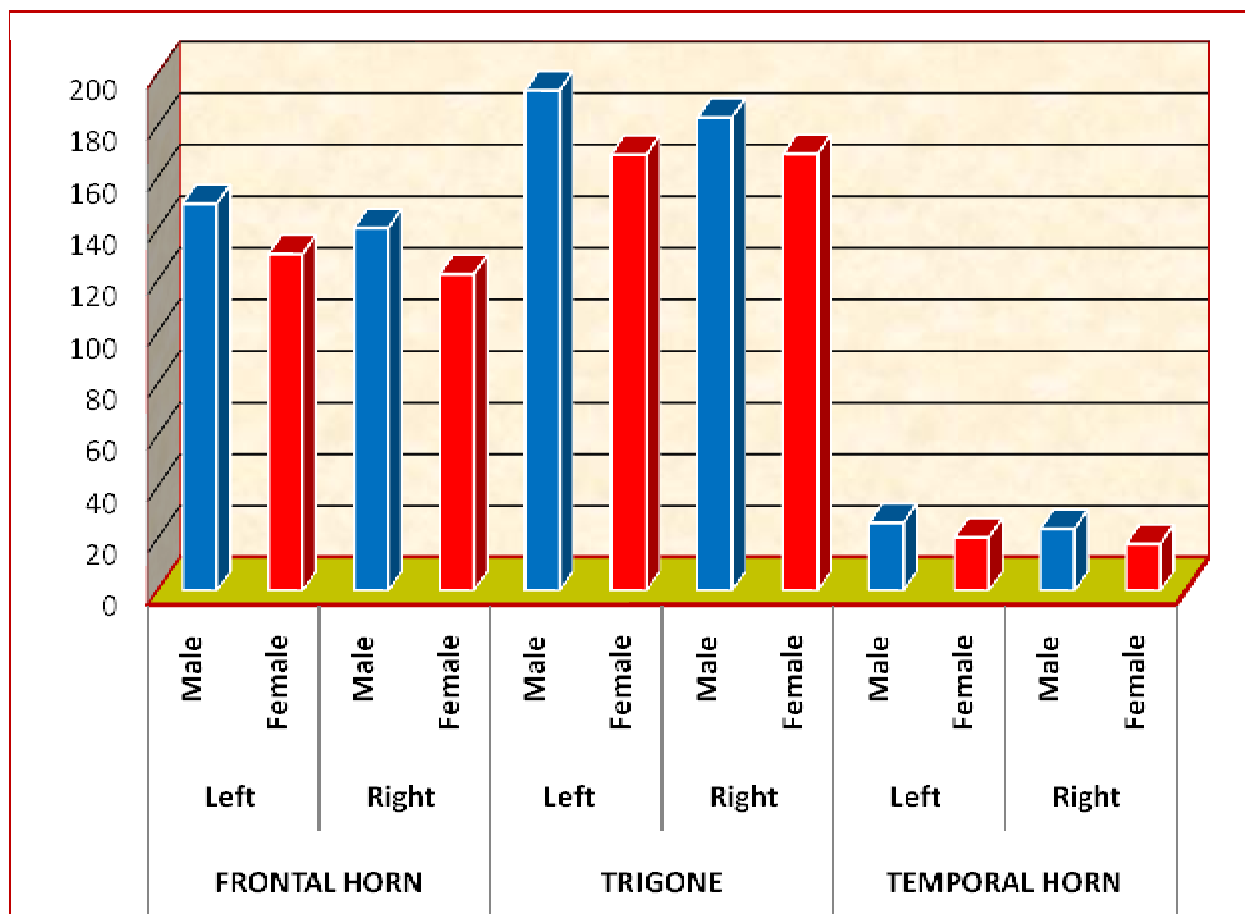
\* = significant

\*\* = highly significant

---

**RESULTS**

---

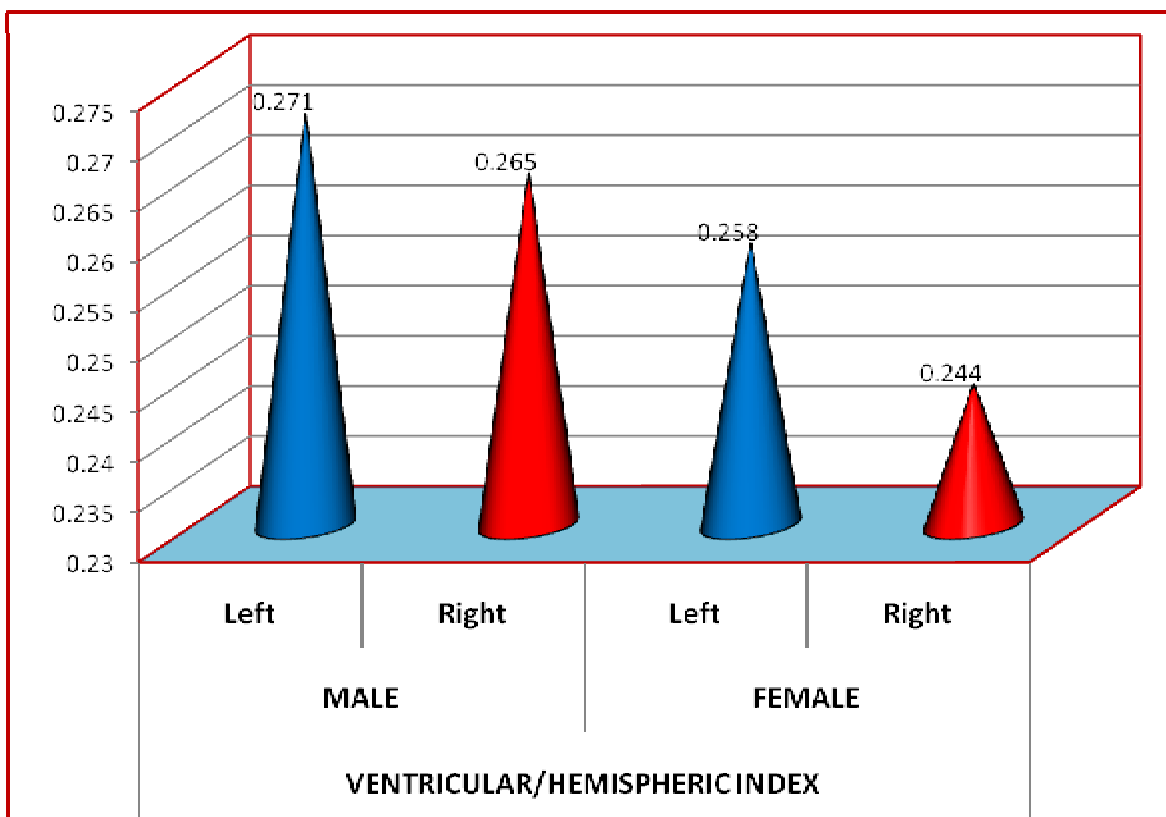


**CHART 4: SEX DIFFERENCES IN THE CROSS SECTIONAL AREA OF THE DIFFERENT PARTS OF THE LATERAL VENTRICLE**

---

**RESULTS**

---



**CHART 5: SEX DIFFERENCES IN THE VENTRICULAR/HEMISPHERIC INDEX OF THE LATERAL VENTRICLE**

---

## **C. AGE CHANGES IN THE LATERAL VENTRICLE**

The subjects were divided into two age groups: **Group I**: 20 – 40 years and **Group II**: 40 - 60 years. In both males and females, morphometric analysis of the lateral ventricle showed significant increase in all the parameters of the lateral ventricle with age (**Tables 32, 33, 34, 35**).

### **AGE CHANGES IN THE MALES (Tables 32, 35) (Charts 6, 7):**

The **left frontal horn** showed 5.3% significant increase in the cross sectional area of Group II.

The **right frontal horn** showed 11.4% significant increase in the cross sectional area of Group II.

The **left trigone** showed 10.7% significant increase in the cross sectional area of group II.

The **right trigone** showed 11.7% significant increase in the cross sectional area of group II.

The **left temporal horn** showed 2.9% significant increase in the cross sectional area of group II.

The **right temporal horn** showed 4% significant increase in the cross sectional area of group II.

The **left V/H index** showed 6.5% significant increase in group II.

The **right V/H index** showed 3.8% significant increase in group II.

The **VI** showed 3.7% significant increase in group II.

---

---

**RESULTS**

---

**TABLE 32: Group statistics of the parameters of the lateral ventricles of the male subjects.**

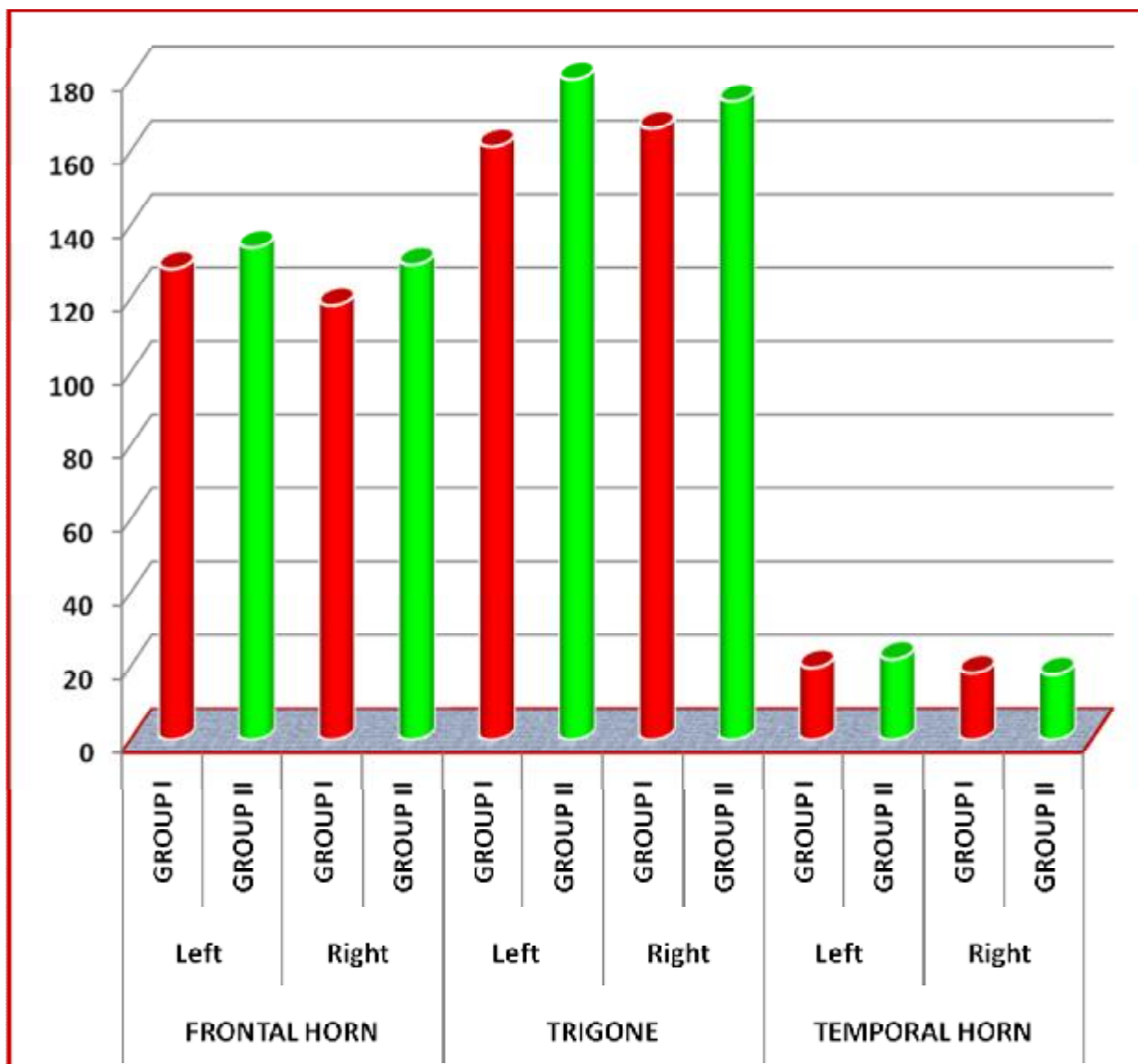
PARAMETER	AGE GROUP	NO.	MEAN	SD	SEM
LT. FRONTAL HORN	I: 20 - 40	42	146.181	32.9859	5.0898
	II: 40 - 60	37	153.997	33.9013	5.5733
RT. FRONTAL HORN	I: 20 - 40	43	133.974	34.0479	5.1923
	II: 40 - 60	37	149.249	38.0516	6.3556
LT. TRIGONE	I: 20 - 40	42	184.502	36.9543	5.7022
	II: 40 - 60	37	204.276	38.5713	6.3411
RT. TRIGONE	I: 20 - 40	42	173.674	28.4861	4.3955
	II: 40 - 60	37	194.111	34.3090	5.6404
LT. TEMPORAL HORN	I: 20 - 40	41	25.812	9.5930	1.4982
	II: 40 - 60	37	26.549	9.7200	1.5980
RT. TEMPORAL HORN	I: 20 - 40	41	23.427	9.6215	1.5026
	II: 40 - 60	37	24.354	8.9060	1.4641
LT. V/H INDEX	I: 20 - 40	42	0.263	2.10869	3.25
	II: 40 - 60	37	0.280	2.8274	4.65
RT. V/H INDEX	I: 20 - 40	42	0.261	2.15966	3.33
	II: 40 - 60	37	0.271	3.27301	5.38
EVANS' INDEX (VI)	I: 20 - 40	43	0.296	1.7329	2.64
	II: 40 - 60	36	0.307	1.877	3.13

---



**RESULTS**

---

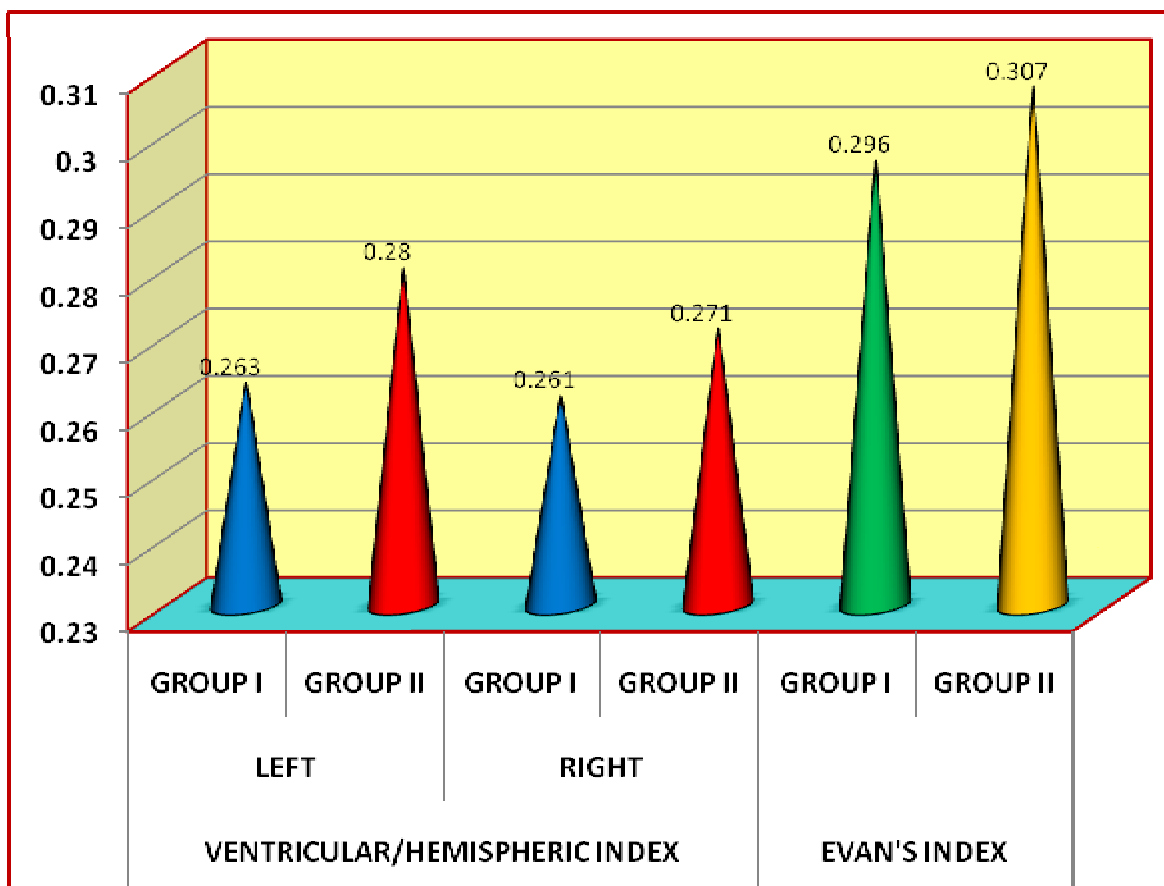


**CHART 6: AGE CHANGERS IN THE CROSS SECTIONAL AREA OF THE DIFFERENT PARTS OF THE MALE LATERAL VENTRICLE**

---

**RESULTS**

---



**CHART 7: AGE CHANGERS IN THE VENTRICULAR/HEMISPHERIC INDEX AND EVANS' INDEX OF THE MALE LATERAL VENTRICLE**

---

**AGE CHANGES IN THE FEMALES (Tables 33, 35) (Charts 8, 9):**

The **left frontal horn** showed 4.5% significant increase in the cross sectional area of Group II.

The **right frontal horn** showed 9.4% significant increase in the cross sectional area of Group II.

The **left trigone** showed 11.4% significant increase in the cross sectional area of group II.

The **right trigone** showed 4.5% significant increase in the cross sectional area of group II.

The **left temporal horn** showed 11.5% significant increase in the cross sectional area of group II.

The **right temporal horn** showed 2.4% significant decrease in the cross sectional area of group II.

The **left V/H index** showed 1.7% significant increase in group II.

The **right V/H index** showed 3.2% significant decrease in group II.

The **VI** showed 1.5% significant decrease in group II.

---

---

---

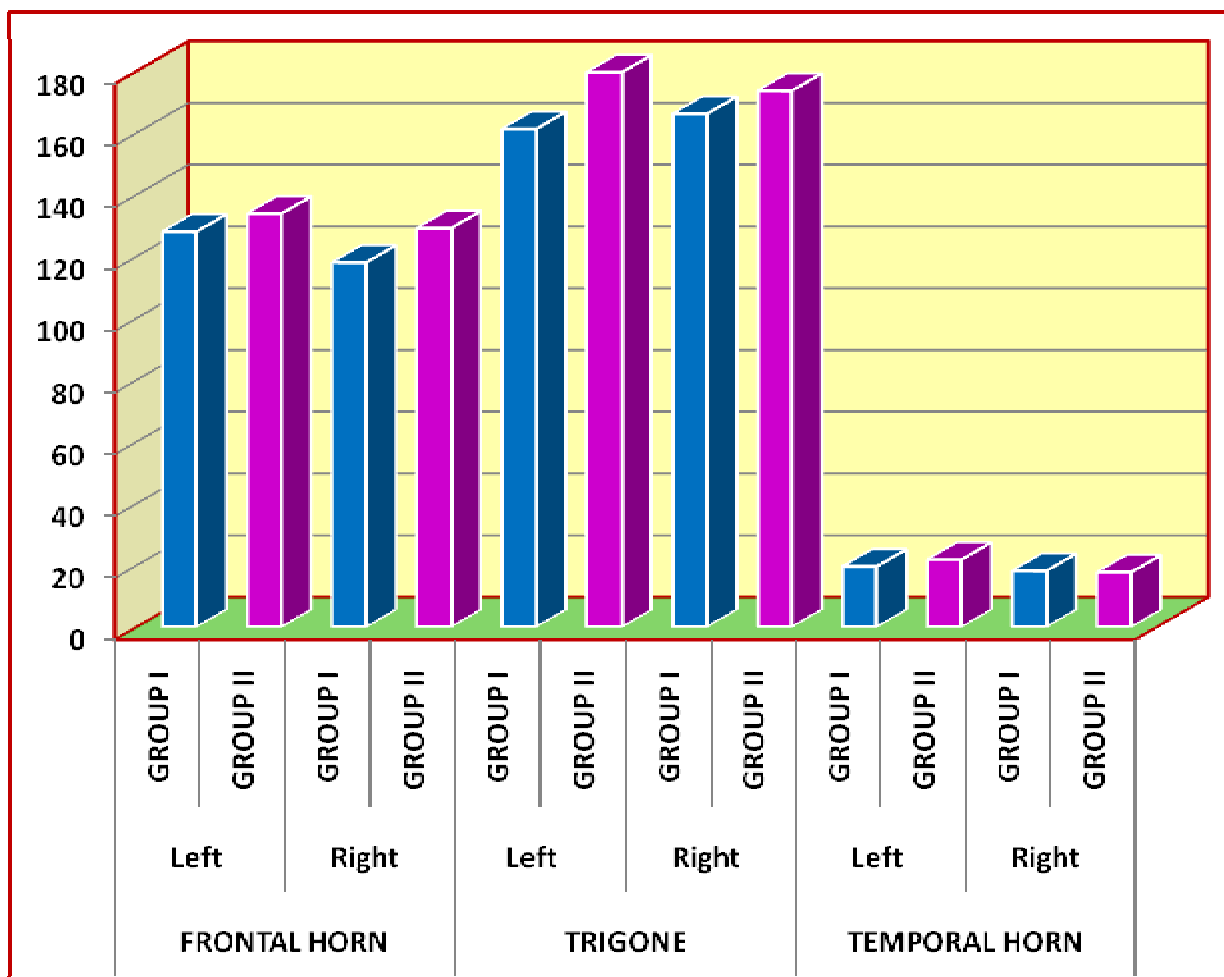
**RESULTS****TABLE 33: Group statistics of the parameters of the lateral ventricles of the female subjects.**

<b>THE PARAMETER</b>	<b>AGE GROUP</b>	<b>NO.</b>	<b>MEAN</b>	<b>SD</b>	<b>SEM</b>
<b>LT. FRONTAL HORN</b>	<b>I: 20 - 40</b>	<b>46</b>	<b>127.9565</b>	<b>39.0537</b>	<b>5.7582</b>
	<b>II: 40 - 60</b>	<b>32</b>	<b>133.7619</b>	<b>33.1038</b>	<b>5.8520</b>
<b>RT. FRONTAL HORN</b>	<b>I: 20 - 40</b>	<b>46</b>	<b>117.9935</b>	<b>35.3919</b>	<b>5.2182</b>
	<b>II: 40 - 60</b>	<b>32</b>	<b>129.0750</b>	<b>37.4890</b>	<b>6.6272</b>
<b>LT. TRIGONE</b>	<b>I: 20 - 40</b>	<b>46</b>	<b>161.1891</b>	<b>33.7332</b>	<b>4.9737</b>
	<b>II: 40 - 60</b>	<b>33</b>	<b>179.5688</b>	<b>39.8058</b>	<b>6.9293</b>
<b>RT. TRIGONE</b>	<b>I: 20 - 40</b>	<b>46</b>	<b>166.0870</b>	<b>36.7012</b>	<b>5.4113</b>
	<b>II: 40 - 60</b>	<b>33</b>	<b>173.5212</b>	<b>34.9181</b>	<b>6.0785</b>
<b>LT. TEMPORAL HORN</b>	<b>I: 20 - 40</b>	<b>45</b>	<b>19.5689</b>	<b>8.9620</b>	<b>1.3360</b>
	<b>II: 40 - 60</b>	<b>33</b>	<b>21.8121</b>	<b>9.4844</b>	<b>1.6510</b>
<b>RT. TEMPORAL HORN</b>	<b>I: 20 - 40</b>	<b>44</b>	<b>18.1523</b>	<b>8.5139</b>	<b>1.2835</b>
	<b>II: 40 - 60</b>	<b>33</b>	<b>17.7212</b>	<b>8.1933</b>	<b>1.4263</b>
<b>LT. V/H INDEX</b>	<b>I: 20 - 40</b>	<b>46</b>	<b>0.256478</b>	<b>2.57352</b>	<b>3.79</b>
	<b>II: 40 - 60</b>	<b>34</b>	<b>0.260735</b>	<b>3.39700</b>	<b>5.83</b>
<b>RT. V/H INDEX</b>	<b>I: 20 - 40</b>	<b>46</b>	<b>0.247446</b>	<b>2.50058</b>	<b>3.69</b>
	<b>II: 40 - 60</b>	<b>34</b>	<b>0.239618</b>	<b>4.57576</b>	<b>7.85</b>
<b>EVANS' INDEX</b>	<b>I: 20 - 40</b>	<b>46</b>	<b>0.29054</b>	<b>1.6872</b>	<b>2.49</b>
	<b>II: 40 - 60</b>	<b>34</b>	<b>0.28618</b>	<b>1.6425</b>	<b>2.82</b>

---

**RESULTS**

---

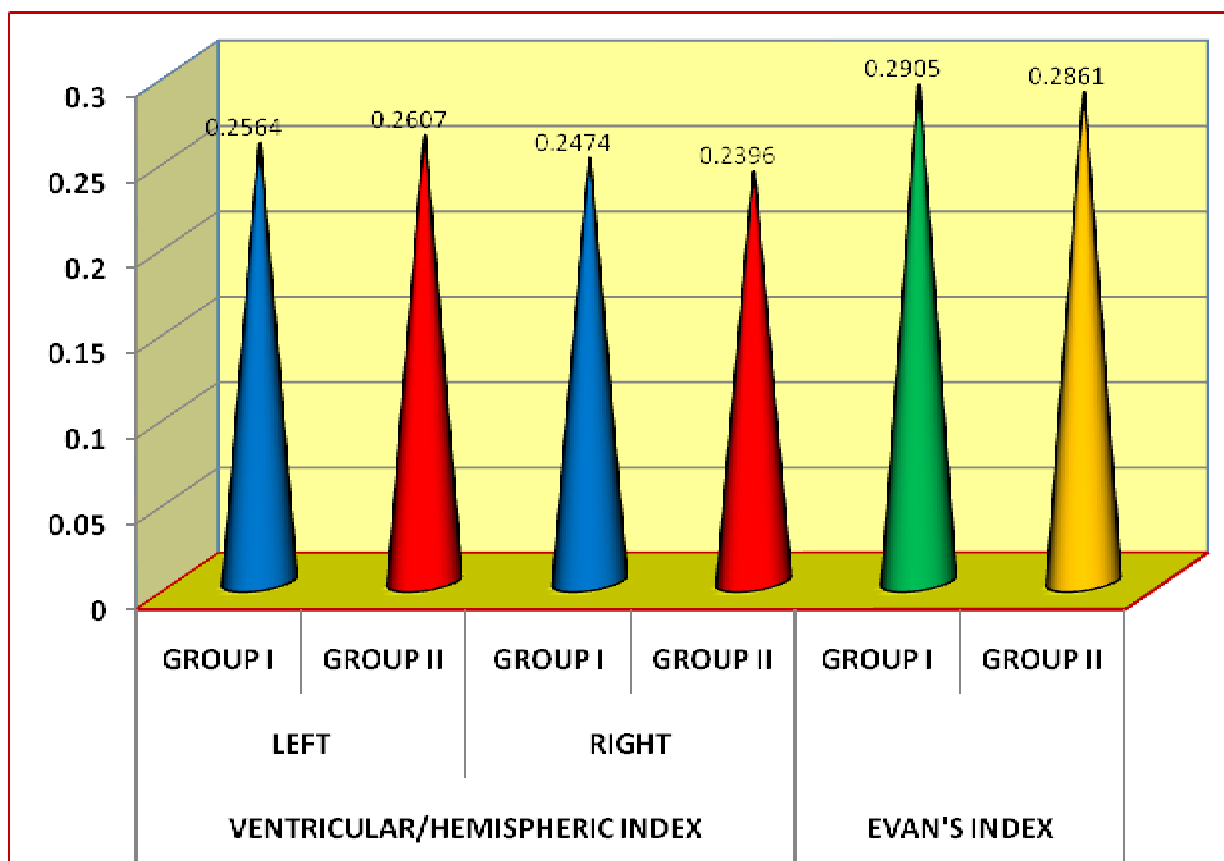


**CHART 8: AGE CHANGERS IN THE CROSS SECTIONAL AREA OF THE DIFFERENT PARTS OF THE FEMALE LATERAL VENTRICLE**

---

**RESULTS**

---



**CHART 9: AGE CHANGERS IN THE VENTRICULAR/HEMISPHERIC INDEX AND EVANS' INDEX OF THE FEMALE LATERAL VENTRICLE**

---

**AGE CHANGES IN THE TOTAL NUMBER OF THE SUBJECTS (Tables 34, 35):**

The **left frontal horn** showed 5.8% significant increase in the cross sectional area of Group II.

The **right frontal horn** showed 11.3% significant increase in the cross sectional area of Group II.

The **left trigone** showed 11.8% significant increase in the cross sectional area of group II.

The **right trigone** showed 8.7% significant increase in the cross sectional area of group II.

The **left temporal horn** showed 7.9% significant increase in the cross sectional area of group II.

The **right temporal horn** showed 2.6% significant increase in the cross sectional area of group II.

The **left V/H index** showed 4.3% significant increase in group II.

The **right V/H index** showed 0.8% significant increase in group II.

The **VI** showed 1.2% significant increase in group II.

---

---

**RESULTS**

---

**TABLE 34: Group statistics of the parameters of the lateral ventricles of all subjects.**

THE PARAMETER	AGE GROUP	NO.	MEAN	SD	SEM
LT. FRONTAL HORN	I: 20 - 40	88	136.6545	37.2219	3.9679
	II: 40 - 60	69	144.6128	34.8046	4.1900
RT. FRONTAL HORN	I: 20 - 40	89	125.7146	35.4727	3.7601
	II: 40 - 60	69	139.8928	38.8581	4.6780
LT. TRIGONE	I: 20 - 40	88	172.3159	37.0041	3.9447
	II: 40 - 60	70	192.6281	40.8090	4.8776
RT. TRIGONE	I: 20 - 40	88	169.7080	33.0704	3.5253
	II: 40 - 60	70	184.4043	35.8716	4.2875
LT. TEMPORAL HORN	I: 20 - 40	86	22.5453	9.7325	1.0495
	II: 40 - 60	70	24.3157	9.8327	1.1752
RT. TEMPORAL HORN	I: 20 - 40	85	20.6965	9.3925	1.0188
	II: 40 - 60	70	21.2271	9.1454	1.0931
LT. V/H INDEX	I: 20 - 40	88	0.259739	2.37465	2.53
	II: 40 - 60	71	0.271001	3.24556	3.85
RT. V/H INDEX	I: 20 - 40	88	0.253794	2.42462	2.58
	II: 40 - 60	71	0.255831	4.22256	5.01
EVANS' INDEX	I: 20 - 40	89	0.29324	1.7227	1.83
	II: 40 - 60	70	0.29680	2.0393	2.44

---



---

**RESULTS**

---

**TABLE 35: Summary of the age increase in the mean parameters of the lateral ventricle in the males, females and in the total number of the cases.**

<b>THE PARAMETER</b>	<b>MALES</b>	<b>FEMALES</b>	<b>TOTAL SUBJECTS</b>
<b>LT. FRONTAL HORN:</b>	<b>+ 5.3%</b>	<b>+ 4.5%</b>	<b>+ 5.8%</b>
<b>RT. FRONTAL HORN:</b>	<b>+ 11.4%</b>	<b>+ 9.4%</b>	<b>+ 11.3%</b>
<b>LT. TRIGONE:</b>	<b>+ 10.7%</b>	<b>+ 11.4%</b>	<b>+ 11.8%</b>
<b>RT. TRIGONE:</b>	<b>+ 11.7%</b>	<b>+ 4.5%</b>	<b>+ 8.7%</b>
<b>LT. TEMPORAL HORN:</b>	<b>+ 2.9%</b>	<b>+ 11.5%</b>	<b>+ 7.9%</b>
<b>RT. TEMPORAL HORN:</b>	<b>+ 4.0%</b>	<b>- 2.4%</b>	<b>+ 2.6%</b>
<b>LT. V/H INDEX:</b>	<b>+ 6.5%</b>	<b>+ 1.7%</b>	<b>+ 4.3%</b>
<b>RT. V/H INDEX:</b>	<b>+ 3.8%</b>	<b>- 3.2%</b>	<b>+ 0.8%</b>
<b>EVANS' INDEX:</b>	<b>+ 3.7%</b>	<b>- 1.5%</b>	<b>+ 1.2%</b>

---

# DISCUSSION

It is well known that individuals vary considerably in brain volume, cytology, distribution of grey and white matter and in ventricular sizes (**Meyer, 1971**). Each ventricle contains a choroid plexus that produces CSF that bathes and cushions the brain and the spinal cord. Evaluation of the volume and measurements of the cerebral ventricle is important to know the normal variations of the ventricular parameters and to follow up the evolution of the hydrocephalus or other neurological diseases that may cause variations in the ventricular parameters and to define therapeutic conducts as the placement of ventricular valves or other invasive methods (**Lombroso et al., 1968; Hobar et al., 1983; Hilpert et al., 1995; Kodama et al., 2002; Garel & Alberti, 2006**). Awareness of these normal anatomical ventricular asymmetries as demonstrated in the MR images is very important to both radiologists and anatomists to be familiar with the normal brain asymmetry as an expression of asymmetrical brain development and to avoid any erroneous diagnosis of any brain lesion.

The cerebral ventricular system in man occupies a mean volume of approximately 20 ml, varying from 10 to 50 ml. The lateral ventricles represent about 90% of the total ventricular system volume (**Nolte, 1993**). Several pathological conditions as the processes of expansible

---

intracranial masses, the meningo-ventricular infections and the intraventricular hemorrhage can cause alterations of the ventricular volume (**Berman & Banker, 1966; Boasquevisque et al., 2000**).

The CT and the MRI techniques are the commonly used methods in the evaluation of CNS diseases including abnormalities in the ventricular system (**Degreef et al., 1992; Buchsbaum et al., 1997; Chudgar, 1999; Bernasconi et al., 2000; Dale et al., 2000; Brambilla et al., 2001; Levine et al., 2002; Duffner et al., 2003**). Several investigators have studied the cerebral ventricles quantitatively (**Gyldensted, 1977; DeCarli et al., 1992a & 1992b; Kramer et al., 1997; Hauser et al., 2000; Melhem et al., 2000; Sullivan et al., 2002; Jamous et al., 2003; Lewis et al., 2009**). However, the methods and the equipments used for the morphometric measurements and data obtained for analysis are controversial in the literature (**Meese et al., 1980; McGahan & Phillips, 1983; Blumhagen & Mack, 1985; Shackelford, 1986; Jernigan et al., 1990; Riccabona et al., 1995**).

In the present investigation, the normal quantitative values of the different parts of the human lateral ventricle were presented to create a standard morphometric database of the cerebral ventricle in a normal Libyan population, to compare the parameters of the right and left lateral ventricles in both males and females and to study the sex differences & age changes in the lateral ventricle from age of 20 years to age of 60 years. This database can be used as a guideline and as a reference for MRI diagnosis of different neurological diseases.

---

The results of the present study revealed that the cross sectional area, the ventricular hemispheric index and the ventricular index of the left lateral ventricle are significantly higher than those of the right lateral ventricle with the exception of the cross sectional area of the trigone in the female which showed no significant difference between the two sides. The ventricular index appeared within the normal standard range (0.24 - 0.31). **Brunberg et al. (2002)** defined Evans' Index as a measure of ventricular size and averaged 0.28 (range, 0.24 – 0.31) for normal adult brain.

In the present investigation, comparing the parameters of the male lateral ventricle with those of the female lateral ventricle revealed significant differences in all the parameters in favor of the male. The data revealed also that the cross sectional area of the male frontal horn, the cross sectional area of the male trigone and the cross sectional area of the male temporal horn were highly significant greater than those of the female. The ventricular hemispheric index of the male lateral ventricle was highly significant greater than that of the female. Evans' Index of the male lateral ventricle was highly significant greater than that of the female. In both males and females, morphometric analysis of the lateral ventricle showed significant increase in all the parameters with age.

The significant higher value of the left ventricular hemispheric index is correlated with the significant higher value of the cross sectional area of the left frontal horn. This may reflect a corresponding increase in the size of the left cerebral hemisphere than the right hemisphere. Taking

---

into the consideration that the left cerebral hemisphere is the dominant hemisphere in most individuals, this result may indicate a larger size of the dominant hemisphere than the non-dominant hemisphere. This suggestion needs further morphometric study on the parameters of the cerebral hemisphere.

In agreement with the present results, several investigators have reported similar observations. **Haug (1977)** studied several parameters of the normal ventricular size from 170 computed tomographic scans of patients with normal neurological findings and the analysis showed that the male subjects showed larger parameters than the females, and these parameters increased with age. **Gyldensted (1977)** found that the left lateral ventricle was larger than the right in both sexes, both lateral ventricles were larger in the male and there was a statistically significant increase of all cerebral parameters with age. **Hirashima et al. (1983)** found that the size of the ventricular system in 198 normal cases increased steadily with age. Moreover, **Saliba et al. (1990)** found that in 87 preterm infants, measurements of Lateral ventricle area and head circumference increased as age increased. Moreover, similar results were reported by **Voigt and Bockenheimer (1978)** and **Pedersen et al. (1979)** who found that the width of the left anterior horn and size of the skull were larger in boys and that Evans' ratio was larger in the younger group than in the older group. On the other hand, **Shapiro et al. (1986)** found no apparent correlation between the normal cerebral asymmetry and the sex of the patient.

---

Several studies support the present results of an asymmetry favoring an increased size of the left compared to the right lateral cerebral ventricle (**Gyldensted, 1977; Shenton et al., 1991; Ichihashi et al., 2002**). **Sener (1992)** reported that the left ventricles are larger than the right, and concluded that measurements of the size of the lateral cerebral ventricles provide useful indices of cerebral asymmetry and atrophy. Moreover, frontal horn asymmetry is a common occurrence without clear pathologic basis. Several correlates have been tested, including the patient's left- or right-handedness and age. However, the mechanism that leads to this asymmetry still remains conjectural, and the range of acceptable asymmetry is unknown. Asymmetry of the lateral ventricles and frontal horns may simulate unilateral hydrocephalus. Therefore, it is important to rule out an intraventricular or periventricular structural abnormality. **Baj (2002)** reported that asymmetry of the frontal horns can be considered a normal variant as long as no discernible parenchymal or intraventricular abnormality is present.

From the results of the present study and the results of the previous investigations, it appears that asymmetry of the ventricles of the brain without an obvious cause is a common and intriguing radiologic finding. **LeMay (1976)** described cerebral asymmetries in the form of longer left sylvian fissure than the right, wider the left occipital pole than the right and longer left lateral ventricle than the right. **Galaburda et al. (1978)** suggested that the differences between the hemispheres may relate to right-left differences in function and that the striking auditory

---

---

asymmetries could underlie language lateralization. The asymmetries in the frontal and occipital lobes and the lateral ventricles are correlated with hand preference. **Grosman et al. (1990)** reported that asymmetry of the lateral ventricles of the brain is a relatively common CT finding that has important clinical and brain structural correlates and deserves more attention in the field of imaging.

Studying the measurements of the lateral ventricles of the different age groups, the present investigation showed that the parameters of the lateral ventricle of both males and females significantly increased with age. **Celik et al. (1995)** examined 100 CT cases with no physical or neurological deficits and found that the sizes of the cerebral ventricles increased with age in both sexes. **Mu et al. (1999)** defined the range of normal size for the temporal horn of the lateral ventricle in different age groups ranging from 40 to 90 years. They concluded that difference in the mean value of standardized size of the temporal horn corresponds to difference in age among healthy subjects. **Sullivan et al. (2002)** compared rates of age-related size change in the lateral ventricles and found that annual rate of ventricular expansion was significant.

The reasons for variations in the brain structure are still unclear. **Baaré et al. (2001)** reported that the degree to which individual variation in brain structure in humans is genetically or environmentally determined is yet not well understood. Genetic factors accounted for most of the individual differences in whole brain. Individual differences in lateral ventricle volume may be explained by environmental factors. **Ichihashi et al. (2002)** studied the effect of head position as a cause of asymmetry

---

of the lateral ventricles in neonates and they found that the left ventricular size was larger than the right one. The difference of the left and right ventricular sizes was partially affected by head position. The ratio of left to right lateral ventricular sizes showed a very wide distribution. They considered that ventricular asymmetry is not pathological, but due to individual differences. More recently, **Ichihashi et al. (2005)** found that the lateral ventricular size became larger during the first two weeks after birth and that the left ventricle was larger than the right one.

It is concluded in this investigation that asymmetry of the lateral ventricle exists in both males and females and that the left lateral ventricle is significantly larger than the right and the male lateral ventricle is significantly larger than that of the female. To our knowledge, this investigation is the first morphometric study that determines the different parameters of the lateral ventricle in a Libyan population and it shows the basic standard values of the dimensions of the lateral ventricle and can be used as a guide for diagnosis of many neurological diseases that may alter these dimensions. The present study also provides a tool to measure 2D parameters of the cerebral lateral ventricles; it is a simple and reproducible method and can be performed routinely in the neuro-radiological field to aid in diagnosis of different pathological conditions that may cause ventricular enlargement.

---



# SUMMARY

The assessment of the measurement of the cerebral ventricles becomes important to follow the evolution of the hydrocephaly or other neurological diseases and to define therapeutic conducts such as the placement of ventricular valves.

The present MR imaging-based morphometric study was carried out to define the normal quantitative values of the different parts of the human lateral ventricle to create a standard morphometric database of the cerebral ventricle in a normal Libyan population. It is also intended to compare the parameters of the right and left lateral ventricles in both males and females and to study the sex differences and age changes in the lateral ventricle from age of 20 to 60 years. This database can be used as a guideline and as a reference for MRI diagnosis of different neurological diseases.

A total of 160 male and female neurologically healthy Libyan individuals (80 men and 80 women) of age 20 - 60 years were used in this study. They were drawn from a Benghazi community and were referred to the MRI unit for different reasons other than neurological disorders. They underwent a medical interview to exclude notable neurologic or psychiatric illnesses. Persons who reported history of cardiovascular, neurological or psychiatric conditions, head trauma with loss of consciousness, thyroid problems and diabetes were excluded. They were subjected to MR imaging of the lateral ventricle

at coronal and axial planes, after taking their consent, at Benghazi Radiodiagnosis and Radiotherapy Center.

Planimetric measures of the lateral ventricle were performed. The margins of the frontal horn, trigone and the temporal horn of both sides were outlined manually on the corresponding axial MR sections. The cross sectional areas were calculated and expressed in mm<sup>2</sup> units. Evans' index (ventricular index) which is the ratio between the distance between anterior tips of the frontal horns and the bi-frontal diameter of the skull at the same level was calculated at same axial plane for all subjects. The ventricular hemispheric index (V/H index) which is the ratio between the distances from the midline to the most lateral point of the lateral ventricle to the corresponding ipsilateral hemispheric width was measured in the coronal plane at the level of the foramen of Monro for all subjects.

Statistical analysis of the male and female data of both age groups was performed using SPSS/PC Student t-test software program. Probability less than 0.05 is considered significant.

The results revealed that the cross sectional area of the left lateral ventricle is significantly larger than that of the right lateral ventricle with the exception of the cross sectional area of the trigone in the female which showed no significant difference between the two sides.

The ventricular index (VI) of the male, female and total subjects was within the normal range of the international standard values of the VI. The standard normal Evans' Index averaged 0.28 (range, 0.24 – 0.31) for normal adult brain. Comparing the parameters of the male lateral ventricle with those of the female lateral ventricle revealed

significant higher values in the male than in the female. The V/H Index and Evans' Index of the male lateral ventricle were significantly greater than that of the female.

The significant higher value of the left V/H index is correlated with the significant higher value of the cross sectional area of the left frontal horn. This may reflect a corresponding increase in the size of the left cerebral hemisphere than the right hemisphere. Taking into consideration that the left cerebral hemisphere is the dominant one in most individuals, this result may indicate a higher size of the dominant hemisphere than the non-dominant hemisphere. This suggestion needs further morphometric study on the parameters of the cerebral hemisphere.

In both males and females, morphometric analysis of the lateral ventricle showed significant increase in all the parameters of the lateral ventricle with age.

It is concluded in this investigation that the present results demonstrate asymmetry of the lateral ventricle between left and right side, and between male and female. To our knowledge, this investigation is the first morphometric study that determines the different parameters of the lateral ventricle and it shows the basic standard values of the dimensions of the lateral ventricle in a Libyan population and can be used as a guide for diagnosis of many neurological diseases that may alter these dimensions. The present method provides a tool to measure 2D parameters of the cerebral lateral ventricles and can be performed routinely in the neuro-radiological field to aid in diagnosis of different pathological conditions that may cause ventricular enlargement.

# REFERENCES

1. **Achiron R, Yagel S, Rotstein Z, Inbar O, Mashiach S and Lipitz S (1997):** Cerebral lateral ventricular asymmetry: is this a normal ultrasonographic finding in the fetal brain? *Obstetrics & Gynecology* 89:233 - 237.
  2. **Alagappan R Browning PD, Laorr A and McGahan JP (1994):** Distal lateral ventricular atrium: reevaluation of normal range. *Radiology*, 193(2):315 - 317.
  3. **Anderson RC, Grant JJ, Paz RDL, Frucht S and Goodman RR (2002):** Volumetric measurements in the detection of reduced ventricular volume in patients with normal-pressure hydrocephalus whose clinical condition improved after ventriculoperitoneal shunt placement. *J. Neurosurg.*, 97:73 – 79.
  4. **Baaré WF, Hulshoff HE, Boomsma DI, Posthuma D, de Geus EJ, Schnack HG, van Haren NE, van Oel CJ and Kahn RS (2001):** Quantitative Genetic Modeling of Variation in Human Brain Morphology. *Cereb. Cortex*, 11:816 - 824.
  5. **Baj M (2002):** Normal variation in asymmetric frontal horns of lateral ventricles. *AJR*, 178: 240.
  6. **Bazán-Camacho AJ, García-Almeida E and Jiménez-Valdés ML (2004):** A study of the evolution of ventricular dilatations using transfontanellar ultrasonography. *Rev. Neurol.*, 39(12):1109 - 1112.
-

## **References**

---

7. **Beats B, Levy R, and Förstl H (1991):** Ventricular enlargement and caudate hyperdensity in elderly depressives. *Biol. Psychiatry.*, 30(5):452 - 458.
  8. **Bennett GL, Bromley B, and Benacerraf BR (1996):** Agenesis of the corpus callosum: prenatal detection usually is not possible before 22 weeks of gestation. *Radiology*, 199:447 – 450.
  9. **Berg D, Maurer M, Warmuth-metz M, Rieckmann P, and Becker G (2000):** The correlation between ventricular diameter measured by transcranial sonography and clinical disability and cognitive dysfunction in patient with multiple sclerosis. *Arch Neurol.*, 57: 1289-1292.
  10. **Berman PH & Banker B (1966):** Neonatal meningitis: the clinical and pathological study of 29 cases. *Paediatrics*, 38:6 - 24.
  11. **Bernasconi N, Bernasconi A, Caramanos Z, Andermann F, Dubeau F& Arnold DL (2000):** Morphometric MRI analysis of the parahippocampal region in temporal lobe epilepsy. *Ann. NY Acad. Sci.*, 911:495 – 500.
  12. **Blatter DD, Bigler ED, Gale SD, Johnson SC, Anderson CV, Burnett BM, Parker N, Kurth S and Horn SD (1995):** Quantitative Volumetric Analysis of Brain MR: Normative Database Spanning 5 Decades of Life. *Am. J. Neuroradiol.*, 16:241 – 251.
  13. **Blumhagen JD & Mack LA (1985):** Abnormalities of the neonatal cerebral ventricles. *Radiol. Clin. N. Amer.*, 23:13 - 27.
-

## **References**

---

- 14. Boasquevisque EM, Mandarim-de-Lacerda CA, and Cerri GG (2000):** Comparison between computed tomography and ultrasonography in the cerebral ventricles morphometry, Rev. Chil. Anat. 18; 122 -127.
  - 15. Boyd JD (1955):** Some Aspects of the Early Development of the Nervous System. In: Biochemistry of the Developing Nervous System. pp: 3 - 27, Acad. Press, New York.
  - 16. Bradley KM, Bydder G M, Budge MM, Hajnal JV, White SJ, Ripley B D and Smith AD (2002):** Serial brain MRI at 3 – 6 month intervals as a surrogate marker for Alzheimer's disease. Br. J. Radiol., 75:506 - 513.
  - 17. Brambilla P, Harenski K, Nicoletti M, Mallinger AG, Frank E, Kupfer DJ, Keshavan MS & Soares JC (2001):** MRI study of posterior fossa structures and brain ventricles in bipolar patients. J. Psychiatr. Res., 35: 313 - 322.
  - 18. Brinkman SD, Sarwar M, Levin SH and Morris HH (1981):** quantitative indexes of computed tomography in dementia and normal aging. Radiology, 138: 89 - 92.
  - 19. Brunberg JA, Jacquemont S, Hagerman RJ, Jacquemont S, Hagerman RJ, Berry-Kravis EM, Grigsby J, Leehey MA, Tassone F, Ted Brown W, Greco CM and Hagerman P (2002) :** Fragile X Premutation Carriers: Characteristic MR Imaging Findings of Adult Male Patients with Progressive Cerebellar and Cognitive Dysfunction, American Journal of Neuroradiology 23:1757-1766.
-

## **References**

---

- 20. Buchsbaum MS, Yang S, Hazlett E, Siegel BV Jr, Germans M, Haznedar M, O'Flaithbheartaigh S, Wei T, Silverman J, and Siever LJ (1997):** Ventricular volume and asymmetry in schizotypal personality disorder and schizophrenia assessed with magnetic resonance imaging. *Schizophr. Res.*, 27: 45 – 53.
  - 21. Burt AM (1993):** Textbook of Neuroanatomy. First edition, pp.17-19 and 172-174, Saunders Company, Philadelphia.
  - 22. Carpenter MB & Sutin J (1983):** Human Neuroanatomy. Eighth edition, pp. 41 - 45, Williams & Wilkins, Baltimore & London.
  - 23. Celik HH, Gurbuz F, Erilmaz M and Sancak B (1995):** CT measurement of the normal brain ventricular system in 100 adults. *Kaiboqaku. Zasshi.*, 70(2): 107 -115.
  - 24. Chmielowski K, Podgórski JK, Twarkowski P, Pietrzykowski J, and Szaluś N (2004):** Radionuclide cisternography in the diagnosis of normal pressure hydrocephalus. *Pol. Merkur. Lekarski.*, 16:576-580.
  - 25. Chudgar P (1999):** Role of imaging in hydrocephalus. *Neuroradiology*, 22:144 -149.
  - 26. Clarke E and Dewhirst K (1972):** An Illustrated History of Brain Function. P:149, University of California Press, Berkley, California.
  - 27. Correa FF, Lara C, Bellver J, Remohí J, Pellicer A and Serra V (2006):** Examination of the fetal brain by transabdominal three-dimensional ultrasound: potential for routine neurosonographic studies. *Ultrasound Obstet. Gynecol.*, 28(5):742 - 743.
-

## **References**

---

- 28. Csutak R, Unterassinger L, Rohrmeister C, Weninger M and Vergesslich KA (2003):** Three-dimensional volume measurement of the lateral ventricles in preterm and term infants: evaluation of a standardized computer-assisted method in vivo. *Pediatric Radiology*, 33(2):104 -109.
  - 29. Dale AM, Liu AK, Fischl B, Lewine JD, Buckner RL, Belliveau JW and Halgren E (2000):** Dynamic statistical parameter mapping: combining fMRI and MEG to produce high resolution imaging of cortical activity. *Neuron*, 26: 55 - 67.
  - 30. Dalton CM, Brex PA, Jenkins R, Fox NC, Miszkiet KA, W R Crum WR, O'Riordan JI, Plant GT, Thompson AJ, and Miller DH (2002):** Progressive ventricular enlargement in patients with clinically isolated syndromes is associated with the early development of multiple sclerosis. *Journal of Neurology Neurosurgery and Psychiatry*, 73:141 -147.
  - 31. Davis KL, Buchsbaum MS, Shihabuddin L, Spiegel-Cohen J, Metzger M, Frecska E, Keefe RS and Powchik P (1998):** Ventricular enlargement in poor-outcome schizophrenia. *Biol. Psychiatry*, 43:783 - 793.
  - 32. DeCarli C, Haxby JV, Gillette JA, Teichberg D, Rapoport SI and Schapiro MB (1992a):** Longitudinal changes in lateral ventricular volume in patients with dementia of the Alzheimer type. *Neurology*, 42:2029 – 2036.
-



## **References**

---

- 33. DeCarli C, Maisog J, Murphy DG, Teichberg D, Rapoport SI and Horwitz B (1992b):** Method for quantification of brain, ventricular, and subarachnoid CSF volumes from MR images. *J. Comput. Assist. Tomogr.*, 16:274 – 284.
  - 34. Degreef G, Ashtari M, Bogerts B, Bilder RM, Jody DN, Alvir JMJ and Lieberman JA (1992):** Volumes of ventricular system subdivisions measured from magnetic resonance images in first-episode schizophrenic patients. *Archives of General Psychiatry*, 49:531 - 537.
  - 35. Dopson JF (1927):** Erasistratus. *Proc. B. Soc. Med.*, 20: 835 – 832. (Cited in Tascioglu, 2005).
  - 36. Dudek RW & Fix JD (2005):** Embryology. Third edition, pp. 70 -71, Lippincott Williams & Wilkins, Philadelphia & Baltimore.
  - 37. Duffner F, Schiffbauer H, Glemser D, Skalej M and Freudenstein M (2003):** Anatomy of the cerebral ventricular system for endoscopic neurosurgery: a magnetic resonance study. *Acta Neurochirurgica*, 145(5):359 - 368.
  - 38. El Gammal T, Allen MB, Brooks BS and Mark ED (1987):** MR evaluation of hydrocephalus. *Am. J. Neuroradiol.*, 8:591 – 597.
  - 39. Enzmann DR and Pelc NJ (1991):** Normal flow patterns of intracranial and spinal cerebrospinal fluid defined by phase contrast cine MR imaging. *Radiology*, 178:467 - 474.
-

## **References**

---

- 40. Erdem G, Celik O, Hascalik S, Karakas HM, Alkan A and Firat AK (2007):** Diffusion-weighted imaging evaluation of subtle cerebral microstructural changes in intrauterine fetal hydrocephalus. *Magn. Reson. Imaging.*, 25(10):1417 -1422.
  - 41. Ernestus RI, Krüger K, Ernst S, Lackner K and Klug N (2002):** Relevance of magnetic resonance imaging for ventricular endoscopy. *Minim. Invasive Neurosurg.*, 45:72 – 77.
  - 42. Evans WA (1942):** An encephalographic ratio for estimating ventricular enlargement and cerebral atrophy. *Arch. Neurol. Psychiatry*, 47:931 - 937.
  - 43. Fannon D, Tennakoon L, O'ceallaigh S, Doku V, Soni W, Chitnis X, Lowe J, and Sumich A (2000):** Third ventricle enlargement and developmental delay in first-episode psychosis: preliminary findings. *The British Journal of Psychiatry*, 177: 354 - 359.
  - 44. Fiske CE, Filly RA & Callen PW (2005):** Sonographic measurement of lateral ventricular width in early ventricular dilation. *Journal of Clinical Ultrasound*, 9(6): 303 - 307.
  - 45. FitzGerald MJT & Folan-currin J (2002):** *Clinical Neuroanatomy and Related Neuroscience*, Fourth edition, pp. 221, Saunders Company, Edinburgh, New York.
  - 46. Galaburda AM, LeMay M, Kemper TL and Geschwind N (1978):** Right-left asymmetries in the brain. *Science.*, 24;199(4331):852 - 856.
-

## **References**

---

- 47. Garel C & Alberti C (2006):** Coronal measurement of the fetal lateral ventricle: comparison between ultrasonography and magnetic resonance imaging. *Ultrasound Obstet. Gynecol.*, 27(1): 23 - 27.
  - 48. Gaser C, Nenadic I, Buchsbaum BR, Hazlett EA, Monte S and Buchsbaum MS (2004):** Ventricular enlargement in schizophrenia related to volume reduction of the thalamus, striatum, and superior temporal cortex. *Am. J. Psychiatry*, 161:154 - 156.
  - 49. Gawish I, Reisch R and Perneczky A (2005):** Endoscopic aqueductoplasty through a tailored craniocervical approach. *J. Neurosurg.*, 103(5):778 - 782.
  - 50. Grasby DC Estermana A and Marshall P (2003):** Ultrasound grading of cerebral ventricular dilatation in preterm neonates. *Journal of Paediatrics and Child Health*, 39(3):186 -190.
  - 51. Griscom NT and O'Connor JF (1995):** The rise and fall of a radiologic technique. *Am. J. Roentgenol.*, 164(4):1011 -1012.
  - 52. Grosman H, Stein M, Perrin RC, Gray R and St Louis EL (1990):** Computed tomography and lateral ventricular asymmetry: clinical and brain structural correlates. *Can. Assoc. Radiol J.*, 41(6):342 - 346.
  - 53. Gross CG (1998):** *Brain, Vision, Memory: Tales in the History of Neuroscience.* pp. 94 & 253, MIT Press, Cambridge.
-

## **References**

---

- 54. Gyldensted C (1977):** Measurements of the normal ventricular system and hemispheric sulci of 100 adults with computed tomography. *Neuroradiology*, 14: 183 - 192.
  - 55. Hakyemez B, Erdogan C, Oruc E, Aker S, Aksoy K and Parlak M (2007):** Foramen of monro meningioma with atypical appearance: CT and conventional MR findings. *Australas Radiol.*, 51 Spec. No.: B3 - 5.
  - 56. Hamilton WJ, Boyed, and Mossman HW (1972):** Human Embryology. Fourth edition, pp. 437-461, Heffer W & Sons Ltd, Cambridge.
  - 57. Haug G (1977):** Age and sex dependence of the size of normal ventricles on computed tomography. *Neuroradiology*, 14(4):201-214.
  - 58. Hauser P, Matochik J, Altshuler LL, Denicoff KD, Conrad A, Li X and Post RM (2000):** MRI-based measurements of temporal lobe and ventricular structures in patients with bipolar I and bipolar II disorders. *J. Affect. Disord.*, 60:25 - 32.
  - 59. Hilpert PL, Hall BE & Kurtz AB (1995):** The atria of the fetal lateral ventricles: a sonographic study of normal atrial size and choroid plexus volume. *Am. J. Roentgenol.*, 164(3):731-734.
  - 60. Hirashima Y, Shindo K and Endo S (1983):** Measurement of the area of the anterior horn of the right lateral ventricle for the diagnosis of brain atrophy by CT. Correlation with several ventricular indices. *Neuroradiology*, 25(1): 23 - 27.
-

## ***References***

---

- 61. Hobar JD, Leahy KA & Lucey JF (1983):** Ultrasound identification of lateral ventricular asymmetry in the human neonate. *JCU* 11:67 - 69.
  - 62. Hughes CP and Gado M (1981):** Computed tomography and aging of the brain. *Radiology*, 139(2):391-396.
  - 63. Ichihashi K, Lino M, Eguchi Y, Uchida A, Honma Y and Momoi M (2002):** Difference between left and right lateral ventricular sizes in neonates. *Early Hum. Dev.*,68(1):55 - 64.
  - 64. Ichihashi K, Takahasi N, Honma Y and Momoi M (2005):** cerebral ventricular volume assessment by three-dimensional ultrasonography. *J. perinat. Med.*, 33(4): 332 - 335.
  - 65. Jain D, Sharma MC, Sarkar C, Suri V, Rishi A, Garg A and Vaishya S (2008):** Choroid glioma: report of two rare examples with unusual features. *Acta. Neurochir.*, 150(3):295 - 300.
  - 66. Jamous M, Sood S, Kumar R and Ham S (2003):** Frontal and occipital horn width ratio for the evaluation of small and asymmetrical ventricles. *Pediatr. Neurosurg.*, 39(1):17 - 21.
  - 67. Jeong Y, Song YM, Chung PW, Kim EJ, Kang SJ , Kim JM, Cho SS , Kim SE, Byun HS and NA DL (2005):** Correlation of the ventricular asymmetry and metabolic asymmetry in FrontoTemporal dementia. Masson, Paris, *Journal de Neuroradiologie.*, 32:247 – 254.
  - 68. Jernigan TL, Press GA and Hesselink JR (1990):** Methods for measuring brain morphologic features on magnetic resonance images: validation and normal aging. *Arch Neurol.*, 47:27 – 32.
-

## **References**

---

- 69. Johnstone EC, Crow TJ, Frith CD, Husband J and Kreef L. (1976):** Cerebral ventricular size and cognitive impairment in chronic schizophrenia. *Lancet*, 2(7992):924 - 926.
  - 70. Kazan-Tannus JF, Dialani V, Kataoka ML, Chiang G, Feldman HA, Brown JS and Levine D (2007):** MR Volumetry of Brain and CSF in Fetuses Referred for Ventriculomegaly. *AJR*, 189:145 - 151.
  - 71. Keele KD (1964):** Leonardo da Vinci's influence on Renaissance anatomy. *Med. Hist.*, 8: 360 – 370.
  - 72. Kodama N, shimada T and fukumoto I (2002):** Image-based diagnosis of Alzheimer- type dementia: Measurement of hippocampal and ventricular areas in MR Images. *Magnetic Resonance in Medical Science*, 1(1):14 - 20.
  - 73. Kramer RL, Yaron Y, Johnson MP, Evans MI, Treadwell MC and Wolfe HM (1997):** Differences in measurements of the atria of the lateral ventricle: does gender matter? *Fetal Diagn. Ther.*,12 (5):304 - 305.
  - 74. Kulkarni AV, Drake JM, Armstrong DC and Dirks PB (1999):** Measurement of ventricular size: reliability of the frontal and occipital horn ratio compared to subjective assessment. *Pediatr. Neurosurg.*, 31(2):65 - 70.
  - 75. Larsen WJ (2001):** *Human Embryology*. Third edition, pp. 446-447, Churchill Livingstone, New York.
-

## **References**

---

- 76. Lee PH, Yong SW, Ahn YH and Huh K (2005):** Correlation of midbrain diameter and gait disturbance in patients with idiopathic normal pressure hydrocephalus. *J. Neurol.*, 252(8): 1432 - 1459.
  - 77. LeMay M (1976):** Morphological cerebral asymmetries of modern man, fossil man, and nonhuman primate. *Ann N Y Acad. Sci.*, 280:349 - 366.
  - 78. Levine D, Barnes PD, Madsen JR, Li W and Edelman RR (1997):** Fetal central nervous system anomalies: MR imaging augments sonographic diagnosis. *Radiology*, 204:635 – 665.
  - 79. Levine D, Trop I, Mehta TS and Barnes PD (2002):** MR Imaging of Fetal Cerebral Ventricular Morphology. *Radiology*, 213:291 - 299.
  - 80. Lewis MM, Smith AB, Styner M, Gu H, Poole R, Zhu H, Li Y, Barbero X, Gouttard S, McKeown MJ, Mailman RB, and Huang X (2009):** Asymmetrical lateral ventricular enlargement in Parkinson's disease. *Eur. J. neurol.*, 20(1) 15 - 22.
  - 81. Liao MF, Chaou WT, Tsao LY, Nishida H and Sakanoue M (1997):** Ultrasound measurement of the ventricular size in newborn infants. *J. Neurorad.*, 88:133 - 142.
  - 82. Lombroso CT, Erba G and Yogo T (1968):** Two-dimensional ultrasonography: a method to study normal and abnormal ventricles. *Pediatrics*, 42:157 - 174.
  - 83. Longrigg J (1988):** Anatomy in Alexandria in the third century BC. *Br. J. Hist. Sci.*, 21: 455 – 488.
-

## **References**

---

- 84. Mata I, Perez-Iglesias R, Roiz-Santiañez R, Tordesillas-Gutierrez D, Gonzalez-Mandly A, Vazquez-Barquero JL, and Crespo-Facorro B (2009):** A neuregulin 1 variant is associated with increased lateral ventricle volume in patients with first-episode schizophrenia. *Biol. Psychiatry*, 65(6):535 - 540.
  - 85. McGahan JP and Phillips HE (1983):** Ultrasonic evaluation of the size of the trigone of the fetal ventricle. *J. Ultrasound Med.*, 2:315 - 319.
  - 86. McKinley MJ McAllen RM, Davern P, Giles ME, Penschow J, Sunn N, Uschakov A and Oldfield BJ (2003):** The sensory circumventricular organs of the mammalian brain. *Adv. Anat. Embryol. Cell Biol.*, 172: III- XII, 1 - 122.
  - 87. Meese W, Kluge W, Grumme T and Hopfenmüller W (1980):** CT evaluation of the CSF spaces of healthy persons. *Neuroradiology*, 19:131 - 136.
  - 88. Melhem ER, Hoon AH Jr, Ferrucci JT Jr, Quinn CB, Reinhardt EM, Demetrides SW, Freeman BM and Johnston MV (2000):** Periventricular leukomalacia: relationship between lateral ventricular volume on brain MR and severity of cognitive and motor impairment. *Radiology*, 214:199 - 204.
  - 89. Mercier F, Kitasako JT and Hatton GL (2002):** Anatomy of the brain neurogenic zones revisited: fractones and the fibroblast-macrophage network. *J. comp. Neurol.*, 445(2): 170 - 188.
  - 90. Meyer A (1971):** *Historical Aspect of Cerebral Anatomy*, Oxford University Press, London.
-



## **References**

---

- 91. Mu Q, Xie J, Wen Z, Weng Y and Shuyun Z (1999):** A Quantitative MR Study of the Hippocampal Formation, the Amygdala, and the Temporal Horn of the Lateral Ventricle in Healthy Subjects 40 to 90 Years of Age. *American Journal of Neuroradiology*, 20:207 - 211.
  - 92. Nadel AS and Benacerraf BR (1995):** Lateral ventricular atrium: larger in male than female fetuses. *Int. J. Gynaecol. Obstet.*, 51(2):123 - 126.
  - 93. Nakamura K , Kawasaki Y, Suzuki M, Hagino H, Kurokawa K, Takahashi T, Niu L, Matsui M, Seto H and Karachi M (2004):** Multiple Structural Brain Measures Obtained by Three-Dimensional Magnetic Resonance Imaging To Distinguish Between Schizophrenia Patients and Normal Subjects. *Schizophrenia Bulletin.*, 30 (2):393 - 404.
  - 94. Nemesius (1955):** On the Nature of Man. In: Tefler W, ed. *Cyric of Jerusalem and Nemesius of Emesa*. Philadelphia, Westminster Press. 1955; 84. (Cited in Tascioglu, 2005).
  - 95. Nolte J (1993):** *The Human Brain*. p 466, St. Louis, Mosby, NY.
  - 96. Nopoulos P, Flaum M and Andreasen NC (1997):** Sex Differences in Brain Morphology in Schizophrenia. *Am. J. Psychiatry*, 154:1648 - 1654.
  - 97. O'Hayon BB, Drake JM, Ossip MG, Tuli S and Clarke M (1998):** Frontal and occipital horn ratio: A linear estimate of ventricular size for multiple imaging modalities in pediatric hydrocephalus. *Pediatr. Neurosurg.*, 29(5):245 - 249.
-

## **References**

---

- 98. Pedersen H, Gyldensted M and Gyldensted C (1979):** Measurement of the normal ventricular system and supratentorial subarachnoid space in children with computed tomography. *Neuroradiology.*, 17(5):231 - 237.
  - 99. Poynter FN (1964):** Andreas Vesalius of Brussels 1514-1564. A brief survey of recent work. *J. Hist. Med. Allied Sci.*, 19:321-326.
  - 100. Raz S, Raz N, Weinberger DR, Boronow J, Pickar D, Bigler FD and Turkheimer E (1987):** Morphological brain abnormalities in schizophrenia determined by computed tomography: a problem of measurement?. *Psychiatry Res.*, 22(2):91 - 98.
  - 101. Reisner T, Zeiler K and Strobl G (1980):** Quantitative evaluation of lateral ventricle width by means of CT-values obtained from a normal population. *Fortschr. Neurol. Psychiatr. Grenzgeb.*, 48(3):168 - 174.
  - 102. Riccabona M, Nelson TR, Pretorius DH and Davidson TE (1995):** Distance and volume measurement using three-dimensional ultrasonography. *J Ultrasound Med.*, (12):881 - 886.
  - 103. Rocca J (1997):** Galen and the ventricular system. *J. Hist. Neurosci.*, 6(3):227 - 239.
  - 104. Sadleir RJ and Tang T (2009):** Electrode configurations for detection of intraventricular haemorrhage in the premature neonate. *Physiol. Meas.* 30(1):63 - 79.
  - 105. Sadler TW (1998):** Longman's Medical Embryology. Seventh edition, pp. 374 - 8, Williams & Wilkins, Baltimore & London.
-

## **References**

---

- 106. Saliba E, Bertrand P, Gold F, Vaillant MC and Laugier J (1990):** Area of lateral ventricles measured on cranial ultrasonography in preterm infants: reference range. Arch Dis. Child., 65(10 Spec No):1029 - 1032.
  - 107. Schmidt R, Launer LJ, Nilsson L, Pajak A, Sans S, Berger K, Breteler MM, Ridder M, Dufouil C, Fuhrer R, Giampaoli S and Hofman A (2004):** Magnetic Resonance Imaging of the Brain in Diabetes. Diabetes, 53:687 - 692.
  - 108. Segev Y, Metser U, Beni-Adani L, Elran C, Reider-Groswasser II and Constantini S (2001):** Morphometric study of the midsagittal MR imaging plane in cases of hydrocephalus and atrophy and in normal brains. Am. J. Neuroradiol., 22(9):1674 - 1679.
  - 109. Sener RN (1992):** A theoretical explanation of asymmetry of the frontal horns of the lateral ventricles. AJR, 158(5):1175-1176.
  - 110. Shackelford GD (1986):** Neurosonography of hydrocephalus in infants. Neuroradiology, 28:452 - 462.
  - 111. Shapiro R, Galloway SJ and Shapiro MD (1986):** Minimal asymmetry of the brain: a normal variant. AJR, 147:753 - 756.
  - 112. Shenton ME, Kikinis R, McCarley RW, Metcalf D, Tieman J and Jolesz FA (1991):** Application of automated MRI volumetric measurement techniques to the ventricular system in schizophrenics and normal controls. Schizophr. Res.,5(2):103-113.
  - 113. Singer CJ (1957):** A Short History of Anatomy from the Greeks to Harvey; the evolution of anatomy, Dover. pp. 23 – 94, New York.
-

## **References**

---

- 114. Sonigo PC, Rypens FF and Carteret M (1998) :** MR imaging of fetal cerebral anomalies. *Pediatr. Radiol.*, 28:212 – 222.
  - 115. Srijit D and Shipra P (2007):** Anatomical study of anomalous posterior horn of lateral ventricle of brain and its clinical significance. *Bratisl. Lek. Listy.*, 108(9):422 - 424.
  - 116. Staden VH (1989):** Herophilus: The Art of Medicine in Early Alexandria. 146, Cambridge University Press, New York.
  - 117. Standing S, Crossman AR & FitzGerald MJT (2005):** Gray's Anatomy. Thirty-ninth edition, pp. 287 - 294, Elsevier Churchill Livingstone, Edinburgh & London.
  - 118. Strakowski SM, DeBello MP, Adler C, Cecil KM and Sax KW (2000):** Neuroimaging in bipolar disorder. *Bipolar. Disord* 2:148 - 164.
  - 119. Styner M, Lieberman JA, McClure RK and Daniel R (2005):** Morphometric analysis of lateral ventricle in schizophrenia and healthy control regarding genetic and disease-specific factors. *J. Neurorad.*, 7: 221 - 231.
  - 120. Sullivan EV, Pfefferbaum A, Adalsteinsson E, Swan GE and Carmelli D (2002):** Differential Rates of Regional Brain Change in Callosal and Ventricular Size: a 4-Year Longitudinal MRI Study of Elderly Men. *Cereb. Cortex*, 12(4):438 - 445.
  - 121. Tascioglu AO and Tascioglu AB (2005):** Ventricular anatomy: illustrations and concepts from antiquity to Renaissance. *Neuroanatomy*, 4: 57 – 63.
-

## **References**

---

- 122. Verrees M and Selman WR (2004):** Management of Normal Pressure Hydrocephalus. *J. Am. Fam. Phys.*, 70:66 - 72.
  - 123. Voigt K and Bockenheimer S (1978):** Neuroradiologic and clinical correlations in asymmetric lateral ventricles and posterior cornua in pneumo-encephalograms. *Fortschr. Neurol. Psychiatr. Grenzgeb.*, 46(8):440 - 451.
  - 124. Von Staden H (1989):** Herophilus: The Art of Medicine in Early Alexandria. 146, Cambridge University Press. New York.
  - 125. Winchester P, Brill PW, Cooper R, Krauss AN and Peterson HD (1986):** Prevalence of “Compressed” and Asymmetric Lateral Ventricles in Healthy Full-Term Neonates: Sonographic Study. *AJR.*, 146:471 - 475.
  - 126. Wright IC, Rabe-Hesketh S, Woodruff PWR, David AS, Murray RM and Bullmore ET (2000):** Meta-analysis of regional brain volumes in schizophrenia. *Am. J. Psychiatry.*, 157:16 – 25.
  - 127. Wurthmann C, Bogerts B and Falkai P (1995):** Brain morphology assessed by computed tomography in patients with, degenerative dementia, and normal control subjects. *Psychiatry Res.*, 61(2):103 - 111.
  - 128. Zatz LM (1979):** The Evans ratio for ventricular size: a calculation error. *Neuroradiology*, 18 (2):81 - 99.
-

## الملخص العربي

إن قياسات البطينات الدماغية أصبحت مهمة وذلك لنتبع تطور العديد من الأمراض العصبية مثل مرض استسقاء المخ وكذلك يساعد في إضافة بعض الأساليب العلاجية مثل تركيب الصمامات البطينية.

صممت هذه الدراسة والمعتمدة علي التصوير باستخدام الرنين المغناطيسي لتعريف القيم الطبيعية للأجزاء المختلفة للبطين الوحشي البشري لتكوين قاعدة بيانات قياسية للبطين الدماغ في السكان الليبيين. كما هدفت هذه الرسالة إلي مقارنة قياسات البطينات الوحشية اليمنى واليسرى في كلا الذكور والإناث ولدراسة الاختلافات بين الذكور والإناث ولدراسة التغيرات الزمنية للبطين الوحشي من عُمر 20 إلى عمر 60 عاماً. يُمكن استخدام هذه القاعدة البيانية كدليل معلوماتي وكمراجع لتشخيص الأمراض العصبية المختلفة.

استعملت في هذه الدراسة مجموعه من 160 ذكر وأنثي من مدينة بنغازي-ليبيا، وخاليين من الأمراض العصبية (80 ذكر و80 أنثي) تراوحت أعمارهم بين 20 – 60 عاماً وتم إرسالهم إلى وحدة التصوير بالرنين المغناطيسي لأسباب مختلفة عدا الاضطرابات العصبية وقد مرّوا بمقابلة طبية تم من خلالها استبعاد الحالات العصبية أو النفسية أو القلبية. كذلك تم استبعاد الأشخاص الذين يعانون من الأمراض القلبية أو

السكري أو الذين تعرضوا لأي صدمه علي الرأس ، وقد أخضع الأشخاص المستهدفون إلى تصوير البطن الجانبي بالرّنين المغناطيسي في المستويات المحورية المختلفة ، بعد أخذ موافقتهم، في مركز بنغازي للاشعة التشخيصية والعلاجية.

شملت القياسات الشكلية للبطن الوحشي نطاق القرن الأمامي والثالوث (الأذين)، والقرن الصدغي لجانب الأيسر والأيمن و حددت يدوياً على الأقسام المحورية التصويرية المناسبة. حُسبت المساحات المقطعية و عبر عنها بوحدات المليمتر المربعة. عرف دليل إيفانز بأنه النسبة بين المسافة بين قمم القرون الأمامية والقطر الأمامي للجمجمة في نفس المستوى محسوباً في المستوي المحوري نفسه لكل الأشخاص. عرف الدليل النصف كروي البطني (V/H index) بأنه النسبة بين المسافات من خط المنتصف إلى النقطة الأكثر جانبية من البطن الوحشي إلى العرض المطابق للنصف كروي الدماغ في نفس الجهة مقاساً في المحور التاجي في مستوى فتحة مونرو. تم انجاز التحليل الإحصائي لبيانات الذكور والإناث لكلا المجموعتين العمريتين باستعمال برنامج SPSS /PC.

كشفت النتائج بأن المساحة المقطعية للبطن الوحشي الأيسر كانت أكبر من مثيلتها بالبطن الوحشي الأيمن باستثناء المنطقة المقطعية للثالوث في الأنثى التي لم تبين أي اختلاف مميز بين الجانبين. تم مقارنة قيم دليل إيفانز في الذكور والإناث وكل الأشخاص مع القيمة الدولية للدليل والتي متوسطها 0.28 للدماغ البالغ الطبيعي. في هذا البحث كان متوسط دليل إيفانز للذكور وللإناث مطابقاً للقيمة الدولية للدليل. وبمقارنة قياسات

البطين الوحشي الذكري مع البطين الوحشي النسائي لوحظ أن قيمَ الذكور كانت اعلي من مثيلاتها في الإناث. كما كان دليل  $V/H$  ودليل إيفانز للبطين الوحشي في الذكر اكبر من مثيلاتهم في الأنثى.

إنّ القيمة المرتفعة وذات دلالة مميزة لدليل  $V/H$  الأيسر كانت معادله للقيمة المرتفعة للمساحة المقطعية للقرن الأمامي الأيسر وهذا قد يعكس زيادةً في حجم النصف الدماغى الأيسر عن الأيمن. أخذاً في الاعتبار أن نصف كرة الدماغ الأيسر هو المهيمن في أكثر الأفراد، فإن هذه النتيجة قد تُشيرُ إلى أن النصف الدماغى المهيمن اكبر حجماً من النصف الأخر. هذا الاقتراح يحتاجُ إلي دراسة قياسات شكلية أخرى علي نصف الكرة الدماغى. وأوضح تحليل القياسات الشكلية للبطين الوحشي في كلا الذكور والإناث زيادةً نو دلالة في كلّ قياسات البطين الوحشي مع التقدم بالعمر.

ولقد استخلص من هذه الدراسة أن النتائج تشير إلي وجود اختلاف ولا تناظر بين البطين الوحشي الأيسر والأيمن وأيضاً بين الذكر و الأنثى. وحسب معرفتنا فان هذه الدراسة التحليلية هي الأولى من نوعها في ليبيا التي بحثتُ القياسات المختلفة للبطين الوحشي وبينتُ القيمَ القياسية الأساسية لأبعادِ البطين الوحشي في مجموعه من السكان الليبيين ويُمكنُ أن تُستعملَ كدليل لتشخيص العديد من الأمراض العصبية التي قد تُخلُ بهذه الأبعاد. كما أن هذه الدراسة قدمتُ وسيلةً لحساب القياسات ثنائية الأبعاد للبطينات الوحشية الدماغية ويُمكنُ أن تستعملَ بشكل دوري في المجال الإشعاعي العصبى



---

للمُساعدَة في تشخيص الظروف المرضية المختلفة الذي قد تَسبَّبُ توسعَ في البطن  
الدماعي.

---